

## Review Article

## Stigma and Epulis: About A Case

Diakite Y.<sup>1</sup>, Traore C.I.<sup>1</sup>, Djire H.<sup>1</sup>, Diassana M.<sup>2</sup>, Traore B.A.<sup>2</sup>, Toure L.<sup>2</sup>, Diaby L M.<sup>3</sup>, Diallo L.<sup>3</sup>, Maiga A. S.<sup>3</sup>, Kane A.S.T.<sup>3</sup>, Diatta M.<sup>4</sup>, Tamba B.<sup>4</sup>.

<sup>1</sup>Service of Odontostomatology of Sikasso's Hospital

<sup>2</sup>Service of General Surgery of Sikasso's Hospital

<sup>3</sup>Medical Services of Malian Armed Forces

<sup>4</sup>General Hospital of Grand Yoff

\*Corresponding Author

Youssouf Diakite, Email: [Youdiak5@yahoo.fr](mailto:Youdiak5@yahoo.fr)

**Abstract:** Epulis is a circumscribed gingival outgrowth of varying aspects. It is the most common benign tumor in the oral cavity. Its etiology is unknown. The objective of this observation was to present a case of tumor with psycho-social impact. **Observation:** We report the case of a 17-year-old male patient, living in rural area, referred by the healthcare center of his area to the service of dentistry for management. His consultation was motivated by the increasing volume of his tumor, stigmatization and mockery. The largest tumor was painless, firm, mobile, rounded, localized buccally and next to teeth 11, 12, and 13 inserted between 11 and 12 by means of a cord, and a smaller one next to tooth 21 was detected. The diagnosis of the epulis was mentioned for both. Their surgical resection was practiced. Follow-up was simple. The Anatomico-pathological examination confirmed the diagnosis of fibrous tumor. **Discussion:** Epulis is an extremely characteristic lesion with a generally sulcus starting point, which protrudes on the gum. It presents itself as a single mass or poly-lobed, pedicled or sessile, of varying size. It mostly appears dark red, hemorrhagic. It can be observed at any age. **Conclusion:** The treatment of tumor consists of its surgical resection and the elimination of the causative factor. This allows an improvement in the quality of life of the patient by the amendment of functional and aesthetic genes.

**Keywords:** epulis, stigma, care, reinsertion, rural area.

### INTRODUCTION

The epulis is a circumscribed gingival outgrowth which could have variable aspects clinically, histologically and topographically. It is the most common tumor of the oral cavity (Mounir, Z. *et al.*, 2015); it has been widely described in Europe, Africa and Asia (Rakotoarivony, A. *et al.*, 2013). Its etiology is unknown; however, several factors may be incriminated as an inflammatory process (Mounir, Z. *et al.*, 2015; Kané, A.S.T. *et al.*, 2018, may; Elmahi, H., & Mernissi, F.Z. 2016), chronic local irritation due to dental plaque, poorly fitting prosthesis or dental debris (Bengondo, M.C. *et al.*, 2006). Clinically, it appears as a fibrous mass, painless with a consistency of soft, elastic or firm; it could also appear with a smooth or lobulated appearance, hyperemia, with a hemorrhagic tendency. It may be circumscribed, sessile with a broad or pedicle-based implantation (Bengondo, M.C. *et al.*, 2006). It is a slow-growing tumor with no evidence of malignancy (clear limits, absence of lymphadenopathy,

painless, induration) (Elmahi, H., & Mernissi, F.Z. 2016; Elmahi, H., & Mernissi, F.Z. 2016).

The diagnosis of the epulis is based on a thorough interrogation, a rigorous clinical examination and a systematic radiological examination (retro alveolar or panoramic). Despite the clinical and radiological particularities which sometimes guide the diagnosis, it is the anatomico-pathological study which makes possible the definitive diagnosis and the exact aspect of the epulis (Mounir, Z. *et al.*, 2015). There are different histological types of epulis: simple, inflammatory, vascular or angiomatous, fibrous, giant cell or myeloid epulis (Elmahi, H., & Mernissi, F.Z. 2016; Traore, H. *et al.*, 2013). Conservative surgical excision and removal of local irritants (plaque, tartar, foreign materials, source of trauma) are the treatments of choice for epulis (Mounir, Z. *et al.*, 2015; Kané, A.S.T. *et al.*, 2018, May; Elmahi, H., & Mernissi, F.Z. 2016). Recently, other treatment protocols replacing

Quick Response Code



Journal homepage:

<http://www.easpublisher.com/easms/>

Article History

Received: 11.03.2019

Accepted: 25.03.2019

Published: 16.04.2019

**Copyright © 2019 The Author(s):** This is an open-access article distributed under the terms of the Creative Commons Attribution 4.0 International License (CC BY-NC 4.0) which permits unrestricted use, distribution, and reproduction in any medium for non-commercial use provided the original author and source are credited.

DOI: 10.36349/easjms.2019.v01i02.013

surgical excision have been proposed (Mounir, Z. *et al.*, 2015; Rakotoarivony, A. *et al.*, 2013).

The objective of this observation was to present a case of epulis, seen and treated in the odontostomatology department of the Sikasso regional hospital.

### OBSERVATION

He was a seventeen years old young man on the day of the consultation, a Malian citizen living in a rural area. He consulted for a fleshy mass appended to the anteroposterior gingiva at the buccal area. He has seen this mass for about two years. It gradually increased in volume over time. It was painless, often bleeding through contact. Its size became so large that it prevented the closing of her labia for about a year; the size also made it a factor of stigma and mockery from his comrades of his village.

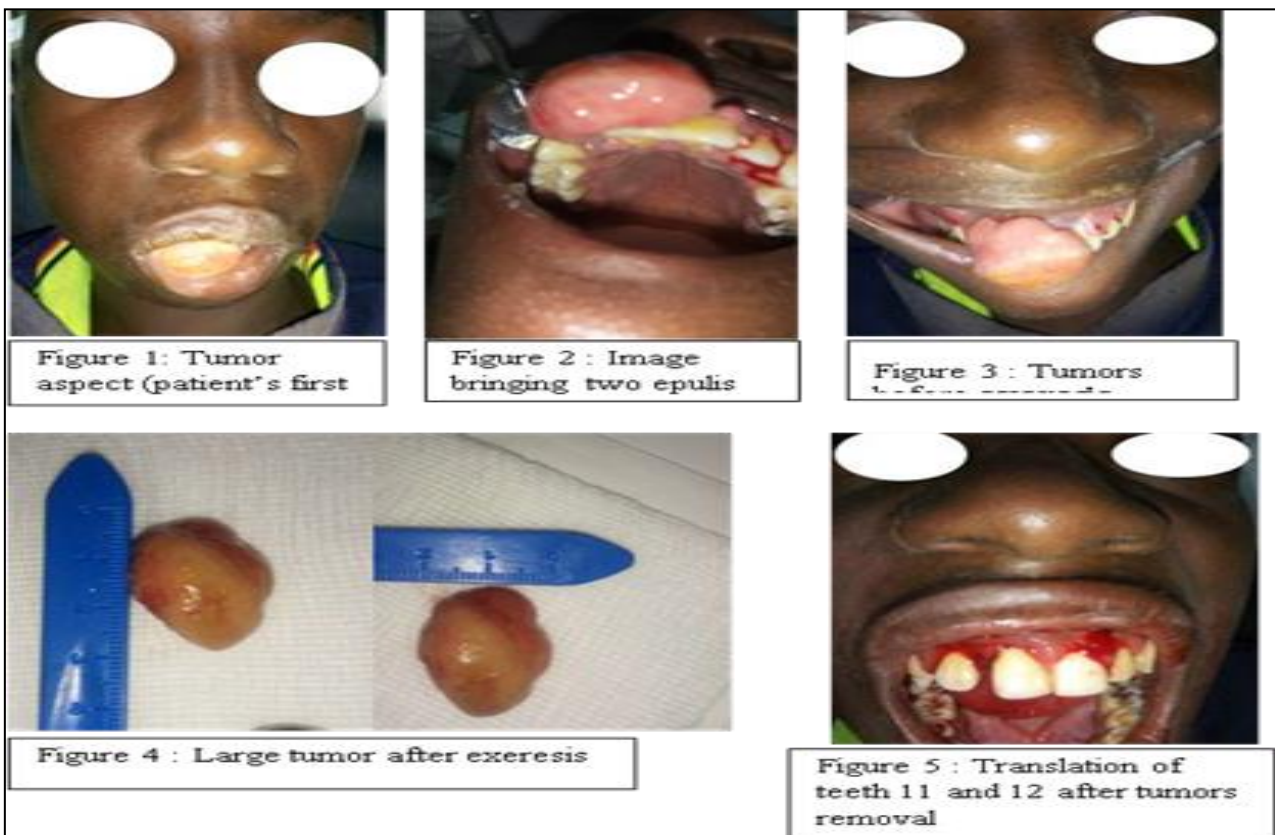
In face of these challenges, he consulted at the health center of his area, which then referred him to the odontostomatology department for a voluminous mass.

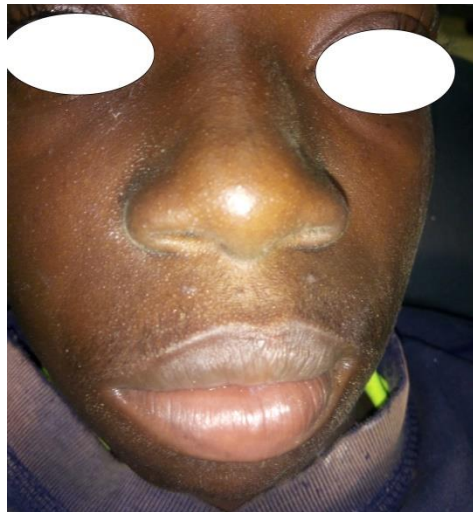
He was anxious. During exo-oral examination, there was a facial asymmetry at the expense of the right side, a labial inoclusion revealed the tumor and labial dryness (Fig. 1). On palpation, we didn't report any muscle pain, sensitivity of teguments, or cervico-facial lymphadenopathy. In the endo-oral examination, the

mouth opening was sufficient; the oral hygiene was poor with many tartaric deposits (Fig. 2).

The large epulis had a fleshy rounded, festooned, firm and mobile mass in the buccal aspect of teeth (21, 11, 12, 13) inserted between teeth 11 and 12 by means of a cord (Fig. 3), and another smaller one was localized at the level of marginal gingiva next to tooth 21 (Fig. 2). The diagnosis of epulis was mentioned for both masses and a biological examination (complete blood count, blood sugar level, hemostasis measure) was requested and appeared normal. Surgical excision of the two masses was performed with a cold blade and deep curettage of the bases (Fig. 4). He received a dressing based on eugenate and cotton fibers after compression with a cotton ball soaked in hydrogen peroxide. A post-operative prescription was composed of: amoxicillin (2 g / day for 7 days), paracetamol (2 g / day for 5 days) and chlorhexidine in mouthwash, plus motivation for oral hygiene and conditioning of the oral cavity a week later. Post-operational effects were simple.

Anatomo-pathological examination confirmed the diagnosis of fibrous epulis, with no sign of malignancy. The six-month postoperative check-up revealed no signs of recurrence, and the patient returned to normal life with his classmates and he was no longer teased or stigmatized.





**Fig-6: Complete mouth closure after surgery**

## DISCUSSION

The epulis is an extremely characteristic lesion with a generally sulcular starting point; it is prominent in the gingiva. It is presented as a single mass or polylobed, pedicled or sessile on the gum. Its size is variable and often measuring from 0.5 to 1.5 cm in diameter (Rakotoarivony, A. *et al.*, 2013).

It is most often appeared dark red, vascular or haemorrhagic and may present with superficial ulceration (Rakotoarivony, A. *et al.*, 2013). It can be observed at any age (Rakotoarivony, A. *et al.*, 2013). Our patient was a 17 year old young man. He had two tumors that appeared pink-blood color through contact and had variable size. The largest tumor measured 2.5cm / 1.5cm and the smallest measured as the size of a pea. Both of them were pedicled.

Up to now, no precise etiology of epulis was determined, but the aetiopathogenic approach made by many authors makes possible to distinguish local and general factors (inflammation, trauma, hormonal ...) that contribute to its occurrence (Rakotoarivony, A. *et al.*, 2013; Kané, A.S.T. *et al.*, 2018, May) . A post-avulsion epulis is a sequelae of extraction. It can be confused with lesions of similar appearance such as a pyogenic granuloma, hernia of the maxillary sinus. In case of traumatic epulis, dental restorations and poorly finished prosthetic edges are involved in its occurrence (Rakotoarivony, A. *et al.*, 2013; Kané, A.S.T. *et al.*, 2018, May). These factors were dismissed because our patient was neither wearing prosthesis nor having dental restorations. On the other hand, during the endo-oral examination, our patient presented moderate generalized gingivitis of tartaric origin. We can therefore say that tumors were favored by poor oral hygiene.

In the absence of effective treatment, the epulis can progress to certain complication. On the one hand, the consequences of this evolution are functional and aesthetic gene (Rakotoarivony, A. *et al.*, 2013; Adouko-

Aka, J.A. *et al.*, 2015), sometimes leading patients to hide their faces (Adouko-Aka, J.A. *et al.*, 2015). This was the case of our patient who consulted following the externalization of the tumor and the mockery of his comrades. In its contemporary sense, stigmatization describes keeping someone out of the way of the others because of differences that are considered to be contrary to social norms (Bichsel, D.N. 2017). In the field of mental health, the World Health Organization (WHO) classifies it as "the most important obstacle to overcome in the community" (WHO, 2001, 98) (Stuart, H. 2003). By considering these two factors, we can say that our patient suffered from stigmatization of his community. Ervin and Goffman identified three groups: the first is physical stigma refers to physical deformities of the body or visible external deformities (scars, physical disabilities, obesity); the second is stigma of character traits which refers to differences in people behaviors (mental disorders, substance abuse, alcoholism, criminal history); the third is stigma of group identity which refers to stigma that comes from being of a particular race, nation, religion, politics etc (Bichsel, D.N. 2017). Our patient is in the first group due to physical deformities of the body or visible external deformities that the tumor inflicted on him. On the other hand, local complications are: teeth displacements, dental mobility, alveolysis and teeth loss (Adouko-Aka, J.A. 2015). In the case of our patient, we noted translation of teeth 11 and 21; general complications such as malnutrition and anemia were not found. The treatment of choice for epulis is surgical excision, plus the elimination of irritating factors (Mounir, Z. *et al.*, 2015; Kané, A.S.T. *et al.*, 2018, May; Elmahi, H., & Mernissi, F.Z. 2016). Our patient was motivated to improve oral hygiene and help conditioning oral cavity after cold-blade surgical excision of the epulis. The definitive diagnosis is given by the anatomo-pathological examination of the operative specimen (Mounir, Z. *et al.*, 2015; Elmahi, H., & Mernissi, F.Z. 2016); in our case, this examination confirmed a fibrous epulis, without sign of malignancy.

## CONCLUSION

- Epulis is a pseudotumor of the gum. It is the most common tumors of the oral cavity.
- Its diagnosis is clinical, but confirmed by anatomo-pathological examination.
- Its prognosis can affect aesthetics, function, and mental state. The treatment is surgical with elimination of the etiological factor.
- Perspectives of introducing new non-surgical therapies are being tested.

## REFERENCES

1. Mounir, Z., Fayçal, B., & Aicha, B. (2015). À propos d'une nouvelle thérapeutique non conventionnelle des épulis. *facmed*, 3 (1), 31-36.
2. Rakotoarivony, A., Rasolonjatovo, T., Rakotoarimanana, F., Rakotoarison, R., & Alson,

- S.R. (2013). Epulis récidivante. *Revue d'odontostomatologie malgache*, 6, 9-15.
3. Kané, A.S.T., Diawara, O., Coulibaly, A., Diarra, D., Togo, A.K., Diaby, L.M., Maiga, A.S., Sanogo, A., & Traore, H. (2018, may). Management of a Case of Gingival Epulis and Review of Literature, *Sch. J. Med. Case Rep*, 6(5), 294-298.
  4. Adouko-Aka, J.A., Assouan, C., N'guessan, D., Abouna, A.D., Yapo Angoh, J.J., & Konan, E. (2015). Épulis géante ulcérée: un cas. *Med Buccale Chir Buccale*, 21, 225-227.
  5. Elmahi, H., & Mernissi, F.Z. (2016). Multiples épulis. *Pan Afr Med J*, 20, 25: 15.
  6. Bengondo, M.C., Onana, J., Sando, Z., Ebolo, X., & Bengono, G. (2006). Epulis géante pédiculée: à propos d'un cas. *Médecine Buccale Chir Buccale*, 12 (3),159-62.
  7. Akazane, A., & Hassam, B. (2014). Epulis: à propos d'un cas. *The Pan African Medical Journal*, (17), 19.
  8. Traore, H., Kamissoko, K., Traore, D., Coulibaly, A.D., Thera, T.D., Toure, K., Garango, A., Coulibaly, B., Ba, A., Malle, B., Traore, C.B., & Togora, S. (2013). Epulis fibreuse remaniee: Prise en charge chirurgicale d'un cas. *Mali Medical*, 3, 45-48.
  9. Bichsel, D.N. (2017). La stigmatisation: un problème fréquent aux conséquences multiples. *Rev MÉDICALE SUISSE*, 4.
  10. Stuart, H. (2003). Stigmatisation. Leçons tirées des programmes visant sa diminution. *Santé Ment Au Qué*, 28 (1), 54.