

Case Report

Sutton's Disease and Vitamin Deficiency: Diagnostic and Therapeutic Difficulties. About a Clinical Case at the University Teaching Hospital Center of Yaounde

Ntep Ntep David Bienvenue*¹, Bengondo Messanga Charles¹, Kenna Ernest¹, Mendouga Menye Coralie², Kwedi karl¹, Sitchepi Kamsu Huguette Sonia¹ and Endalle Catherine¹

¹Department of Odontostomatology and Maxillofacial Surgery, Yaounde University, Teaching and Hospital Center, Cameroon

²Pasteur Center of Yaoundé, Cameroon

Article History

Received: 04.12.2019

Accepted: 11.12.2019

Published: 03.01.2020

Journal homepage:

<http://www.easpublisher.com/easms/>

Quick Response Code



Abstract: Sutton's disease is a major recurrent aphthous stomatitis. It is an inflammatory pathology, characterized by the recurrent eruption of ulcerations. Although the etiopathogenesis of sutton's disease is still imperfectly known, it is nevertheless probable that the main phenomenon results from the cytotoxic action of CD4 + and CD8 + T lymphocytes and monocyte-macrophages with respect to the oral epithelium. We report the case of a 22- year-old patient who came to see for recurrent ulcerations of the oral cavity. The endobuccal examination showed giant ulcers of the lower lip, tongue and uvula. The suggested diagnostic for this clinical picture were: aphthosis oral recurrent, cyclic neutropenia and vitamin B12 deficiency. The combination of low cyanocobalamin, megaloblastic anemia, and histopathological characteristics, confirmed the diagnosis of Sutton disease secondary to vitamin B12 deficiency. Several treatments have been tried, but can not prevent recurrence. However, taking colchicine combined with vitamin B12 replacement therapy reduced the frequency and severity of the lesions.

Keywords: inflammatory pathology, cytotoxic action, CD4 + and CD8 + T lymphocytes and monocyte-macrophages.

Copyright © 2020 The Author(s): This is an open-access article distributed under the terms of the Creative Commons Attribution **4.0 International License (CC BY-NC 4.0)** which permits unrestricted use, distribution, and reproduction in any medium for non-commercial use provided the original author and source are credited.

INTRODUCTION

Sutton's disease is a recurrent aphthous stomatitis characterized by giant necrotizing ulcers that persist, disappear, leaving a fibrous retractile scar. This lesion was described in 1911 by Richard L. Sutton, an American dermatologist, who observed an inflammatory lesion developing around accessory salivary glands (Sutton, R. L. 1941).

Immunological disturbances and hypersensitivity to certain strains of normal oral bacteria have been implicated in the pathogenesis (Bilancia, A., & Altobella, L. 1970), but the exact etiology of this condition is not fully understood. A wide range of drugs are available but with limited effectiveness. We report the case of Sutton's peradenitis and discuss the diagnostic and therapeutic difficulties.

CASE PRESENTATION

In May 2015 Mrs X, aged 19, consults in the department of odontostomatology and maxillofacial surgery for ulcers of the oral cavity and an odynophagia.

The patient had consulted in several hospitals for mouth ulcers, appearing every months since the age of 9 years. Each ulcerative episode would end with spontaneous healing and subsequent recurrence.

The patient, worried, reports intense pain such as burns, odynophagia and tingling. The different treatments (systemic antibiotics, mouthwashes) did not bring any improvement, which motivated its consultation.

The general condition was well preserved. The patient was diagnosed with longstanding epigastric pain, treated with a proton pump inhibitor.

There was no notion of allergies, tuberculosis counting, HIV infection, herpes, and inflammatory bowel disease. However, the patient reports identical episodes in some members of her family (3/5).

On physical examination the patient was afebrile. Examination of ganglionic areas revealed sub-mandibular polyadenopathy. At the endobuccal examination, there were two painful supracentimetric ulcerations, sitting on the lower-right half-lip. The

lesions were oval, jagged edges with a granular bottom, and hollowed and covered with a whitish coating. They rested on an inflammatory nodule which extended away from the ulcerations (Figure 1).

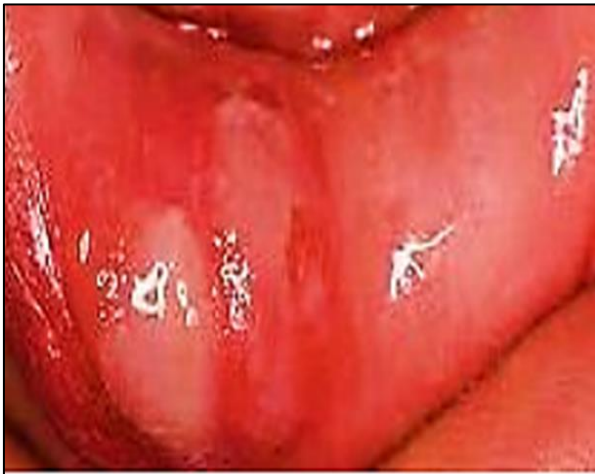

Figure 1: Ulcerations of the lower half-lip

Other ulcerations were found on the ventral side of the tongue and uvula with the same characteristics. No examination was undertaken to find the etiology due to the patient's financial arrangements.

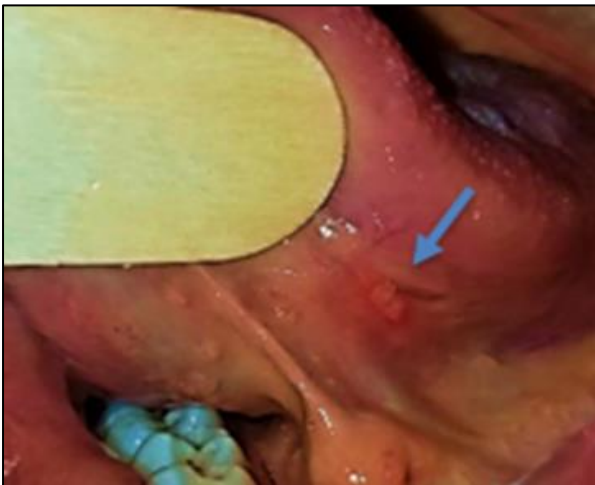

Figure 2: lingual ulceration

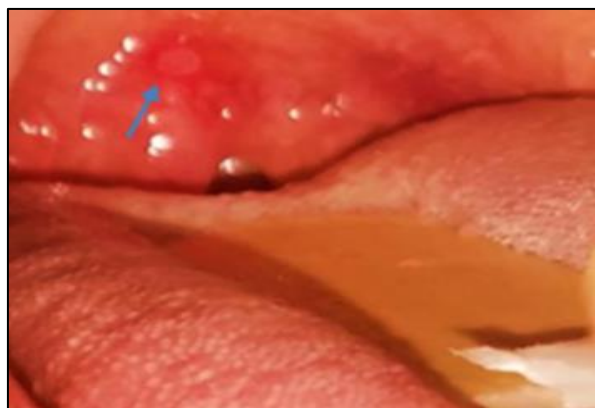

Figure 3: Ulceration of the uvula

The lesions disappeared three weeks after local symptomatic treatment (mouthwashes based on chlorhexidine gluconate 0.2%) and submucosal injections of Betamethasone.

A month later, we noticed the appearance of another ulceration on the lower right hemi-lip associated with scarring flanges overflowing the mucosal side.

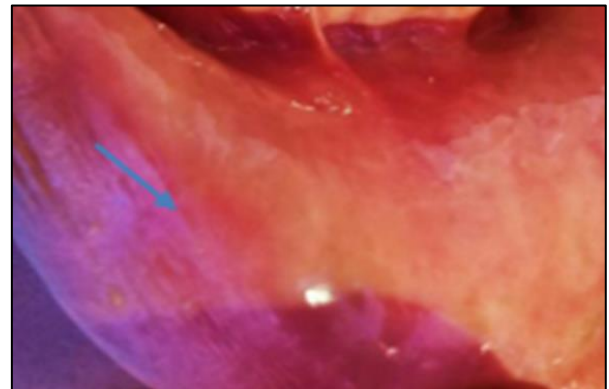


Figure 4: Absence of ulcerations at 3 weeks

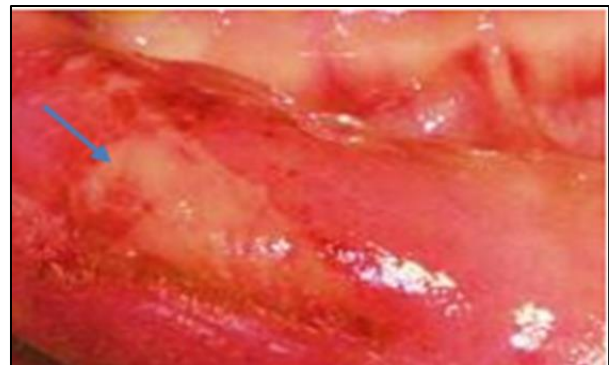

Figure 5: Recurrence at 1 month

The suggested diagnostic hypotheses for this clinical picture were: recurrent oral aphthosis, cyclic neutropenia, vitamin B12 deficiency. Further investigations were made and the hematologic bilan revealed megaloblastic anemia (Hb: 11 g / dl, VGM: 110fl) and neutropenia at 750 / mm³. The serum vitamin B12 value was 135 pmol / L and 132 pmol / L, respectively, at the first and second doses.

A biopsy was performed to confirm the diagnosis. Histologic examination showed accessory salivary glands sit with significant chronic inflammation that partially destroys them. There was a dense infiltrate made of lymphocytes and polymorphonuclear neutrophils, not invading the epithelium. This aspect was suggestive of sutton peradentitis , as shown in (Figure 6).

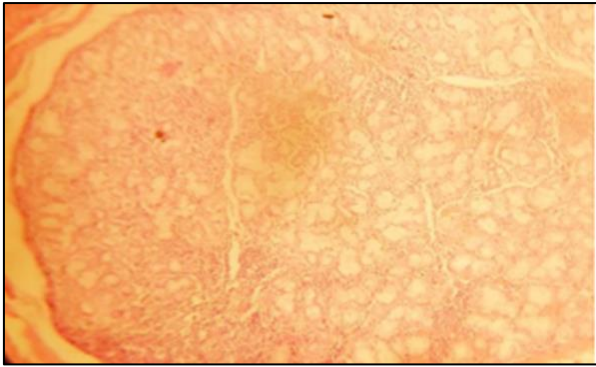


Figure 6: Histopathological features of Sutton's disease.

The confrontation of the collected elements was in favor of a disease sutton secondary to vitamin B12 deficiency.

The Treatment Initiated Was Based On:

- Colchicine, at a dose of 1 mg / day for 2 months; ▪ prednisone 40 mg / day for 8 days. A dosage reduction was made of 5 mg every other day, then 5 mg / day.
- Vitamin B12 at a rate of 1 mg / day for 3 months
- Omeprazole-metronidazoleclarithromycin (40 mg / 2 × 500 mg / day-500 mg 2 × day) for 6 weeks Complete healing of ulcerations was observed 4 weeks after the start treatment.

Two months later, no recurrence was observed, and biological parameters returned to normal except cyanocobalamin values (140 pmol / L). It was therefore decided on a longterm substitution treatment (vitamin B12 at a rate of 1 mg / day for 6 months).

After regular follow-up for more than 2 years, the lesions were lower in terms of frequency (greater than 6 months), volume (less than 1 cm) and pain.

DISCUSSION

Sutton's disease or Sutton's periadenitis is a major oral aphthosis. This recurrent and painful pathology, characterized by giant persistent necrotizing ulcers, disappears, sometimes leaving retractile fibrous scars (Bilancia, A., & Altobella, L.1970).

The disease often begins at puberty and can progress through exacerbations and remissions for about 20 years (COULON, J., & PIETTE, E).

This chronology is close to the case described. The ulcerations have a predilection for the non-keratinized mucosa (Ruhl,C.M. *et al.*, 1997), and the areas rich in accessory salivary glands such as the lips, the tongue, the soft palate and the anterior pillars of the veil, the uvula.

Some of these localisations are found in our description. Large, deep, oedematous, single or multiple

ulcerations often persist beyond 2 weeks. They most often recur on initial sites with cicatricial fibrosis (Ruhl, C.M. *et al.*, 1997).

The functional signs are important to type of dysphonia, dysphagia, hyper-sialorrhea (Akintoye, S.O., & Greenberg, M.S. 2005). This is the case of our patient who presented an odynophagia.

The pathophysiology of foot-and-mouth disease is not fully understood. Some non-specific findings allow for are immune assumptions in the aphthous recurrent oral. It would appear that the aphthous ulcer is due to cytotoxic action of T lymphocytes CD4 + and CD8 + cells and monocytes-macrophages vis-à-vis of the epithelium buccal (Burruano, F., & Tortorici, S. 2000; Słebioda, Z. *et al.*, 2014), but the factor triggering of these reactions is not not elucidated.

The factors favoring Sutton's disease are multiple and uncertain. For this case two favoring factors were retained: genetic susceptibility and vitamin B12 deficiency.

More than 40% of patients with recurrent oral aphthosis may report a vague notion of familial oral aphthosis (Ship, I. I. 1972). These patients may have canker sores at an earlier age (Burruano, F., & Tortorici, S. 2000). This hypothesis is reinforced by the patient's family history.

About 20% of patients with recurrent oral aphthosis may have hemantin deficiency (Porter, S. R. *et al.*, 1988). Vitamin B12 deficiencies cause serious alterations in humoral or cellular immunity. This deficiency often results in mouth ulcers, glo ssites, stomatitis and angular cheilitis.

The patient did not have any significant clinical signs suggestive vitamin B12 deficiency. However, the vitamin B12 deficiency was evoked during the diagnostic procedure from the discrete clinical signs. This deficit is oriented by macrocytic anemia and confirmed later by the determination of cyanocobalamin.

Histologically, Sutton's disease is characterized by inflammatory lesions of the epithelium, connectivetissue, and accessory salivary glands with intranuclear inclusions (Burruano, F., & Tortorici, S. 2000). The inflammatory infiltrate, where neutrophils predominate, affects vessels of larger caliber at depth (Burruano, F., & Tortorici, S. 2000).

The diversity of therapies proposed in Sutton's disease, reflects the difficulty of finding a specific and effective treatment. This is especially so since the curative treatment must be administered after the search for the cause. Research that often proves fruitless because of the plurality and co- dynamism of etiologies.

It is therefore important initially to control the symptoms and to reduce the duration of the lesions. Treatment may be local and often uses corticosteroids, antiseptics, antibiotics, or local anesthetics (Laccourreye, O. *et al.*, 1995). We limited ourselves to local corticosteroids and antiseptics.

In a second step, if ulcerations persist, an immunomodulator is recommended. These include dapsone, colchicine, thalidomide, levamisole, pentoxifylline (Stanley, H. R. 1973; Hello, M. *et al.*, 2010). Colchicine was preferred because of its availability, cost and tolerance.

The colchicine seems depolymerizing proteins microtubule inflammatory cells, inhibiting chemotaxis, mobilization, the adhesiveness and the lysosomal degranulation (Ruah, C. B. *et al.*, 1988; Seçkin, H. Y. *et al.*, 2016).

Of course it is necessary to join to this treatment, the treatment of etiology. In our case, it was vitamin B12 deficiency, probably due to chronic *Helicobacter pylori* gastritis.

CONCLUSION

Sutton's disease is major and recurrent oral aphthosis. Lesions predominate in areas rich in accessory salivary glands. The etiological diagnosis is not always certain, but it is necessary to look for a hemantimic deficiency even if the clinical signs are discrete.

The management is often ineffective because of recurrences and the absence of a curative treatment. However, it is based on: symptomatic treatment and elimination of favoring factors.

REFERENCES

1. Sutton, R. L. (1941). Recurrent Scarring Painful Aphthae: Amelioration With Sulfathiazole In Two Cases. *Journal of the American Medical Association*, 117(3), 175-176.
2. Bilancia, A., & Altobella, L. (1970). Case of Sutton's disease. *Archivio italiano di dermatologia, venereologia, e sessuologia*, 36(3), 174.
3. Coulon, J., & Piette, E. Aphthes banals, aphtose buccale récidivante et maladie de Behçet. *Encycl Méd Chir (Paris). Stomatologie*, 22-050.
4. Ruhl, C.M., Gleich, L.L., Biddinger, P.W., & Gluckman, J.L. (1997). Sutton's disease. *Am J Otolaryngol*, 18(3), 214-6.
5. Akintoye, S.O., & Greenberg, M.S. (2005). Recurrent aphthous stomatitis. *Dent Clin North Am*, 49(3), 47.
6. Burruano, F., & Tortorici, S. (2000). Major aphthous stomatitis (Sutton's disease): etiopathogenesis, histological and clinical aspects. *Minerva stomatologica*, 49(1-2), 41-50.
7. Ślebioda, Z., Szponar, E., & Kowalska, A. (2014). Etiopathogenesis of recurrent aphthous stomatitis and the role of immunologic aspects: literature review. *Archivum immunologiae et therapiiae experimentalis*, 62(3), 205-215.
8. Ship, I. I. (1972). Epidemiologic aspects of recurrent aphthous ulcerations. *Oral Surgery, Oral Medicine, Oral Pathology*, 33(3), 400-406.
9. Porter, S. R., Scully, C., & Flint, S. (1988). Hematologic status in recurrent aphthous stomatitis compared with other oral disease. *Oral Surgery, Oral Medicine, Oral Pathology*, 66(1), 41-44.
10. Laccourreye, O., Durand, H., Fadlallah, J. P., Brasnu, D., Pages, J. C., & Lowenstein, W. (1995). Sutton's disease (peradenitis mucosa necrotica recurrens). *Annals of Otolaryngology, Rhinology & Laryngology*, 104(4), 301-304.
11. Stanley, H. R. (1973). Management of patients with persistent recurrent aphthous stomatitis and Sutton's disease. *Oral Surgery, Oral Medicine, Oral Pathology*, 35(2), 174-179.
12. Hello, M., Barbarot, S., Bastuji-Garin, S., Revuz, J., & Chosidow, O. (2010). Use of thalidomide for severe recurrent aphthous stomatitis: a multicenter cohort analysis. *Medicine*, 89(3), 176-182.
13. Ruah, C. B., Stram, J. R., & Chasin, W. D. (1988). Treatment of severe recurrent aphthous stomatitis with colchicine. *Archives of Otolaryngology-Head & Neck Surgery*, 114(6), 671-675.
14. Seçkin, H. Y., Bütün, I., Baş, Y., Takcı, Z., & Kalkan, G. (2016). Effects of colchicine treatment on mean platelet volume and the inflammatory markers in recurrent aphthous stomatitis. *Journal of Dermatological Treatment*, 27(4), 389-391.