

Case Report

Diagnoses and Treatment of Acute Pancreatitis Due to Hydatid Cysts of the Liver: A Case Report

Abderraouf Bataiche^{*1}, Hakim Rahmoune², Nada Boutrid², Mouni Abdelmoumene¹ and Naouel Lemdaoui¹

¹Department of general surgery B, ben badis university hospital, Constantine, Algeria

²LMCVGN Laboratory, Setif-1 University, Algeria

Article History

Received: 02.06.2020

Accepted: 10.06.2020

Published: 20.06.2020

Journal homepage:

<http://www.easpublisher.com/easms/>

Quick Response Code



Abstract: Hydatid disease is a major health problem worldwide. The acute pancreatitis is a rare complication of this disease. We reported the case of 53 years-old man, who presented with upper abdominal pain, jaundice, a high level of lipase and Abdominal CT scan showed an hydatid cysts lesion and an inflammatory pancreas. Acute pancreatitis was treated in first time and after that a surgery was performed treating the hydatid liver cyst. The patient made an uneventful recovery after surgery.

Keywords: acute pancreatitis, hydatid liver cyst, diagnoses, treatment.

Copyright © 2020 The Author(s): This is an open-access article distributed under the terms of the Creative Commons Attribution **4.0 International License (CC BY-NC 4.0)** which permits unrestricted use, distribution, and reproduction in any medium for non-commercial use provided the original author and source are credited.

INTRODUCTION

Hydatid disease caused by the larval stage of the *Echinococcus* parasite is a public health problem in endemic countries. Hydatid disease can involve any organ. The liver is the most common organ involved and, together with the lungs, account for 90% of cases. Other involved sites (less than 10% of cases) are muscles, bones, kidneys, brain, and spleen (Makni, A. *et al.*, 2012). Hydatid acute pancreatitis, as a result of hydatid material that enters the bile duct, is a rare complication of hydatid liver disease, and there are only a few cases reported in the literature (Zeytunlu, M. *et al.*, 2004). We describe two cases who presented acute pancreatitis as a complication of intrabiliary rupture of hepatic hydatid cysts.

CASE REPORT

A 53 year-old man, without any medical or surgical history was admitted to the hospital for epigastric pain and jaundice that had started one week earlier. The pain was constant, radiating from the back. There was no history of drug or alcohol ingestion. On physical examination, the patient was in good condition OMS 0, jaundiced with dark urine and discolored faeces. Laboratory tests revealed a lipase count of 7313 IU/L (normal 73 - 393 IU/L), C-reactive protein (CRP) 254.7 mg/L (normal 0 - 5 mg/L), leukocyte 18.5

$10^3/\mu\text{L}$ (normal 4.0 - 11.0 $10^3/\mu\text{L}$), granulocytes 15.6 $10^3/\mu\text{L}$ (normal 2.0 - 8.0 $10^3/\mu\text{L}$), total bilirubin 42.2 mg/l (normal 0-12 mg/l), conjugated bilirubin 23.6 mg/l (normal 0 - 3 mg/L), alkaline phosphatase 708 IU/l (normal 100-290 IU/L), gamma glutamyl transferase (GGT) 723 IU/L (normal 0 - 55 IU/L), aspartate aminotransferase (ASAT) 276 IU/L (normal 0 - 37 IU/L), alanine aminotransferase (ALAT) 434 IU/L (normal 0 - 41 IU/L), Ultrasonography and computer tomography (CT) of the abdomen revealed an hydatid cysts in the V, VII and VIII segment of the liver measured 10 cm (figure 1) ruptured into the intra biliary ducts. Dilatation of the intra biliary duct and the main biliary duct measured 15.5 mm (figure 2) and a diffusely swollen pancreas with indurations around it (figure 3). The Patient was treated at first for his acute pancreatitis using intravenous fluids, pain medication and fasting. Laboratory values returned to normal within ten days. Control CT scan showed the resolution of inflammatory phenomena and a new rupture of the cyst throw diaphragm in the thorax (figure 4). Patient was referred after that to surgery where a complete disconnection and excision of the hydatid cyst with pericystectomy was performed, extirpation of the daughter cysts and membranes after a choledocotomy and the placement of a T-tube in the main bile duct. The ruptured diaphragm was excised and sutured after

thoracic lavage. The patient made an uneventful recovery.

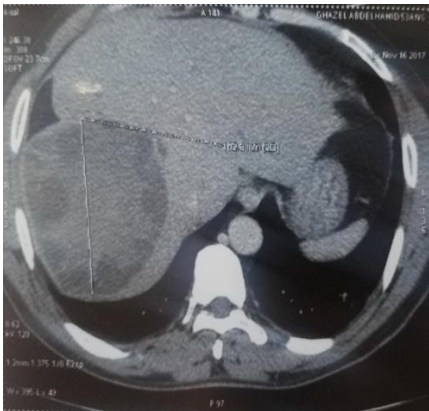


Figure 1: hydatid liver cyst in the V VII and VIII segment of the liver.

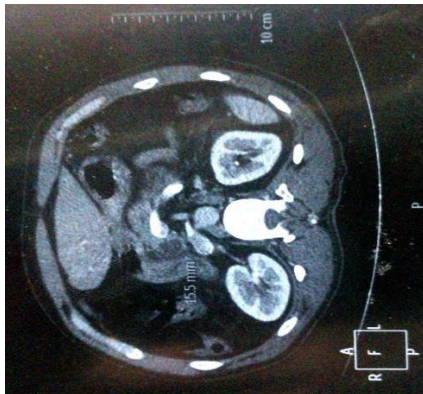


Figure 2: dilatation of the main biliary duct (15.5 mm)

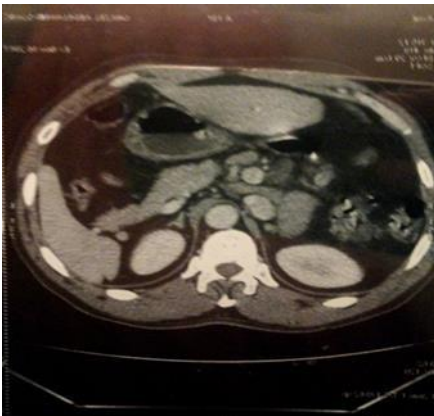

Figure 3: diffusely swollen pancreas with indurations around it

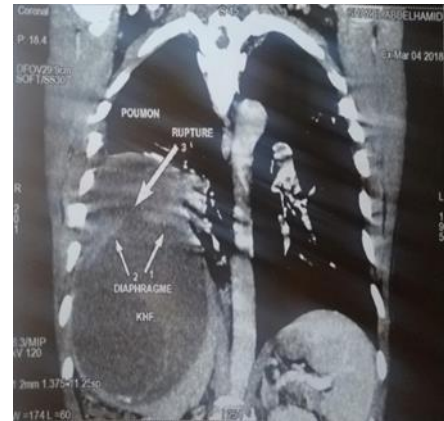

Figure 4: hydatid liver cyst rupture in the thorax.

DISCUSSION

The main causes of acute pancreatitis are gallstones and chronic alcohol abuse, accounting for 75% of all cases (Sherlock, S., & Dooley, J. 2002). There are rare reports in the international medical literature of acute pancreatitis resulting from intrabiliary rupture of a hydatid cyst (Bellara, I. L. *et al.*, 2004 July). However, in endemic areas, some authors advocate that it's not as rare as reported (Sáez-Royuela, F. *et al.*, 1999).

The pathogenesis of acute pancreatitis due to hydatid disease of the liver open to the biliary tree. Results to a high Hydrostatic pressure which exceeds inside the hydatid cyst that in bile duct, caused the rupture and fistulation of the hydatid cyst into the bile ducts (Sherlock, S., & Dooley, J. 2002). This communication can lead to expulsion of hydatid cyst material (membranes, scolices, daughter cysts) into the biliary tree and may cause cholestatic jaundice and recurrent cholangitis. The passage of this material through the papilla of Vater can cause transient occlusion of the pancreatic duct and/or bile reflux into the pancreatic duct and it may initiate acute pancreatitis. A local allergic reaction to echinococcus antigens inside the ampulla may also play a part in the initiation of pancreatitis (Veyrac, M. *et al.*, 1985).

There are no specific symptoms of the hydatid acute pancreatitis. Diagnose can be suspected by the presence of epigastric pain, the association of acute cholangitis, jaundice and infection.

Biological parameter (serum pancreatic enzymes, hydatid serology) and imaging allowed to confirm the diagnose of the both of the disease and the complication (El Idrissi, H. D. *et al.*, 1996). Serology is useful to confirm the diagnosis of hydatidosis; however, a negative serological result does not exclude the diagnosis. About 50% of cases have negative serology and false-positive results can be caused by cysticercosis (Al-Toma, A. A. *et al.*, 2004).

In the patient described above, the diagnosis was made on the basis of a marked increase in the serum concentrations of lipase, in addition to CT scan evidence of pancreatitis which also evaluate its gravity. CT scan has permitted to diagnose the hydatid liver cysts and objective the leak into the biliary tract. The dilatation of all biliary tree confirm the presence of a low obstruction wich is also the cause of acute pancreatitis. This obstruction is most probably due to migration of hydatid material in the biliary ducts since there is no gallstones.

The endoscopic sphincterotomy efficacy and safety for the treatment of intrabiliary rupture of hydatid cyst is well established (Özaslan, E., & Bayraktar, Y. 2002 ; & Ponchon, T. *et al.*, 1987). However, in the treatment of hydatid acute pancreatitis, the successful use of this technique has been very rarely reported (Sáez-Royuela, F. *et al.*, 1999). Endoscopic sphincterotomy has also been used postoperatively to speed the closure of bliairy leak by facilitating drainage of the obstructed biliary tract (Dumas, R. *et al.*, 1999).

The classic treatment for hydatid cysts ruptured into the bile ducts is surgery with exploration of the Cyst Bile Duct through a choledochotomy, placement of a T. tube, clearance of cyst remnants and surgical excision of the hydatid cyst or cysts, by enucleation or by pericystectomy. However, such operations are associated with morbidity, mortality and prolonged hospitalization (Tacyildiz, I. *et al.*, 2004).

Our patient was initially treated for his acute pancreatitis, using medical treatment which was Satisfying to cure the pancreas. Secondly for the liver disease, we performed a cyst disconnection from diaphragm and complete excision with pericystectomy, extirpation of the daughter cysts and membranes after a choledocotomy and the placement of a T-tube in the main bile duct. This procedure was satisfying in our case and the post-procedure course was uneventful.

CONCLUSION

Acute pancreatitis is a rare complication of hydatid liver cyst disease ruptured into the biliary ducts. radiological examination may be very useful to diagnoses and surgical approach remains the principal radical treatment in hydatid liver cyst ruptured into biliary ducts preventing thus its complications.

REFERENCES

1. Al-Toma, A. A., Vermeijden, R. J., & van de Wiel, A. (2004). Acute pancreatitis complicating intrabiliary rupture of liver hydatid cyst. *European journal of internal medicine*, 15(1), 65-67.
2. Bellara, I. L., Amara, H., Hablani, N., Harzallah, L., Abbassi, D. B., & Kraiem, C. (2004, July). Pancréatite aiguë d'origine hydatique: à propos d'un

- cas. In *Annales de chirurgie* (Vol. 129, No. 6-7, pp. 372-375). Elsevier Masson.
3. Dumas, R., Le Gall, P., Hastier, P., Buckley, M. J. M., Conio, M., & Delmont, J. P. (1999). The role of endoscopic retrograde cholangiopancreatography in the management of hepatic hydatid disease. *Endoscopy*, 31(03), 242-247.
4. El Idrissi, H. D., Ridai, M., & Zerouali, N. O. (1996). Pancréatite d'origine hydatique. *La Presse médicale* (1983), 25(40), 2022-2024.
5. Makni, A., Jouini, M., Kacem, M., & Safta, Z. B. (2012). Acute pancreatitis due to pancreatic hydatid cyst: a case report and review of the literature. *World Journal of Emergency Surgery*, 7(1), 7.
6. Özaslan, E., & Bayraktar, Y. (2002). Endoscopic therapy in the management of hepatobiliary hydatid disease. *Journal of clinical gastroenterology*, 35(2), 160-174.
7. Ponchon, T., Bory, R., & Chavaillon, A. (1987). Endoscopic retrograde cholangiography and sphincterotomy for complicated hepatic hydatid cyst. *Endoscopy*, 19(04), 174-177.
8. Sáez-Royuela, F., Yuguero, L., López-Morante, A., Pérez-Álvarez, J. C., Martín-Lorente, J. L., & Ojeda, C. (1999). Acute pancreatitis caused by hydatid membranes in the biliary tract: treatment with endoscopic sphincterotomy. *Gastrointestinal endoscopy*, 49(6), 793-796.
9. Sherlock, S., & Dooley, J. (2002). Diseases of the liver and Biliary system. 11th Ed. *Oxford: Blackwell Scientific Publicatins*, 511-516.
10. Tacyildiz, I., Aldemir, M., Aban, N., & Keles, C. (2004). Diagnosis and surgical treatment of intrabiliary ruptured hydatid disease of the liver. *South African Journal of Surgery*, 42(2).
11. Veyrac, M., MACHAYEKHI, J. P., KITSCHKE, B., Costalat, G., & Barneon, G. (1985). Pancréatite aiguë révélatrice d'une rupture de kyste hydatique du foie dans les voies biliaires. Valeur de la cholécystite à éosinophiles associée. *Gastroentérologie clinique et biologique*, 9(3), 271-272.
12. Zeytinlu, M., Coker, A., Yüzer, Y., Ersöz, G., Aydin, A., Tekeşin, O., ... & Batur, Y. (2004). Hydatid acute pancreatitis. *Turk J Gastroenterol*, 15(4), 229-232.