

Case Report

Decompression, Vertebroplasty and Internal Fixation for Primary Non-Hodgkin's Lymphoma of the Lumbar Spine: A Case Report and Literature Review

Yangliang Huang ^{*1} and Yi Zhong ²¹Department of Spine Surgery, the First Affiliated Hospital, Sun Yat-Sen University, Guangzhou, 510700, China²Key Laboratory of Neuroscience, School of Basic Medical Science, Guangzhou Medical University, Guangzhou, 511436, China**Article History**

Received: 05.06.2020

Accepted: 11.06.2020

Published: 26.06.2020

Journal homepage:<http://www.easpublisher.com/easms/>**Quick Response Code**

Abstract: Non-Hodgkin's lymphoma is a rare primary neoplasm of the epidural spine of the elderly. Although lymphomatous involvement of vertebral bodies will be recognized as marked high signal on STIR images, the radiological features are still unspecific, which make it difficult for identification. We report a case of a 86-year-old man complaining of serious lower lumbar pain and lower limbs muscle weakness. The PET-CT scan showed invasion of the fifth lumbar vertebra without migration. As the posterior vertebral body wall collapsed, never roots were compressed by the instability. The Spinal Instability Neoplastic Score (SINS) was 13. Vertebroplasty was performed to consolidate the vertebral and followed by decompression and internal fixation, afterward, the pain and lower limb weakness was relieved. The histopathological examination revealed a diffuse lymphoma. R-miniCHOP chemotherapy was applied following the surgery in the department of hematology. Until the 12 months follow-up, the clinical result was satisfied.

Keywords: Lymphoma; spine; surgical treatment

Copyright © 2020 The Author(s): This is an open-access article distributed under the terms of the Creative Commons Attribution **4.0 International License (CC BY-NC 4.0)** which permits unrestricted use, distribution, and reproduction in any medium for non-commercial use provided the original author and source are credited.

INTRODUCTION

Spinal involvements are estimated to occur in 5.8 and 6.5% of patients with Hodgkin and non-Hodgkin lymphoma (Siegel, R. L. *et al.*, 2015). As a spinal lesion is usually a late manifestation of systemic, disseminated disease, it causing epidural spinal neurological compression is rare (Uehara, M. *et al.*, 2013). Lower lumbar pain and neurological defect being the initial manifestation is even unusual. Given the radio sensitive nature of lymphoma, the treatment of surgical intervention in the management of spinal lymphoma remains unclear and controversial (Koeller, K. K., & Shih, R. Y. 2016), however, patients with spinal lymphoma most commonly undergo surgical intervention for a pathological diagnosis and stabilization of spinal instability, which is not possible with radiation alone. In this report, an 86-year-old man complaining of serious lower lumbar pain and lower limb muscle weakness was treated by decompression, vertebroplasty and internal fixation for primary Non-Hodgkin's lymphoma of the lumbar Spine.

CASE REPORT

History

A 86-year-old man with history of 2 weeks of sudden onset of lower back pain and progressing lower limb weakness presented to our department. The pain could be increased by lumbar movement and became more serious at night. Initially, he was diagnosis as vertebral infection and given antibiotics in another hospital. His symptom did not relieve, even progressed. He came to our hospital for a PET-CT scan and consulted for his lower limb symptoms. The PET-CT scan identified a lesion located at the fifth lumbar vertebral without any another invasion. When he was arrived at the out-patient clinic, he could stand just for a few minutes. The radicular pain could be aggravated by extension of lumbar spine. He did not complain urinary retention or bowel movement problems. He denied any other systemic diseases. He was conscious and did not have any difficulty of communication.

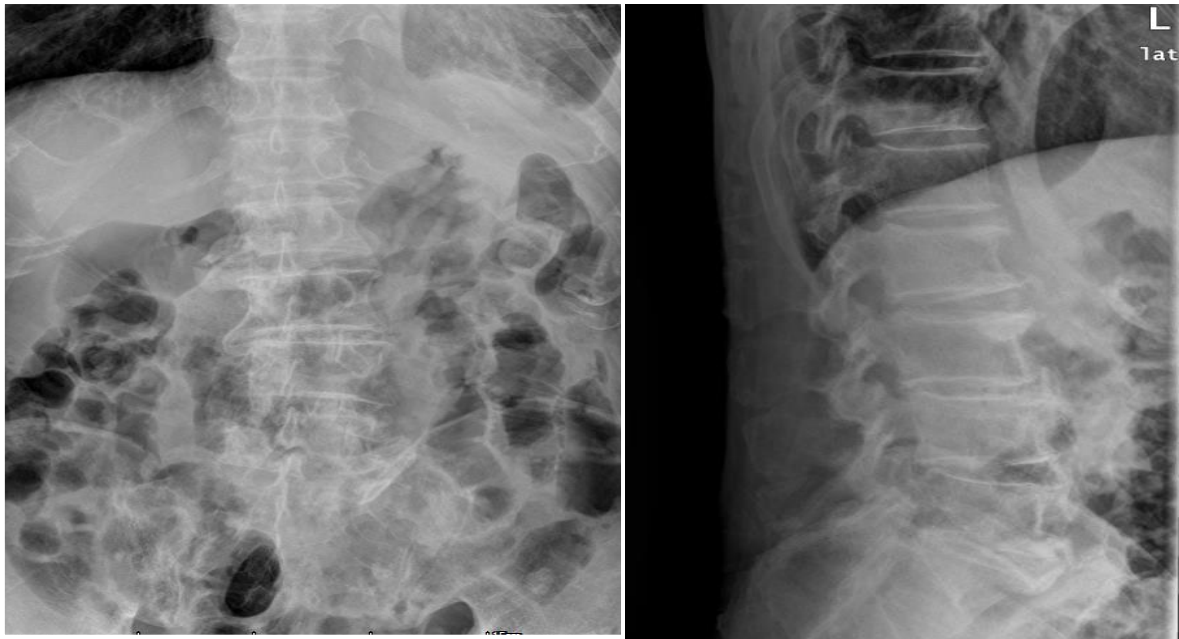


Fig. 1 Pre-operative X-ray pictures

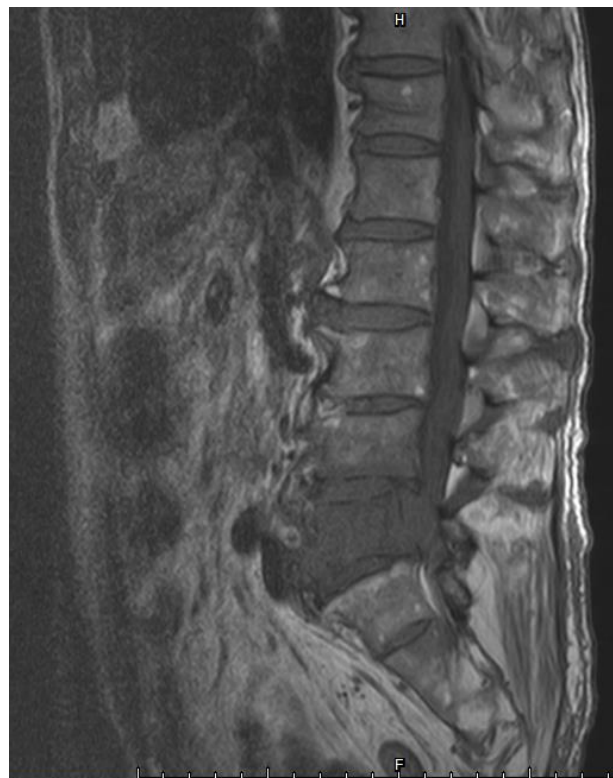

Fig. 2 pre-operative T1 image

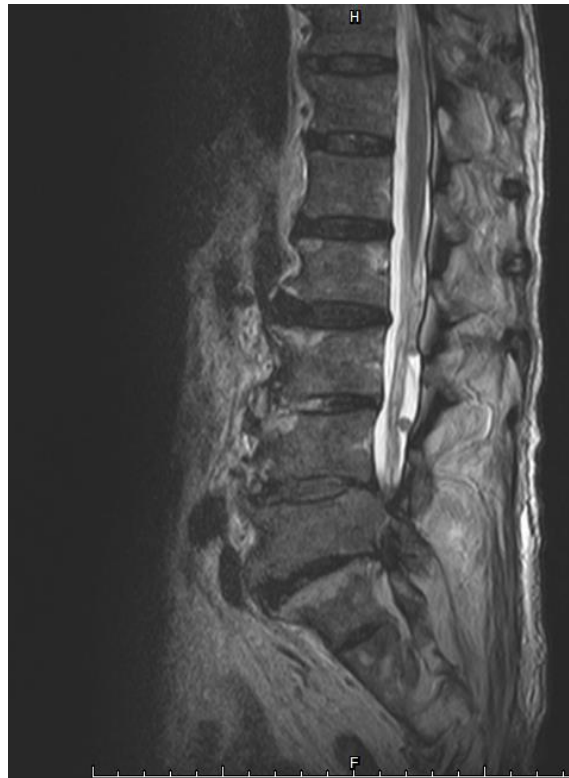

Fig. 3 pre-operative T2 image

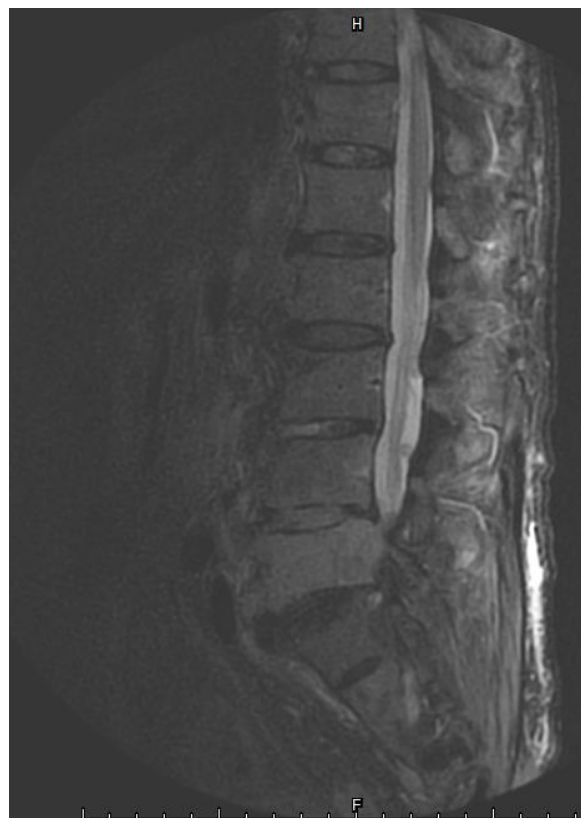

Fig. 4 pre-operative STIR image

Examinations

Physical examination revealed decreased motor and sensory function below knee of both sides, mainly impairment located at the toe and foot extension. The manual muscle strength test demonstrated 3/5 strength on the left and 3/5 on the right. Increase of deep tendon reflex was not noted. Babinski sign was negative bilaterally. Muscle tonus of lower extremities was not increased. The dysuria function was normal. Pre-operative CT scans imaging showed pathological destruction and loss of anterior column support of the L5 vertebral, the nerve roots were compressed by the collapsed vertebral body wall and pre-existing lumbar spine stenosis. The posterolateral elements had been invaded either. The pre-operative MRI showed severe spinal stenosis at L5 secondary to a suspected tumor mass. The mass was isointense on T1-weighted images and hyperintense on T2-weighted images with marked high signal on STIR images. The Spinal Instability Neoplastic Score (SINS) is 13 which indicated unstable. Pre-operative laboratory examinations consisted of complete blood count, electrolytes, liver, renal function tests, urinalysis. They were all normal.

Surgical treatment

The collapse of L5 posterior wall were considered to be responsible for clinical symptoms. Before decompression, vertebroplasty was performed to consolidate the vertebra and reduce bleeding. Total laminectomy of L5 was performed. The L5 and S1 nerve roots were totally explored and decompressed. During surgery, Gel like mass was located at the posterior wall of L5 vertebral body. The tumor mild adherent to the nerve roots, which is not difficult to clean up. The wound was closed in the usual multilayered fashion. He was treated postoperatively with a rigid hard plastic lumbar orthosis that had to be worn constantly for 12 weeks.

Pathological findings and Postoperative course

Histopathological examination confirmed the lesion to be non-Hodgkin lymphoma. Pathology specimens were immunohistochemically stained, the result was reported as: CD20, CD79a, Kappa, Lambda (+); CD38, CD138, MPO (-).

As there was no leakage of cerebrospinal fluid, the drainage was removed 2 days later. One week later, his muscle strength was improved. The manual muscle test demonstrated 4/5 strength on the left limbs and 4/5 on the right limbs. After rehabilitation, the patient could stand up independently and walked for 10 meters. After the wound was completely healed, R-CHOP (rituximab, cyclophosphamide, doxorubicin, vincristine, prednisolone) was applied following the surgery in the department of hematology. He was discharged home 2 weeks later. After follow-up for 3 months, there was no recurrence of pain, neurologic examination was normal.

The design and performance of this study conformed to ethical standards of Helsinki Declaration and our national legislation. It was approved by Medical Ethical Committee of our institution. The patient was enquired whether or not willing to take part in a scientific report and informed consent forms were signed by himself.

DISCUSSION

Epidural location for lymphoma is observed in 0.1% to 6.5% of all lymphoma cases, most of them are non-Hodgkin, which are over 85% (Messina, C. *et al.*, 2015). Lymphoma can be located in every spinal compartment with the thoracic spine being the most common location. In MRI pictures, epidural lymphoma is isointensity on T1WI, isointense or hyperintense on T2WI, with homogeneous enhancement. Lymphomatous involvement of vertebral bodies will be recognized as T1 isointense to slightly hypointense, and T2 isointense to hyperintense lesions with marked high signal on STIR images (Han, S. *et al.*, 2016). PET has proved useful for staging and monitoring treatment response in lymphomas (Paes, F. M. *et al.*, 2010).

As the radiosensitivity nature of lymphoma, radiotherapy should be considered as the first choice even in cases of neurological decline (Avilés, A. *et al.*, 2002). Under the principle that nonsurgical management was favored over surgery whenever possible, the surgical indication remains unclear and controversial. For most of time, surgery should be offered under the following conditions: 1. Emergent neurologic deterioration, such as acute and significant decline in motor function, with or without dysuria function; 2. Stabilization for obvious or impending instability; 3. Biopsy should be considered appropriate when computed tomography (CT)-guided needle biopsies were non-diagnostic (Kaloostian, P. E. *et al.*, 2014). Since the radicular pain could be deteriorated by the extension movement in this case, mechanical instability was clearly identified. Surgical intervention was applied according to the second point mentioned above.

Recently, a standardized, easily applicable tool for grading spinal neoplastic related instability which is called SINS was created by a panel of spine oncology experts (Fourney, D. R. *et al.*, 2011). The score was established to aid decision for surgical candidates. Since its inter- and intra-observer reliability across the various medical and surgical disciplines have been proved by many studies, the clinical acceptance is increasing. In this case, the score was 13 which indicated unstable. The score was verified by location 3, pain 3, bone lesion 1, spinal alignment 2, vertebral body collapse 1, posterolateral involvement of spinal element 3.

Since there was pre-existing lumbar stenosis, decompression and stabilization were both important for this patient (Laufer, I. *et al.*, 2013; Fisher, C. G. *et al.*, 2014; & Sun, H. *et al.*, 2014). Stabilization was accomplished by internal fixation from L4 to S1, and anterior support of L5 vertebral by vertebroplasty. Therefore, the anterior and posterior column were all mechanically stable, while a number of the lymphoma cells was eliminated by the bone cement. The decompression was accomplished by L5 total laminectomy. During decompression, the lamina was removed from middle line to outside. The middle line spine canal was less occupied than the outside. Attention was taken to avoid nerve root injury and cerebrospinal fluid leakage. After the lamina was removed, the L4 and L5 nerve roots were clearly exposed to ensure the decompression was successful.

Despite new advances in lymphoma therapies and surgical decompression in cases of epidural lymphoma, the prognosis is still relatively poor. The longest survival period has been reported for primary osseous lymphoma (10-year survival rate approximately 90%) (Chang, C. M. *et al.*, 2013; & Thomas, A. G. *et al.*, 2011).

CONCLUSIONS

As nonsurgical intervention is the first treatment of lymphoma. The role of surgery in the management of spinal lymphoma remains unclear, and mechanical instability remains the only agreed upon surgical indication (Arana, E. *et al.*, 2016). In this retrospective study, we present the epidemiological data, surgical indications, treatment and the comparative outcome data for an aged gentleman who underwent decompression and stabilization of lumbar spine. The clinical outcome was satisfied.

REFERENCES

1. Arana, E., Kovacs, F. M., Royuela, A., Asenjo, B., Pérez-Ramírez, Ú., Zamora, J., ... & Álvarez, M. A. (2016). Spine Instability Neoplastic Score: agreement across different medical and surgical specialties. *The Spine Journal*, 16(5), 591-599.
2. Avilés, A., Fernández, R., González, J. L., García, E. L., Neri, N., Talavera, A., & Diaz-Maqueo, J. C. (2002). Spinal cord compression as a primary manifestation of aggressive malignant lymphomas: long-term analysis of treatments with radiotherapy, chemotherapy or combined therapy. *Leukemia & lymphoma*, 43(2), 355-359.
3. Chang, C. M., Chen, H. C., Yang, Y., Wang, R. C., Hwang, W. L., & Teng, C. L. J. (2013). Surgical decompression improves recovery from neurological deficit and may provide a survival benefit in patients with diffuse large B-cell lymphoma-associated spinal cord compression: a case-series study. *World journal of surgical oncology*, 11(1), 90.
4. Fisher, C. G., Schouten, R., Versteeg, A. L., Boriani, S., Varga, P. P., Rhines, L. D., ... & Sahgal, A. (2014). Reliability of the Spinal Instability Neoplastic Score (SINS) among radiation oncologists: an assessment of instability secondary to spinal metastases. *Radiation Oncology*, 9(1), 69.
5. Fourney, D. R., Frangou, E. M., Ryken, T. C., DiPaola, C. P., Shaffrey, C. I., Berven, S. H., ... & Chou, D. (2011). Spinal instability neoplastic score: an analysis of reliability and validity from the spine oncology study group. *Journal of clinical oncology*, 29(22), 3072-3077.
6. Han, S., Yang, X., Jiang, D., Zhou, W., Liu, T., Yan, W., ... & Xiao, J. (2016). Surgical outcomes and prognostic factors in patients with diffuse large B-cell lymphoma-associated metastatic spinal cord compression. *Spine*, 41(15), E943-E948.
7. Hashi, S., Goodwin, C. R., Ahmed, A. K., & Sciubba, D. M. (2018). Management of extranodal lymphoma of the spine: a study of 30 patients. *CNS oncology*, 7(2), CNS11.
8. Kaloostian, P. E., Yurter, A., Zadnik, P. L., Sciubba, D. M., & Gokaslan, Z. L. (2014). Current paradigms for metastatic spinal disease: an evidence-based review. *Annals of surgical oncology*, 21(1), 248-262.
9. Koeller, K. K., & Shih, R. Y. (2016). Extranodal lymphoma of the central nervous system and spine. *Radiologic Clinics*, 54(4), 649-671.
10. Laufer, I., Rubin, D. G., Lis, E., Cox, B. W., Stubblefield, M. D., Yamada, Y., & Bilsky, M. H. (2013). The NOMS framework: approach to the treatment of spinal metastatic tumors. *The oncologist*, 18(6), 744-751.
11. Messina, C., Christie, D., Zucca, E., Gospodarowicz, M., & Ferreri, A. J. (2015). Primary and secondary bone lymphomas. *Cancer treatment reviews*, 41(3), 235-246.
12. Paes, F. M., Kalkanis, D. G., Sideras, P. A., & Serafini, A. N. (2010). FDG PET/CT of extranodal involvement in non-Hodgkin lymphoma and Hodgkin disease. *Radiographics*, 30(1), 269-291.
13. Peng, X., Wan, Y., Chen, Y., Chen, L., He, A., Liao, W., ... & Zou, X. (2009). Primary non-Hodgkin's lymphoma of the spine with neurologic compression treated by radiotherapy and chemotherapy alone or combined with surgical decompression. *Oncology reports*, 21(5), 1269-1275.
14. Siegel, R. L., Miller, K. D., & Jemal, A. (2015). Cancer statistics, 2015. *CA: a cancer journal for clinicians*, 65(1), 5.
15. Sun, H., Yang, Z., Xu, Y., Liu, X., Zhang, Y., Chen, Y., ... & Xia, J. (2015). Safety of percutaneous vertebroplasty for the treatment of metastatic spinal tumors in patients with posterior wall defects. *European Spine Journal*, 24(8), 1768-1777.

16. Thomas, A. G., Vaidhyanath, R., Kirke, R., & Rajesh, A. (2011). Extranodal lymphoma from head to toe: part 1, the head and spine. *American Journal of Roentgenology*, 197(2), 350-356.
17. Uehara, M., Takahashi, J., Hirabayashi, H. *et al.*, (2013). Hodgkin's disease of the thoracic vertebrae. *Spine J.* 13, 59-63.