

Research Article

Percutaneous Pulmonary Valve implantation (PPVI): Analysis of cases in a Bangladeshi Center

Prof: Nurun Nahar Fatema^{*1}, Dr Mansur Al Jufan², Prof Stephan Shubert³ and Dr Mir Mahmud Hossain⁴¹ Congenital and structural Interventionist, FCPS, FRCP (Edin), FACC, FSCAI, Head of Pediatric Cardiology, CMH Dhaka² Structural and interventional cardiologist, King Faisal Specialist Hospital and Research Center, Riyadh, KSA³ Consultant Pediatric cardiologists, German Heart Center, Berlin⁴ Chief Cardiac Anaesthesiologist, CMH Dhaka**Article History**

Received: 20.07.2020

Accepted: 05.08.2020

Published: 20.08.2020

Journal homepage:<http://www.easpublisher.com/easms/>**Quick Response Code**

Abstract: As a resource constraint country, it was a difficult task to introduce percutaneous pulmonary valve implantation (PPVI) with Melody™. We aimed to see the outcome of our cases in this background. Retrospective analysis of six cases who had PPVI with Melody™ in Combined Military Hospital, Bangladesh. Inclusion criteria were dysfunctional conduit between right ventricle (RV) and pulmonary artery causing (a) Symptoms of exceptional dyspnoea of various grade (NYHA II, III, IV) (b) RVEVD >150ml/m²+regurgitant fraction >40% (c) RVOT peak instantaneous gradient > 30 mm Hg. (d) RV dysfunction (RVEF<40%). Patient fulfilled above criteria were selected and outcome were analyzed. Mean age was 9.56 ± 2.96 years, weight was 28.75 ± 8.61 kg, height was 137.5 ± 17.52 cm. Mean age at surgery was 4.25±2.72 years. Female were 66.66%. Aortic homograft was used in 66.66 % cases. Eighteen mm Ensemble was used in four (66.66%) cases and 20mm and 22 mm in one each. Immediate result was excellent with no residual PS in two cases and negligible residual flow acceleration across pulmonary valve in four cases. No PR seen in all except one. One patient developed bacterial endocarditis after 3 years and was treated. Aim of PPVI is to prolong the life expectancy of conduits which were placed surgically from right ventricle to pulmonary artery. It significantly reduces the number of surgeries to change conduit in total life span of patient.

Keywords: PPVI, Melody™, RVOT, Outcome, dysfunctioning conduit, analysis.

Copyright © 2020 The Author(s): This is an open-access article distributed under the terms of the Creative Commons Attribution **4.0 International License (CC BY-NC 4.0)** which permits unrestricted use, distribution, and reproduction in any medium for non-commercial use provided the original author and source are credited.

INTRODUCTION

Percutaneous Pulmonary valve implantation was first introduced by Bonhoeffer et al in 2000 (Bonhoeffer P *et al.*, 2000) to treat stenosis & regurgitation in a prosthetic conduit in the right ventricular outflow tract (RVOT). Although surgical replacement of conduit is associated with low mortality and morbidity, but operative risk is high in some cases after repeated sternotomies. In some cases surgery is also prohibited (Kevin Ong *et al.*, 2013). Multiple sternotomies and conduit replacement throughout life span is also troublesome (Holst KA *et al.*, 2011). Conduit are usually placed between right ventricle (RV) and Pulmonary artery (PA) in patient with Tetralogy of Fallot (TOF) with pulmonary stenosis or Pulmonary atresia (PA), Double out let right ventricle (DORV) with pulmonary stenosis (PS), Truncus arteriosus (TA), Transposition of great arteries (TGA) with PS and ventricular Septal Defect (VSD) etc. In Ross procedure, a homograft in a pulmonary position also require valved conduit. Surgical correction of RVOT obstructions are usually performed by transannular patch or by implanting biological valves like homograft or xenograft (Ansari MM *et al.*, 2015). Since the introduction in 2000, thousands of cases has been performed in Europe, America, other regions and there is significant improvements in valve designs and procedures and all the capable centers are trying to incorporate this procedure in their routine practice (Asoh K *et al.*, 2010; Lurz P *et al.*, 2008; McElhinney DB *et al.*, 2010). About 95% of the children with RVOT repair can survive up to adulthood, however all of them need one or two percutaneous of surgical reintervention (Jones MI *et al.*, 2018; Carminiti M *et al.*, 2015). In this study we included the variety that had surgically implanted prosthetic valves and conduits which degenerates in course of time even calcified, leading to stenosis, regurgitation or both. We started PPVI in Combined Military Hospital (CMH) Bangladesh with Melody™ pulmonary valves on 25th December 2012 as first ever team of South Asia (Fatema NN *et al.*, 2014) As a resource constraint country it was difficult to introduce such expensive valve (3000 USD), moreover there was no health insurance system existing for civilian population. Patient party has to pay for the valve and accessories. Melody™ pulmonary valves in these cases were arranged from various charities and corporate social responsibilities (CSR) fund. Moreover, pre stenting with covered CP stent or Andra bare metal stent and BIB balloons and other hardware increase the cost further beyond the limit. Aim of this study is to publish the outcome of our cases.

EXPERIMENTAL SECTION

It is a retrospective analysis of PPVI cases using Melody™ valve (Medtronic Inc, Minneapolis, MN, USA) since December 2012 to October 2019, performed in Combined Military Hospital, Dhaka, Bangladesh. Inclusion criteria were dysfunctional right ventricle (RV) to pulmonary artery (PA) conduit with:

1. RV systolic pressure $> 2/3^{\text{rd}}$ of systemic pressure in symptomatic patient.
2. RV systolic pressure $> 3/4^{\text{th}}$ of systemic pressure in asymptomatic patient.
3. Moderate to severe Pulmonary regurgitation with symptoms or
 - a) Moderate to severe RV dilatation
 - b) Moderate to severe RV dysfunction.
 - c) Impaired exercise capacity ($< 65\%$ predictive, NYHA class II, III, IV) Special criteria for using Melody™ were:
4. Diameter of conduit 16 mm – 22mm.
5. RVOT diameter not more than 22 mm
6. Coronary artery origin or course not closely related to RVOT.
7. Venous access adequate to allow 22 F sheath through femoral vein or Jugular Vein.

All the parameters were assessed from history, physical examination, surgical history and notes. ECG, CXR, Echocardiography were done. Echocardiographic assessment of RVOT conduit for peak pressure gradient across pulmonary valve (PS) was measured by CW doppler, pulmonary regurgitation (PR) by color doppler, RV dimensions (RVEDV ml/m², RVESV ml/m²) by Simpson method, RV ejection fraction (RVEF) by M-Mode, TR (CW Doppler) etc. Cardiac Magnetic resonance Imaging (CMRI) was not performed for non-availability. Diagnostic cardiac catheterization was performed for checking morphology of RVOT more accurately by balloon sizing and aortogram to exclude coronary compression during balloon occlusion of RVOT.

Melody pulmonary Valve: We used Melody™ Valve (Medtronic Inc, Minneapolis, MN) Which was approved by united states FDA in 2010 with HDE (Humanitarian device exemption), It consist of a harvested valve from a bovine jugular vein and is sutured into a platinum – iridium stent frame which is 28 mm long and 18 to 22 mm diameter. Crimped diameter is 6 mm.

Delivery System: The stent is crimped onto the Ensemble delivery system and can be expanded up to 22 mm diameter. It is a 22 French catheter with a balloon in balloon deployment design and has 18, 20, 22 mm outer diameter. The tip of the system is blue which corresponds with outflow suture of the stent. There are three proximal ports, green one for guidewire, indigo for inner balloon and orange for outer balloon.

Statistical analysis: Data were collected using Excel spread sheets. Results were presented as mean \pm standard deviation (SD); cases were shown individually, paired t test done where applicable.

RESULTS

Table 1 showed demographic profile of patients. Mean age was 9.56 years \pm 2.96 years. Female (66.66%) outnumbered male (33.33%). Mean weight was 28.75 \pm 8.61 kg. Height varied from 137.5 \pm 17.52 cm. Age at the time of surgery was 4.25 \pm 2.72 years. Four cases (66.66%) had pulmonary atresia and two had tetralogy of Fallot (33.33%). Four cases had Aortic homograft (66.66%), one had pulmonary homograft (16.67%) and one had Bovine valved pericardial conduit (16.67%). Four cases had BT shunt followed by Rastelli operation (66.66%), one had ToF repair followed by redo surgery within one year (16.67%) and one had single surgery (16.67%).

Table 2 showed Echocardiographic findings of study cases. Conduit stenosis was 45 mm Hg or more in all cases and regurgitation was moderate in 2 cases & severe in 4 cases. RVEDV was > 130 ml/m² in all cases. One patient had absent LPA, and one had RPA stenosis, one had RPA and LPA stenosis along with conduit stenosis.

Table 3 showed procedural data. General anesthesia (GA) was given in all cases, Access was transfemoral for all. Two CP stents were implanted in three cases and one stenteach inrest three cases. Mean fluoroscopy time was 65 \pm 9.36 minutes. Melody™ with 20 mm and 22 mm ensemble was used in two cases and 18 mm in four cases. Immediate complications like device embolization, dislocation or arrhythmia were not observed in any cases. Additional procedure was Balloon angioplasty (RPA) in one case (case 2) and RPA and LPA origin balloon angioplasty in one case (case 5).

Table 4 showed immediate outcome of the patient. Residual negligible stenosis of 10 to 16 mm Hg was observed in four cases. Two cases had no gradient. No residual PR was observed in 5 cases and trivial in one case. P-Value was significant.

Table 5 showed follow up of cases for any PS, PR, Infective endocarditis, and stent fracture. First case completed 8 years follow up. No complication was noticed. 2nd case was lost from follow up after 3 years, she had endocarditis after three years and was treated for 6 weeks, cured, and then lost from follow up. Third and fourth cases are in follow up for four years and no complications noted, fifth and sixth cases are in follow up for 6 months and had no complications.

Figure 1 showed RV angiogram with measurements.

Figure 2 and figure 3 showed stages of Melody™ valve implantation.

Table 1: Patient Data

	Demographics	Mean ± SD or n (%)	N=6
1	Age in years	9.56 ±2.96	
2	Gender		
	Female	4 (66.66%)	
	Male	2 (33.33%)	
3	Weight(kg)	28.75±8.61	
4	Height(cm)	137.5 ±17.52	
5	Age at the time of surgery(In years)	4.25 ±2.72	
6	Types of conduits		
	Aortic homograft	4 (18-23 mm) (66.66%)	
	Pulmonary homograft	1 (16.64%)	
	Bovine pericardial valve conduit	1 (16.67%)	
7	Primary diagnosis		
	TOF	2 (33.33%)	
	Pulmonary Atresia with VSD	4 (66.66%)	
8	Number of Surgeries		
	BT Shunt and Rastelli (Two)	4 (66.66 %)	
	TOF repair and Redo surgery with orthotropic conduit (two)	1 (16.67%)	
	ICR TOF with RV to PA conduit due to LAD originated from RCA (One)	1 (16.67%)	

Table 2: Echocardiographic Findings in study cases

Case	PS gradient	PR gradient	RVOT diameter	RVEDV	PA size & Branch PA stenosis
1	50mm Hg	Moderate	25 mm	140 ml/m ²	Absent LPA, RPA 14 mm
2	45 mm Hg	Moderate	26 mm	130 ml/m ²	RPA stenosis & 50 mm Hg
3	48 mm Hg	Severe	24 mm	140 ml/m ²	RPA 11.2 mm LPA 13 mm
4	56 mm Hg	Severe	20 mm	145 ml/m ²	RPA 12 mm LPA 13 mm
5	95 mm Hg	Severe	16 mm	140 m ¹ /m ²	RPA & LPA origin stenosis PPG 62 mm Hg & 66 mm Hg.
6	45 mm Hg	Severe PR	25 mm	130 ml/m ²	RPA 11 mm LPA 13 mm

PA- Pulmonary Artery, LPA- Left Pulmonary Artery.RPA- Right Pulmonary Artery, RVEDV- Right Ventricular End Diastolic Volume, RVESV- Right Ventricular End Systolic Volume, PS- Pulmonary Stenosis, PR- Pulmonary Regurgitation, RVOT- Right ventricular outflow tract.

Table 3. Procedure Data

Case	G/A sedation	Access	No of stent implanted/ Additional procedure	Type of stent	PPVI with Melody™, Ensemble used	Flouroscopy time in min/ mean±SD	Device dislocation	Device embolization	Arrhythmia
1	G/A	Trans femoral	2	CP	20 mm	62	Nil	Nil	Nil
2	G/A	Trans femoral	2 / RPA angioplasty	CP	18 mm	78	Nil	Nil	Nil
3	G/A	Trans femoral	2	CP	22 mm	68	Nil	Nil	Nil
4	G/A	Trans femoral	1	CP	18 mm	72	Nil	Nil	Nil
5	G/A	Trans femoral	1/ LPA and RPA origin angioplasty.	CP	18 mm	54 65±9.36	Nil	Nil	Nil
6	G/A	Trans femoral	1	CP	Melody 18 mm	56	Nil	Nil	Nil

Table 4. Immediate Outcome

Case No	Pre procedure Pulmonary valve gradient	Post procedure per gradient	P-Value	Pre pulmonary valve regurtation	Post Pulmonary valve regurtation	P -Value
1	50 mm Hg	10 mm Hg		Moderate	None	
2	45 mm Hg	40 mm Hg		Moderate	None	
3	48 mm Hg	15 mm Hg		Severe	None	
4	50 mm Hg	0 mm Hg	0.0006	Severe	None	0.0005
5	95 mm Hg	16 mm Hg		Severe	None	
6	45 mm Hg	15 mm Hg		Severe	None	

Table 5. Functional Outcome: Follow up

Variable	6-month (N=6)	03 Years (N=4)	06 Years (N=1)
Peak gradient (PS) mm Hg	9.33± 7.53	6.25 ± 7.5	10
Pulmonary regurgitation (PR)			
None	5	4	1
Trivial	1	0	0
Stent Fracture	-	-	-
Infective Endocardities	-	1	-

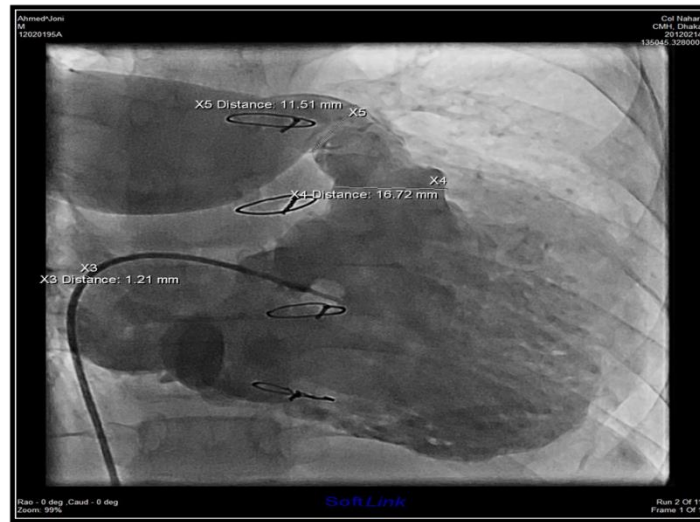

Figure 1. RV angiogram in case 1 showing absent LPA and conduit stenosis

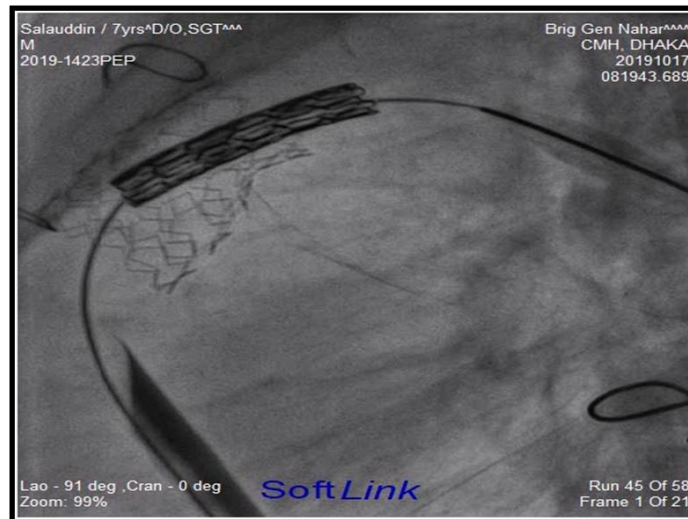


Figure2. Melody™ valve is ready for implantation

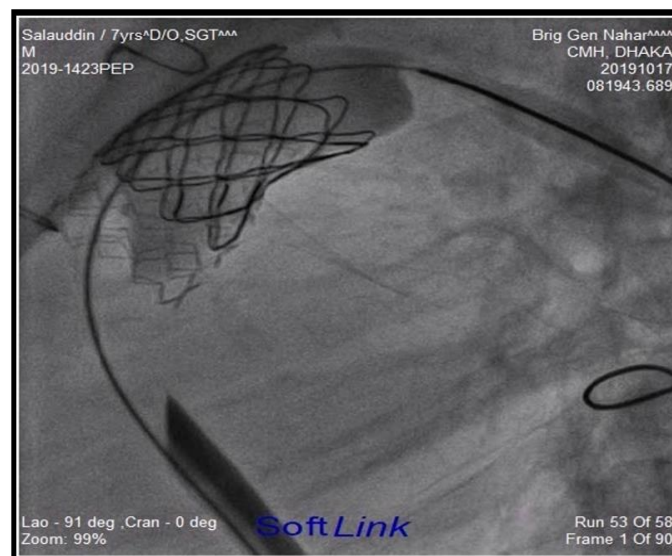


Figure3. Melody™ Valve after complete dilatation

DISCUSSIONS

Approximately 20% congenital heart disease has abnormalities in right ventricular outflow tract (Esmaili A *et al.*, 2019). Tetralogy of Fallot (TOF), Pulmonary atresia, Transposition of great arteries (TGA) with pulmonary stenosis, Truncus arteriosus etc. Following surgical repair, RVOT dysfunction is very common in these patients in the form of pulmonary valve regurgitation (PR) or pulmonary valve stenosis (PS), or both (Bonhoeffer P *et al.*, 2000; Kevin Ong *et al.*, 2013; Holst KA *et al.*, 2011; Ansari MM *et al.*, 2015). Many of them require change of conduits several times in their life span by surgical pulmonary valve replacement (SPVR) as valved conduit has limited life span (Jones MI *et al.*, 2018; Carmini M *et al.*, 2015).

Fatema NN *et al.*, 2014; Esmaili A *et al.*, 2019; Ran L *et al.*, 2019; Khambadkone S *et al.*, 2005; O'Byrne ML *et al.*, 2015). PPVI is an alternative treatment modality which could delay surgery by prolonging conduit life span and reducing the number of operations on the open heart. Since first implantation in 2000 by Phillip Bonhoeffer, thousands of cases were performed all over the world (Borik S *et al.*, 2015; Cheatham JP, *et al.*, 2015). Points in favor of doing PPVI than SPVR is (1) It delays the next surgery (2) Cost effective comparing to multiple surgery in life span of a patient (3) Outcome is good and hospital stay is less (4) In good hand procedure is very safe (Yuan S-M *et al.*, 2008; Kanter Kr *et al.*, 2015; Hallbergson A *et al.*, 2015). We did first case of our series as first ever case in South Asia on 25th December 2012 (Fatema NN *et al.*, 2014). In Bangladesh Paediatric Cardiology service was started in 1998. Since then patients were referred for RVOT reconstruction to surgeons. As there is no insurance support for cardiac treatment, many patients cannot go for first surgery even. Moreover, many of them need multiple surgeries (Therrien J *et al.*, 2005). In our OPD many patients reported with RVOT dysfunction with multiple previous surgeries, but they could not afford PPVI as valve is very expensive. So, in our set up it is very difficult to enroll a patient in first place. Out of six cases in the series, valves were arranged by personal effort of cardiologist with help of charity or donation. There were many hurdle's other than monetary crisis. Important one was non availability of cardiac magnetic resonance imaging (CMR) of heart. So, patients were included in the PPVI list based on detail echocardiography, CT Angiogram, and diagnostic cardiac catheterization. During catheterization, balloon sizing of the RVOT was performed to see the morphology of RVOT and coronaries arteries were checked for any compression simultaneously. Valves were ordered after confirming the case as perfect as possible. Mean age of our series was 9.56 ± 2.96 years (Table 1) which is much less than other studies (Esmaili A *et al.*, 2019). Age is comparatively less as pediatric cardiology practice was started in our country only two decades ago, so patients who underwent

surgery since then are still young. Mean age at the time of surgery was 4.25 ± 2.72 years, 66.66% were female in this series which does not correlate with others study (Carmini M *et al.*, 2015; Fatema NN *et al.*, 2014; Esmaili A *et al.*, 2019). Primary disease was tetralogy of Fallot in two cases and pulmonary atresia in 4 cases (TOF variant). These correlate with other studies (Therrien J *et al.*, 2005; Eicken A *et al.*, 2011).

Doppler Echocardiography was used to measure RV pressure from TR gradient, RVOT gradient from PPG across RVOT and quantitative color flow was used for PR grading (Yock PG *et al.*, 1984; Dragulescu A *et al.*, 2014). CMR and CT angiography techniques differ in terms of spatial, temporal resolution and radiation dose. Cardiac CT offers the advantage of high spatial resolution, fast acquisition at the expense of poor temporal resolution and ionizing radiation. CT angio can give proper idea about various diameters, calcification of conduits etc (Michellatezza *et al.*, 2018). A study published in European Journal of Radiology stated that CT analysis prior to percutaneous pulmonary valve implantation (PPVI) could help cardiologists to detect risk of coronary compression (Murray BH *et al.*, 2013) So invasive balloon occlusion aortogram to check coronary compression in high risk cases can be avoided by excluding them from PPVI list.

Relief of RVOT obstruction and pulmonary valve frequently results in PR which initiates a cascade of events leading to RV dilatation followed by dysfunction. There is also chance of RVOT or pulmonary artery stenosis, RVOT aneurysm, TR, LV dysfunction, AR, aortic root dilatation etc. Anatomy is complex sometime and associated with RVOT aneurysm (Geva T, 2011; Evel S *et al.*, 2019). CMR is required to delineate RVOT and to find out various volumes and ejection fractions fraction.

In almost all centers, RVOT dimension are assessed by MR angiogram through we have not. A study compared the assessment of RVOT dimension prior to PPVI by two types of MR, contrast enhanced magnetic resonance (CEMRA) angiography versus 3 D steady – state free precession sequence (SSFP). This study showed that CMR is a suitable technique for pre procedural assessment of RVOT for PPVI. Measurement of systolic SSFP showed excellent correlation with current gold standard and all suitable for precise sizing of the valve. This study verifies that the RVOT diameter depends on timing of acquisition: wider in SSFP –systole and smaller in SSFP- diastole (Khambadkone S *et al.*, 2005; Yuan S-m *et al.*, 2008; Evel S *et al.*, 2019).

In all cases of this series, PS gradient was more than 45 mm Hg and two cases had moderate PR, other four had severe PR, RVEDV was more than 130 ml/m² in all cases (Table2, Echocardiographic findings). RVOT morphology was assessed from CT

angiogram and diagnostic 2D cardiac catheterization (Fatema NN *et al.*, 2014).

Cardiopulmonary exercise test was performed in two cases (case 4, case 6) only following other guidelines (Geva T, 2011).

All our cases were performed under GA which correlates with other studies (Table 3) (Ran L *et al.*, 2019). CP stent was used in all cases with an aim to prevent stent fracture and valve durability.

Result of the procedure was assessed in the Catheterization Laboratory by measuring withdrawal gradient between pulmonary artery to RV (Table 4). It was "O" in two cases and negligible gradient of 10-16 mm Hg were noticed in other four cases. Pulmonary artery angiogram showed no PR in all cases except one with trivial PR. It correlates with other studies (Lurz P *et al.*, 2008; Khambadkone S *et al.*, 2005; Fiszer R *et al.*, 2017; Butera G *et al.*, 2012). In follow up visits, echocardiography was done to look for (1) PS (2) PR (3) RVEDV (4) RVEF (5) TR etc. Chest X-Ray was done to look for stent fracture and electrocardiography (ECG) for arrhythmia. In follow up echocardiography RVEDV was reduced in all cases which correlates with other studies (Yock PG *et al.*, 1984; Dragulescu A *et al.*, 2014; Michellatezza *et al.*, 2018; Murray BH *et al.*, 2013). RVOT gradient was not increased and trivial PR was noticed in one case, RVEF also improved. Most common complication seen in other study is stent fracture (Fraisie A *et al.*, 2014; McElhinney DB *et al.*, 2011). In this cohort no stent fracture was noticed (Table 5). In another study stent fracture was observed in 5% cases (McElhinney DB *et al.*, 2011). Infective Endocarditis is a potential threat for PPVI cases (Nordmeyer J *et al.*, 2011; Buber J *et al.*, 2013). In one (Case no 2) of our case, infective endocarditis was diagnosed after 3 years of PPVI, was treated successfully but lost from follow up thereafter. In our experience preparation of catheterization laboratory with all accessories presuming all kind of complications which may happen, ensuring supply of all hardware for an infrequent procedure considering resource constraint setup was a challenge. Availability of patient with conduit dysfunction in the background of only two-decade history of pediatric cardiac services is also a factor for less number of cases. To fulfill operational and institutional requirement and guideline is must for successful outcome of PPVI (Villafane J *et al.*, 2014; Hijazi ZM *et al.*, 2015).

CONCLUSION

As PPVI with Melody™ valve is expensive. it is difficult for resource constraint set up to continue it as routine basis unless insurance facility is available. Strict inclusion criteria were followed in learning curve and Pretesting was done in every case to avoid stent fracture and to enhance valve life.

REFERENCES

1. Ansari, M. M., Cardoso, R., Garcia, D., Sandhu, S., Horlick, E., Brinster, D., ... & Piazza, N. (2015). Percutaneous pulmonary valve implantation: present status and evolving future. *Journal of the American College of Cardiology*, 66(20), 2246-2255.
2. Asoh, K., Walsh, M., Hickey, E., Nagiub, M., Chaturvedi, R., Lee, K. J., & Benson, L. N. (2010). Percutaneous pulmonary valve implantation within bioprosthetic valves. *European heart journal*, 31(11), 1404-1409.
3. Batra, A. S., McElhinney, D. B., Wang, W., Zakheim, R., Garofano, R. P., Daniels, C., ... & Rhodes, J. (2012). Cardiopulmonary exercise function among patients undergoing transcatheter pulmonary valve implantation in the US Melody valve investigational trial. *American heart journal*, 163(2), 280-287.
4. Bonhoeffer, P., Boudjemline, Y., Saliba, Z., Merckx, J., Aggoun, Y., Bonnet, D., ... & Kachaner, J. (2000). Percutaneous replacement of pulmonary valve in a right-ventricle to pulmonary-artery prosthetic conduit with valve dysfunction. *The Lancet*, 356(9239), 1403-1405.
5. Borik, S., Crean, A., Horlick, E., Osten, M., Lee, K. J., Chaturvedi, R., ... & Benson, L. (2015). Percutaneous pulmonary valve implantation: 5 years of follow-up: does age influence outcomes?. *Circulation: Cardiovascular Interventions*, 8(2), e001745.
6. Buber, J., Bergersen, L., Lock, J. E., Gauvreau, K., Esch, J. J., Landzberg, M. J., ... & Marshall, A. C. (2013). Bloodstream infections occurring in patients with percutaneously implanted bioprosthetic pulmonary valve: a single-center experience. *Circulation: Cardiovascular Interventions*, 6(3), 301-310.
7. Butera, G., Milanese, O., Spadoni, I., Piazza, L., Dotti, A., Ricci, C., ... & Carminati, M. (2012). Melody transcatheter pulmonary valve implantation. Results from the Registry of the Italian Society of Pediatric Cardiology (SICP). *Cardiol Young*, 22: S26.
8. Carminati, M., Pluchinotta, F.R., & Piazza, L. (2015). Echocardiographic assessment after surgical repair of tetralogy of Fallot. *frontPediatr*, 3: 3.
9. Cheatham, J. P., Hellenbrand, W. E., Zahn, E. M., Jones, T. K., Berman, D. P., Vincent, J. A., & McElhinney, D. B. (2015). Clinical and hemodynamic outcomes up to 7 years after transcatheter pulmonary valve replacement in the US melody valve investigational device exemption trial. *Circulation*, 131(22), 1960-1970.
10. Dragulescu, A., Friedberg, M. K., Grosse-Wortmann, L., Redington, A., & Mertens, L. (2014). Effect of chronic right ventricular volume overload on ventricular interaction in patients after

- tetralogy of Fallot repair. *Journal of the American Society of Echocardiography*, 27(8), 896-902.
11. Eicken, A., Ewert, P., Hager, A., Peters, B., Fratz, S., Kuehne, T., ... & Berger, F. (2011). Percutaneous pulmonary valve implantation: two-centre experience with more than 100 patients. *European heart journal*, 32(10), 1260-1265.
 12. Esmaeili, A., Khalil, M., Behnke-Hall, K., y Gonzalez, M. B. G., Kerst, G., Fichtlscherer, S., ... & Schranz, D. (2019). Percutaneous pulmonary valve implantation (PPVI) in non-obstructive right ventricular outflow tract: limitations and mid-term outcomes. *Translational Pediatrics*, 8(2), 107.
 13. Evel, S., Gottschling, S., & Lucke, C. (2019). 3D assessment of RVOT dimension prior percutaneous pulmonary valve implantation comparison of contrast enhanced magnetic resource angiography versus 3D steady state free precession sequence. *The international Journal of Cardiovascular imaging*, 35,1453-1463
 14. Fatema, N.N., & Hossain, M.R. (2014). Percutaneous Pulmonary Valve Implantation (PPVI) with Melody®: First Ever Case Report in South Asia. *BCPS Journal*, 32,102-106,2014..
 15. Fiszer, R., Dryżek, P., Szkutnik, M., Góreczny, S., Krawczuk, A., Moll, J., ... & Białkowski, J. (2017). Immediate and long-term outcomes of percutaneous transcatheter pulmonary valve implantation. *Cardiology Journal*, 24(6), 604-611.
 16. Fraisse, A., Aldebert, P., Malekzadeh-Milani, S., Thambo, J. B., Piéchaud, J. F., Aucoururier, P., ... & Assaidi, A. (2014). Melody® transcatheter pulmonary valve implantation: results from a French registry. *Archives of cardiovascular diseases*, 107(11), 607-614.
 17. Geva, T. (2011). Repaired tetralogy of Fallot: The roles of cardiovascular magnetic resonance in evaluating pathophysiology and for pulmonary valve replacement decision support, *J Cardiovasc Magn Reason*, 13:9.
 18. Hallbergson, A., Gauvreau, K., Powell, A. J., & Geva, T. (2015). Right ventricular remodeling after pulmonary valve replacement: early gains, late losses. *The Annals of thoracic surgery*, 99(2), 660-666.
 19. Hijazi, Z.M., Ruiz, C.E., & Zahn. (2015). Operator and institutional requirements for transcatheter valve repair and replacement, part III: pulmonic valve. *J Am CollCardiol*, 65, 2556–2563.
 20. Holst, K. A., Dearani, J. A., Burkhart, H. M., Connolly, H. M., Warnes, C. A., Li, Z., & Schaff, H. V. (2011). Risk factors and early outcomes of multiple reoperations in adults with congenital heart disease. *The Annals of thoracic surgery*, 92(1), 122-130.
 21. Jones, M.I., & Qureshi, S.A. (2015). Recent advances in transcatheter management of pulmonary regurgitation after surgical repair of tetralogy of Fallots. F1000Res.7.(pubmed) 2018.
 22. Kanter, K. R., Budde, J. M., Parks, W. J., Tam, V. K., Sharma, S., Williams, W. H., & Fyfe, D. A. (2002). One hundred pulmonary valve replacements in children after relief of right ventricular outflow tract obstruction. *The Annals of thoracic surgery*, 73(6), 1801-1807.
 23. Khambadkone S, Coats L, Taylor A, Boudjemline Y, Derrick G, Tsang V, Cooper J, Muthurangu V, Hegde SR, Razavi RS, Pellerin D, Deanfield J, Bonhoeffer P (2005). Percutaneous pulmonary valve implantation in humans: results in 59 consecutive patients. *Circulation*, 112(8):1189–97
 24. Khambadkone, S., Coats, L., Taylor, A., Boudjemline, Y., Derrick, G., Tsang, V., ... & Pellerin, D. (2005). Percutaneous pulmonary valve implantation in humans: results in 59 consecutive patients. *Circulation*, 112(8), 1189-1197.
 25. Lurz, P., Coats, L., & Khambadkone, S. (2008). Percutaneous pulmonary valve implantation: Impact of evolving technology and learning curve on clinical outcome. *Circulation*, 117(15), 1964-1972.
 26. Lurz, P., Coats, L., Khambadkone, S., Nordmeyer, J., Boudjemline, Y., Schievano, S., Muthurangu, V., Lee, T.Y., Parenzan, G., Derrick, G., Cullen, S., Walker, F., Tsang, V., Deanfield, J., Taylor, A.M., & Bonhoeffer, P. (2008). Percutaneous pulmonary valve implantation: impact of evolving technology and learning curve on clinical outcome. *Circulation*, 117(15):1964–72.
 27. McElhinney, D. B., Cheatham, J. P., Jones, T. K., Lock, J. E., Vincent, J. A., Zahn, E. M., & Hellenbrand, W. E. (2011). Stent fracture, valve dysfunction, and right ventricular outflow tract reintervention after transcatheter pulmonary valve implantation: patient-related and procedural risk factors in the US Melody Valve Trial. *Circulation: Cardiovascular Interventions*, 4(6), 602-614.
 28. McElhinney, D. B., Hellenbrand, W. E., Zahn, E. M., Jones, T. K., Cheatham, J. P., Lock, J. E., & Vincent, J. A. (2010). Short-and medium-term outcomes after transcatheter pulmonary valve placement in the expanded multicenter US melody valve trial. *Circulation*, 122(5), 507–516.
 29. Murray, B. H., McElhinney, D. B., Cheatham, J. P., Zahn, E. M., Berman, D. P., Sullivan, P. M., ... & Jones, T. K. (2013). Risk of coronary artery compression among patients referred for transcatheter pulmonary valve implantation: a multicenter experience. *Circulation: Cardiovascular Interventions*, 6(5), 535-542.
 30. Nordmeyer, J., Lurz, P., Khambadkone, S., Schievano, S., Jones, A., McElhinney, D. B., ... & Bonhoeffer, P. (2011). Pre-stenting with a bare metal stent before percutaneous pulmonary valve implantation: acute and 1-year outcomes. *Heart*, 97(2), 118-123.
 31. O'Byrne, M. L., Glatz, A. C., Mercer-Rosa, L., Gillespie, M. J., Dori, Y., Goldmuntz, E., ... & Rome, J. J. (2015). Trends in pulmonary valve

- replacement in children and adults with tetralogy of fallot. *The American journal of cardiology*, 115(1), 118-124.
32. Ong, K., Boone, R., Gao, M., Carere, R., Webb, J., Kiess, M., & Grewal, J. (2013). Right ventricle to pulmonary artery conduit reoperations in patients with tetralogy of fallot or pulmonary atresia associated with ventricular septal defect. *The American journal of cardiology*, 111(11), 1638-1643.
33. Ran, L., Wang, W., Secchi, F., Xiang, Y., Shi, W., & Huang, W. (2019). Percutaneous pulmonary valve implantation in patients with right ventricular outflow tract dysfunction: a systematic review and meta-analysis. *Therapeutic advances in chronic disease*, 10, 2040622319857635.
34. Tezza, M., Witsenburg, M., Nieman, K., van de Woestijne, P. C., & Budde, R. P. (2018). Cardiac Ct to assess the risk of coronary compression in patient evaluated for percutaneous pulmonary valve implantation. *European Journal of cardiology*, 11;018.
35. Therrien, J., Provost, Y., Merchant, N., Williams, W., Colman, J., & Webb, G. (2005). Optimal timing for pulmonary valve replacement in adults after tetralogy of Fallot repair. *The American journal of cardiology*, 95(6), 779-782.
36. Villafañe, J., Baker, G. H., Austin III, E. H., Miller, S., Peng, L., & Beekman III, R. (2014). Melody® pulmonary valve bacterial endocarditis: experience in four pediatric patients and a review of the literature. *Catheterization and Cardiovascular Interventions*, 84(2), 212-218.
37. Yock, P. G., & Popp, R. L. (1984). Noninvasive estimation of right ventricular systolic pressure by Doppler ultrasound in patients with tricuspid regurgitation. *Circulation*, 70(4), 657-662.
38. Yuan, S. M., Mishaly, D., Shinfeld, A., & Raanani, E. (2008). Right ventricular outflow tract reconstruction: valved conduit of choice and clinical outcomes. *Journal of cardiovascular medicine*, 9(4), 327-337.