

Case Report

Herpes Zoster Ophthalmicus: A case study

Dr. Sohil Sharma¹ and Dr. Amit Sachdeva*²¹Junior Resident, Department of Ophthalmology, Indira Gandhi Medical College, Shimla, Himachal Pradesh²Senior Resident, Department of Community Medicine, Indira Gandhi Medical College, Shimla, Himachal Pradesh

Article History

Received: 20.08.2020

Accepted: 07.09.2020

Published: 30.09.2020

Journal homepage:

<http://www.easpublisher.com/easms/>

Quick Response Code



Abstract: Herpes zoster ophthalmicus (HZO) is a disease which occurs when the ophthalmic division of the trigeminal nerve is impaired as a result of reactivation of the varicella-zoster virus. Ophthalmic involvement has been considered the most important and potentially serious of all sites of Herpes Zoster virus. Objective of this present case study was to understand the modes of presentation and manifestations (ocular and extraocular) of HZO. This case study was conducted in the Outpatient Department of Ophthalmology at Indira Gandhi Medical College, Shimla (Himachal Pradesh). The Patient diagnosed with HZO was underwent a comprehensive ocular and extraocular examination. The ocular manifestations of HZO in the Patient was acute vesicular, dermatomal, painful, unilateral skin rash, hyperesthesia over his left forehead skin, Hutchinson sign present, Conjunctivitis in left eye with no exudates or obvious corneal scarring, Superficial punctate keratitis, stromal keratitis, Visual acuity Right eye-6/12, Left eye -6/18, IOP digitally normal bilaterally, Fundus cannot be assessed (CNBA) in the left affected eye, normal ocular movements in all planes with no diplopia, normal direct and consensual pupillary reflexes. Patient was medically treated with antiviral, antibiotic, cycloplegic and other supportive drugs and followed up.

Keywords: Herpes Zoster Ophthalmicus, Varicella Zoster virus, ocular manifestations.

Copyright © 2020 The Author(s): This is an open-access article distributed under the terms of the Creative Commons Attribution 4.0 International License (CC BY-NC 4.0) which permits unrestricted use, distribution, and reproduction in any medium for non-commercial use provided the original author and source are credited.

INTRODUCTION

Herpes zoster Ophthalmicus is rare case presenting in the ophthalmology department. Herpes Zoster (HZ) results from the reactivation of the VZV which remains latent in the primary sensory ganglion like Gasserian ganglion (Maiya, A.S., & Shenoy, S. 2013). It usually presents as a painful dermatomal rash. In addition to skin or mucosal involvement, VZV reactivation commonly affects the ophthalmic division of the trigeminal nerve and subsequently the eye (Catron, T., & Gene Hern, H. 2008). This manifestation is termed herpes zoster ophthalmicus (HZO) (Catron, T., & Gene Hern, H. 2008). Within the ophthalmic division of the trigeminal nerve, the frontal branch is most often involved (Maiya, A.S., & Shenoy, S. 2013). The annual incidence of HZ is 1.2-3.4/1000 persons (Maiya, A.S., & Shenoy, S. 2013). The incidence and prevalence of HZO appeared to be increasing due to reasons cited include an older population with inherent immune senescence, immunosuppression by pharmacotherapy, immunocompromising diseases such as AIDS, and universal varicella vaccination in the young leading to fewer exposures within the community to maintain cell-mediated immunity (El-Hamd, M. A., & Aboeldahab, S. 2019).

The prodromal phase of HZO normally includes fatigue, malaise, headache and low-grade fever

that lasts up to 1 week before the rash over the forehead appears (El-Hamd, M. A., & Aboeldahab, S. 2019). About 60% of patients have several degrees of dermatomal pain in the distribution of the ophthalmic nerve. ³ subsequently, erythematous macules appear along the involved dermatome then rapidly progressing over several days to papules and vesicles containing clear serous fluid and later pustules. These lesions rupture and typically crust over, requiring several weeks to heal (El-Hamd, M. A., & Aboeldahab, S. 2019).

The potential ocular manifestations of HZO are myriad and result from direct viral invasion, secondary inflammation and vasculitis, nerve damage and/or tissue scarring. Reported complications of HZO include lid vesicles and scarring, several forms of conjunctivitis and keratitis, episcleritis, scleritis, uveitis, secondary glaucoma, papillary abnormalities, acute retinal necrosis, optic neuritis, CRAO, cranial nerve palsies (III>VI>IV), orbital apex syndrome, localized arteritis and post herpetic neuralgia (Maiya, A.S., & Shenoy, S. 2013; & El-Hamd, M. A., & Aboeldahab, S. 2019).

Long-term structural complications of HZO includes glaucoma, cataract, corneal scarring, and postherpetic neuralgia (PHN) can have devastating outcomes on visual function and/or quality of life of the

patients (Maiya, A.S., & Shenoy, S. 2013; & El-Hamd, M. A., & Aboeldahab, S. 2019).

Antiviral drugs such as acyclovir, valacyclovir, and famciclovir remain the mainstay of therapy and are the most effective lines of treatment in preventing ocular affections when start within 72 h after the onset of the skin rash (Maiya, A.S., & Shenoy, S. 2013; & El-Hamd, M. A., & Aboeldahab, S. 2019). In order to ensure proper follow up and to minimize morbidity, the accurate and timely diagnosis of HZO and prompt management is extremely important (Catron, T., & Gene Hern, H. 2008).

CASE REPORT

Patient was 48-year-old man presented to the ophthalmology department of Indira Gandhi medical college, Shimla, Himachal Pradesh with two days history of painful skin rash on left side of the face involving, forehead, nasal part (Nasal bridge & tip of the nose) and left upper eyelid associated with blurring of vision and pain in left eye. The blurring was associated with mild photophobia and a left sided headache.

There was neither history of trauma, chemical exposure, discharge, foreign body sensation, sick contacts, sore throat, rhinorrhoea, hearing changes, skin rashes nor there was history of similar problems in the past.

The patient did not know if he had ever had chicken pox in the past and had not past history of medical problems like diabetes, hypertension, cancer etc., any previous surgeries, allergies, or any medications. There was no family history of skin rash. There was no history of any homemade remedy or any other treatment taken by the patient for the current problem. Patient was Non-Vegetarian, Non-alcoholic and Non-smoker.

Physical examination

Patient was moderately built and nourished and well oriented to time, place and person with vitals as follows: heart rate at 78 beats/minute, blood pressure at 136/84 mm Hg and respiration rate of 18 breaths/minute.

Patient had acute vesicular, dermatomal, painful skin rash on left side of the face involving forehead, nasal part (nasal bridge and tip of the nose) and left upper eyelid. Rash is unilateral and typically spares the lower eyelid. He had mild hyperesthesia over his left forehead skin and had no cervical or auricular lymphadenopathy.

Ophthalmological examination

1. Hutchinson sign present. Involvement of nasociliary branch of trigeminal nerve as an earliest sign

of ocular involvement in herpes zoster Ophthalmicus.

2. Conjunctivitis in left eye with no exudates or obvious corneal scarring.
3. Corneal involvement (Superficial punctate keratitis, stromal keratitis) on slit lamp examination.
4. Visual acuity Right eye-6/12, Left eye -6/18 on Snellen chart examination.
5. IOP- Digitally Normal bilaterally.
6. Fundus-CNBA in affected eye because of the superficial epithelial and stromal keratitis.
7. Ocular movements – Normal in all planes with no diplopia.
8. Direct and consensual pupillary reflexes present.

Diagnosis

On the basis of clinical history and examination diagnosis of Herpes Zoster Ophthalmicus was made.

Treatment

The following treatment was given to the patient on the first visit.

1. Tab. Valciclovir 1gm tds for 7 days. (Antiviral)
2. Eye drop moxifloxacin 0.5% w/v 1-drop qid for 7 days. (Antibiotic)
3. Eye drop carboxymethylcellulose 1drop qid 7 days. (Lubricant)
4. Ointment Acyclovir 3% 5 times a day. (Antiviral)
5. Eye drop cyclopentolate one drop at bed time. (Cycloplegic to relieve ciliary spasm, to relieve the pain and to prevent development of herpetic iridocyclitis. (synechia formation)

Patient was advised to take skin opinion. He was also advised to avoid exposure to dust, smoke, pollen etc. and to maintain proper hand hygiene.

Skin opinion

1. Added tab. Meganeuron-NT 1 tab. Bedtime after meal. (Methyl cobalamin plus Nortriptyline)
2. Advised to take plenty of fluids.

Follow –Up

Patient was advised to review after 7 days. After seven days on second visit, symptoms were relieved, pain and rash subsided, vision improved, redness & congestion decreased and lacrimation was also decreased. After 2 weeks on third visit, skin lesions almost completely resolved, ocular lesions resolved and conjunctival congestion improved.

DISCUSSION

Herpes zoster ophthalmicus occurs when the varicella-zoster virus is reactivated in the ophthalmic division of the trigeminal nerve (Vrcek, I. *et al.*, 2017). Risks for reactivation occur whenever there is any decline in the T-cell mediated immune response which includes normal aging, HIV/AIDS, and

immunosuppressive medications (Catron, T., & Gene Hern, H. 2008).

This virus damages the eye and its surrounding structures by secondary perineural and intraneural inflammation of sensory nerves (Shaikh, S., & Ta, C. 2002). Herpes zoster ophthalmicus represents approximately 10 to 25 % of all cases of herpes zoster (Shaikh, S., & Ta, C. 2002).

Classically, HZO begins with flu-like symptoms including fever, myalgia, and malaise for approximately one to two weeks (Bhatnagar, K. R. 2013). Most patients with herpes zoster ophthalmicus present with a painful unilateral periorbital vesicular rash distributed according to the affected dermatome. The skin manifestations usually begin as an erythematous macular rash and progressing over several days into papules, vesicles, and then pustules (Shaikh, S., & Ta, C. 2002).

Ocular involvement is not invariable in HZO; however, in patients with nasociliary nerve involvement (Hutchinson's sign) some case series indicate 100% go on to develop eye pathology (Catron, T., & Gene Hern, H. 2008; & Bhatnagar, K. R. 2013). A minority of patients may also develop conjunctivitis, keratitis, uveitis, and ocular cranial-nerve palsies (Shaikh, S., & Ta, C. 2002).

Permanent sequelae of ophthalmic zoster infection may include chronic ocular inflammation, loss of vision, and debilitating pain. It is thought that approximately 50% of those diagnosed with HZO will develop complication (Shaikh, S., & Ta, C. 2002).

Diagnostic tests are rarely indicated in HZO, as diagnosis can almost easily be made by a combination of history, physical and ocular examination.²Examinations should include a thorough ophthalmologic exam including external inspection, visual acuity, visual fields, extra ocular movements, pupillary response, funduscopy, intraocular pressure,

anterior chamber slit lamp exam, and corneal exam with and without staining. (Tzanck smear or Wright stain) (Catron, T., & Gene Hern, H. 2008; & Bhatnagar, K. R. 2013).

Treatment of HZO consists of local wound care, pain control, initiation of antiviral medication, antibiotics, cycloplegic drugs and other symptomatic treatment and is most effective in preventing ocular involvement and significantly decrease adverse outcomes related to HZO when begun within 72 hours after the onset of the rash (Catron, T., & Gene Hern, H. 2008; & Bhatnagar, K. R. 2013).

Timely diagnosis and management of herpes zoster ophthalmicus with referral to an ophthalmologist when ophthalmic involvement is present, are critical in limiting visual morbidity. Many poor outcomes of HZO can be prevented or ameliorated with early recognition, treatment, and referral (Shaikh, S., & Ta, C. 2002).

In all the patients with diagnosis of HZO early ophthalmologic follow up is mandatory (Catron, T., & Gene Hern, H. 2008). As per prognosis most patients with HZO have a single attack and do not go on to get further attacks. Visual outcome is generally good, with vision loss due to corneal problems rather than uveitis. Some patients, however, may develop chronic disease, including uveitis that requires long-term therapy and may persist for years (Bhatnagar, K. R. 2013).

CONCLUSION

HZO is a potentially serious, often devastating ocular disease occur due to reactivation of VZV in the distribution of the ophthalmic division of the trigeminal nerve. Usually HZO presents with classic findings that make diagnosis easy and simple. But full ophthalmologic exam is warranted in all the patients of HZO. Once the diagnosis of HZO has been made, appropriate antiviral and adjunctive drug therapy should be initiated as soon as possible to prevent serious ocular complications of HZO.

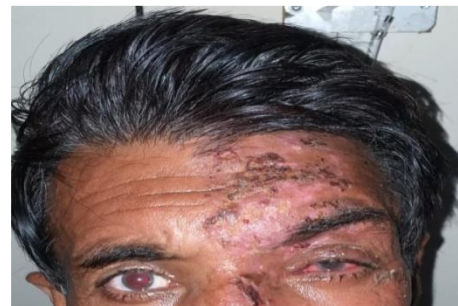
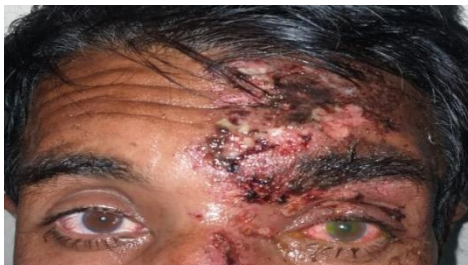
Image 1: Lesions involving left midline of face on first visit

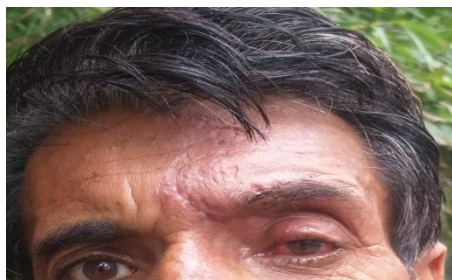

Image 2: Lesions of skin and eye improved on second visit

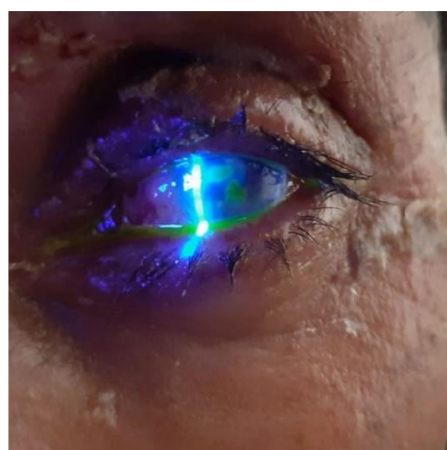

Image 3: skin and ocular lesions almost completely resolved on third visit

Image 4: Fluroscien stain positive epithelial defect present at 5 O clock position around 1mm in diameter




Image 5: Superficial punctate epithelial lesions and stromal infiltrates on slit lamp examination

REFERENCES

1. Bhatnagar, K. R. (2013). Herpes zoster ophthalmicus Medical Journal of Dr. D.Y. Patil University, July-September 6 (3), 292-293.
2. Catron, T., & Gene Hern, H. (2008). Herpes Zoster Ophthalmicus. *Western Journal of Emergency Medicine*, August, 9(3),174-176.
3. El-Hamd, M. A., & Aboeldahab, S. (2019). Herpes zoster ophthalmicus: clinicodemographic characteristics and outcomes of 64 Egyptian patients. *Egyptian Journal of Dermatology and Venerology*, 39(2), 49–56.
4. Maiya, A.S., & Shenoy, S. (2013). A Clinical Study of Herpes Zoster Ophthalmicus. *IOSR Journal of Dental and Medical Science*, 12(6), 9-13.
5. Shaikh, S., & Ta, C. (2002). Evaluation and management of herpes zoster ophthalmicus. *American family physician*, 66(9), 1723.
6. Vrcek, I., Choudhury, E., & Durairaj, V. (2017). Herpes zoster ophthalmicus: a review for the internist. *The American journal of medicine*, 130(1), 21-26.