

Original Research Article

Hepatic Pathophysiological Changes Induced by Nicotine and/or Sodium Nitrite Injection in Male Albino Rats

Fikry Ali Abushofa¹, Azab Elsayed Azab², Samia A. N. Alkadrawy³^{1,3}Department of Zoology, Faculty of Science, Zawia University, Zawia, Libya²Department of Physiology, Faculty of Medicine, Sabratha University, Sabratha, Libya

*Corresponding Author

Azab Elsayed Azab

Abstract: Background: Humans are exposed to chemicals from endogenous or exogenous sources, and they often cause functional failures of certain body systems. Nicotine is one of that chemical can reach to the body from tobacco or from liquid substances. Also, excessive use of preservatives, especially for meat preservation, adversely affects various body systems and causes damage to the body. One of the most common chemical uses is sodium nitrite. Liver is the main organ for the metabolism and detoxification from drugs and environmental toxicants of the body. There is no doubt that nicotine and sodium nitrate are causes a harmful effects on different body organs. **Objectives:** The present study aimed to evaluate the histological and biochemical changes induced by synchronized administration of nicotine and sodium nitrite in the liver of male albino rats. **Materials and methods:** 24 male F-344/NHsd Fischer rats were used for this study and divided into 4 groups. The first group was control group injected subcutaneously with saline daily for 6 weeks, the 2nd was the nicotine group and injected subcutaneous daily with 4mg nicotine/kg body weight for 6 weeks, the 3rd was sodium nitrite group injected subcutaneous daily with 0.4mg sodium nitrite/kg body weight for 6 weeks, the 4th was co-administered nicotine with sodium nitrite group injected subcutaneous with nicotine and sodium nitrite at a dose of 4 mg, and 0.4 mg/ kg body weight /day, respectively for 6 weeks. The livers were dissected out, weighted and specimens were taken and processed for light microscopic examinations. Blood samples were obtained for assessment of serum alanine aminotransferase (ALT), aspartate aminotransferase (AST), and alkaline phosphatase (ALP) activities, serum concentration of total protein, albumin, globulin, and direct bilirubin. **Results:** The results showed a significant increase in serum ALT, AST, and ALP activities, and direct bilirubin concentration, and a significant decrease in serum concentration of total protein, albumin, and globulin in rats treated with nicotine or sodium nitrite. Histopathological investigation of rats treated with nicotine or sodium nitrate showed many structural changes in the liver which included necrosis, congestion, degeneration, cell swelling, cell death, loss of endothelial lining the liver vessels. But, the simultaneous administration of nicotine and sodium nitrite caused additive effects in biochemical parameters and histopathological changes. **Conclusion:** It can be concluded that treatment of rats with nicotine or sodium nitrite caused a serious pathophysiological changes in the liver. Simultaneous administration of nicotine and sodium nitrite a more pathophysiological changes in the liver. Therefore, we should be reduce the use of preservatives, frozen meat and other recommended to stop smoking, as well liquid substances it containing, because of its harmful effects to the body organs.

Keywords: Nicotine, Sodium nitrite, Simultaneous administration, Hepatic pathophysiological changes.

1. INTRODUCTION

Nicotine is one of hundreds of substances contained in cigarette smoke (Abdel Aziz HO. 2010). Nevertheless, it is associated with some cases of toxicity especially lungs, hepatic disorders, and may cause congenital defects during pregnancy. In addition, there are risks for the child in the future for type 2 diabetes, obesity, high blood pressure, neurological behavioral defects, respiratory dysfunction and

infertility. Nicotine is a potent stimulant extracted from the family of nightshades (flowering plants) from plant leaves of rainforest called; *Nicotiana rustica*, and a stimulant in nicotine acetylcholine receptors. Chemically, nicotine is a tertiary amine composed of pyridine and pyrrolidine ring, and its structure is [1-methyl-2-(3-pyridyl-pyrrolidine), C₁₀H₁₄N₂]. It is a highly toxic organic compound containing nitrogen and alkaloid which is mostly found in tobacco (Jana, K. *et*

Quick Response Code



Journal homepage:

<http://www.easpublisher.com/easims/>

Article History

Received: 15.03.2019

Accepted: 30.03.2019

Published: 22.04.2019

Copyright @ 2019: This is an open-access article distributed under the terms of the Creative Commons Attribution license which permits unrestricted use, distribution, and reproduction in any medium for non commercial use (NonCommercial, or CC-BY-NC) provided the original author and source are credited.

al., 2010), and responsible for its addiction (Benowitz, N. L. *et al.*, 2009). The use of electronic cigarettes, designed to be re-filled with nicotine-containing electronic liquids, has raised fears of overdoses of nicotine, especially with regard to the possibility of young children taking liquids. The alkaloid nicotine is currently available in various formulations, such as chewing gum, topical patches, and nasal spray to stop the smoking habit (Dani, J. A. *et al.*, 2001). People who smoke and also who are exposed to cigarette smoke indirectly by breathing the air in the same environment are exposed to nicotine induced oxidative stress (Suleyman, H. *et al.*, 2002; Ceyhun, S. B. *et al.*, 2011). The relationship between the amount of products of oxidative metabolism and natural scavengers of free radicals determines the outcome of tissue damage. Overproduction of reactive oxygen metabolites and a reduction in antioxidant mechanisms have been reported due to acute or chronic smoke exposure (Van der Vaart, H. *et al.*, 2004). Oxidative stress would result in increased free radical injury in the tissue leading to extensive tissue damage with subsequent derangement of cell physiology (Rahal, A. *et al.*, 2014). As a consequence, these radicals interact with cell components such as lipids, proteins, DNA, RNA, carbohydrates and enzymes (Ceyhun, S. B. *et al.*, 2011). So that smoking has an effect on the various metabolic and biological processes in the body (O'malley, M. e al 2014).

There are several types of chemical food preservatives, and the most common use are; sodium benzoate, benzoic acid, sulphur dioxide, sodium sorbate, potassium sorbate and sodium nitrite. Nitrite salts are added to meats, poultry, and fish in minute quantities as a means of preservation; this procedure still very common during many decades (Sherif, I. O., & Al-Gayyar, M. M. 2013). Nitrite in meat greatly delays the development of botulinum toxin, develops cured meat flavor and color, retards the development of rancidity during storage, inhibits the development of warmed-over flavor and preserves the flavors of spice (Vaclavik, V. A., & Christian, E. W. 2014). Nitrates and nitrites are precursors in the formation of *N*-nitroso compounds, a class of genotoxic compounds consisting of nitrosamines and nitrosamides (Vaclavik, V. A., & Christian, E. W. 2014). *N*-nitroso compounds are known to cause congenital malformations in animal models, and the role of these compounds in adverse pregnancy outcomes warrants further exploration (Griesenbeck, J. S. *et al.*, 2009). Individuals are exposed to *N*-nitroso compounds from exogenous sources and through endogenous formation. Dietary sources of nitrosamines include cured meats, beer, smoked fish, tobacco smoke and other environmental sources; these stuffs may contain preformed nitrosamines as the result of cooking or preservation methods (Jakszyn, P., & González, C. A. 2006). The addition of NaNO₂ as a food additive, to the food most likely reacts with amines of the foods in the stomach

and produces nitrosamines or large numbers of free radicals. Such products may increase lipid peroxidation which can create many harmful hazards to the different body organs including the liver (Abdeen, A. M. *et al.*, 2015). Sodium nitrite has been reported to have adverse health effects due to increased oxidative stress that could be harmful to different organs including the liver (Sherif, I. O., & Al-Gayyar, M. M. 2013). The reactive nitrogen species that are produced by exposure to nitrite have many toxic effects including hepatotoxicity, nephrotoxicity and dysregulation of inflammatory responses and tissue injury (De, G. S. B. *et al.*, 1983; Hassan, H. A. *et al.*, 2009).

Humans are exposed to chemicals from endogenous or exogenous sources, and they often cause functional failures of certain body systems. Nicotine is one of that chemical can reach to the body from tobacco or from liquid substances. Several studies have been conducted on the harmful effects of nicotine on animal models. Excessive use of preservatives, especially for meat preservation, adversely affects various body systems and causes damage to the body. One of the most common chemical uses is sodium nitrite. The evidence reporting the effects of simultaneous administration of nicotine with sodium nitrite on the liver in male albino rats are hardly found. So, the present study aimed to evaluate the histological and biochemical changes induced by synchronized administration of nicotine and sodium nitrite in the liver of male F-344/NHsd Fischer rats.

2. MATERIALS AND METHODS

2.1 Materials

2.1.1 Animals

24 male F-344/NHsd Fischer rats (14-15 weeks, 200±25gm) were used in this study. Rats were purchased from Animal Welfare House of Libyan National Medical Research Centre, Zawia, Libya. They were housed in plastic cages, 6 rats per cage, and left one week of acclimation, before commencing the experiment. The rats were kept in a room under standard conditions of ventilation, temperature (25 ± 4°C), humidity (65 ± 5 %) with light/dark cycle. The animals were provided with tap water ad libitum and feed with the standard commercial chow. The animal procedures were performed in accordance with Guidelines for Ethical Conduct in the Care and Use of Animals.

2.1.2 Chemicals

Sodium Nitrite (NaNO₂) is white tiny powder dissolves well in water. It used at concentration 0.5% (Ibrahim *et al.*, 2009). Nicotine (C₁₀H₁N₄) is a colorless organic Liquid was determined at a rate of 0.8 mg / kg / day) was injected under the subcutaneous for 45 days (Matta, S. G. *et al.*, 2007). Sodium nitrite and nicotine was purchased from Sigma-Aldrich. Other chemicals were Xylene, formalin 10%, ethanol (absolute alcohol), chloroform, purified water and paraffin wax.

All these chemicals have been obtained from the Chemistry Faculty of Science – Zawia.

2.1.3 Haematoxyline and Eosin Stains:

All chemicals used were for highest quality available. Haematoxyline (H), Eosin (E) stains were purchased from sigma – Aldrich – pure water were produced in this laboratory at good quality of distilled water, pure paraffin wax (melting point 56°C) in laboratory of Sabratha hospital. (H&E) stains of tissues taken from liver and kidney were fixed and embedded in paraffin and 4.5 µm sections were prepared. The sections were stained with H&E using standard procedures for tissues and histopathological assessment. Snapshots of histology were taken using a XSZ-107BN Microscope equipped with camera. Images were generated using an attached MicroKular I camera.

2.2 METHODS:

2.2.1 Dosing of Animals

The animals were left for a week for the purpose of acclimation before starting the experiment. The animals were divided into 4 groups randomly after the weight of all animals and the readings were taken by weight and recorded. Each group consists of 6 rats as follows:

1-group (G1): The control group: the animals were injected daily subcutaneously with saline solution (0.9% Normal saline) at a dose equal to (0.5mg/Kg) for 45 days.

2-group (G2): Nicotine treated group, rats were injected daily subcutaneously at a dose equal to 0.8 mg / kg of nicotine for 45 days.

3- Group (G3): Sodium nitrite treated group, rats were injected daily subcutaneously with a stock solution containing 0.5% of sodium nitrite at a dose equal to 0.5 mg/kg for 45 days.

4- Group (G4): The treated group with both sodium nitrite and nicotine, rats were injected with 0.5mg/kg body weight with sodium nitrite at time 0 hour, an hour later they were re-injected with 0.8 mg/kg body weight nicotine daily for 45 days.

2.2.2 Blood and Liver Samples Collection

After the animals were killed, blood samples were drawn by cardiac puncture and centrifuged at 3000 rpm for 15 minutes to harvest the serum with which the liver functions assessment were analyzed. The liver weight was recorded and the percentage of the liver weight to body weight calculated. Parts from the liver was taken then fixed in 10% formalin.

2.2.3 Tissue Processing

Tissues were freshly collected from the rats. Parts from the liver was taken then fixed in 10% formalin. The tissues were lifted in the fixative not

more than 3 days. Tissues then dehydrated and infiltrated with paraffin wax by processing in Thermo Scientific Shandon Citadel - Automated Tissue processor. The tissues underwent processing in this machine for 15.5 hr with the following stages: 70 % ethanol for 6.5hr then in a increasing series of ethanol 80 %, 90 %, 95 %. Then 3 hrs in 100% ethanol; (an hour in each container of ethanol). The tissues were passed through 3containers of 100% xylene, 1 hr each. The last stage was paraffin wax used for 2 hr which was automatically changed to a different container after 1 hr. Tissue was removed and embedded with paraffin and kept overnight at room temperature. The paraffin blocks were embedded in ice sectioning. The tissues were sliced at thickness of 4.5 µm and collected on slides. Then slides are ready to under going to H&E Staining. H & E staining was performed for liver tissues to study the histopathological changes under light microscope.

2.3. Measurement of Serum Biochemical Parameters

The serum activities of ALT, AST were measured according to the methods described by Reitman and Frankel, (1957). Serum ALP activity was determined according to Kind *et al.*, (1980). Serum direct bilirubin levels was determined according to the methods described by Dangerfield and Finlayson (1953).

Serum total proteins concentration was determined according to Biuret method explained by Weichselbaum, (1946). Serum albumin concentration was determined according the method of Doumas *et al.*, (1971). Serum globulin concentration was determined according to the formula: Globulin = total protein – albumin.

Serum glucose was determined using Trinder method (1969). Total cholesterol concentration was estimated according to Allain *et al.*, (1974), triglycerides concentration also by the method of Fossati and Prencipe, (1982).

2.4 Statistical Analysis

All data is represented as mean ± standard deviation. Statistical significance was tested by Dunnett's Multiple Comparison Test with a one and two ways analysis of variance (ANOVA) was used for multiple comparisons. This was done with GraphPad prism 7.0 software. : All date analyzed using Graph-pad Prism software, the results means ± standard deviation (M ± SD) used (multiple Duncan taking into account the value (P <0.05), which is considered statistically signified.

3. Results

Treatment of rats with sodium nitrite or nicotine caused a significant (P<0.01) increase in serum Alanine Aminotransferase (ALT), Aspartate Aminotransferase (AST), and Alkaline Phosphates (ALP) activities compared with the control group.

Simultaneous administration of sodium nitrite and nicotine caused additive significantly ($P < 0.01$) increase

in serum ALT, AST, and ALP activities compared to control group (Table.1 & Figure.1).

Table1. Effect of sodium nitrite and/or nicotine on some serum biochemical parameters in different male Wistar albino rats groups

Parameters	Groups			
	Control	Sodium Nitrite	Nicotine	Nicotine + Sodium Nitrite
	Mean + SD	Mean + SD	Mean + SD	Mean + SD
Alanine aminotransferase (U/L)	79.00±1.6	173.83±7.7**	137.16±8.9**	124.66±2.07**
Aspartate aminotransferase (U/L)	96.83±8.4	194.16±3.8**	171.66±5.6**	147.66±2.4**
Alkaline phosphatase (U/L)	86.50±1.01	120.50±2.0**	100.1±6.3**	109±2.9**
Total proteins concentration (g/dl)	5.88±0.24	4.96±0.46**	5.03±0.51**	4.16±0.52**
Globulin concentration (g/dl)	3.48±0.65	2.46±0.36**	1.89±0.20**	1.78±0.20**
Albumin concentration (g/dl)	2.69±0.23	3.45±0.13**	3.96±0.23**	4.24±0.5**
Glucose concentration (mg/dl)	112.16±9.74	184.83±2.8**	171.66±9.8**	188.83±2.7**
Cholesterol concentration (mg/dl)	69.17±7.6	87.50±4.5**	84.16±6.28	93.83±1.2**
Triglyceride concentration (mg/dl)	81.16±4.26	158.00±6.5**	141.00±3.4**	149.17±8.6**

All data are mean of 6 individuals. **: Significant differences as compared with control group ($P < 0.01$).

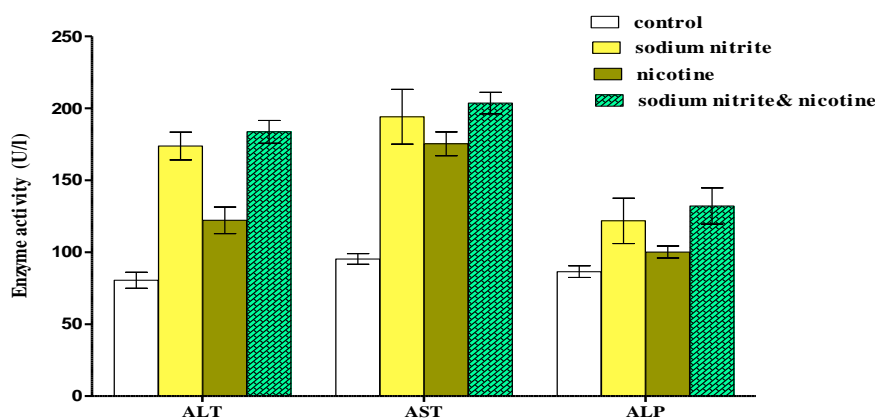


Fig.1. Effect of sodium nitrite and/or nicotine on serum LT, AST, and ALP activities in different groups

Serum concentrations of total protein and globulin were significantly ($P < 0.01$) decreased and serum albumin concentration was significantly ($P < 0.01$) increased in rats treated with sodium nitrite or nicotine compared with control group. Simultaneous administration of sodium nitrite and nicotine caused

additive significantly ($P < 0.01$) decrease in serum concentrations of total protein and globulin and a more significantly ($P < 0.01$) increase in serum albumin compared to control group as shown in table.1 & figure.2.

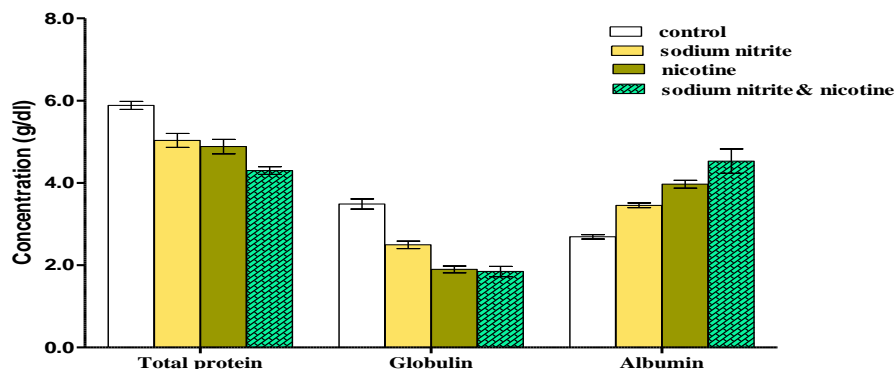


Fig.2 Effect of sodium nitrite and/or nicotine on serum concentrations of Total proteins, globulin, and albumin in different group

Animals treated with sodium nitrite or nicotine showed a significant ($P < 0.01$) increase in serum glucose, cholesterol and triglyceride concentrations compared with control group. Simultaneous

administration of sodium nitrite and nicotine caused additive significantly ($P < 0.01$) increase in serum glucose, cholesterol, and triglyceride concentrations compared with control group (Table.1& Figure.3).

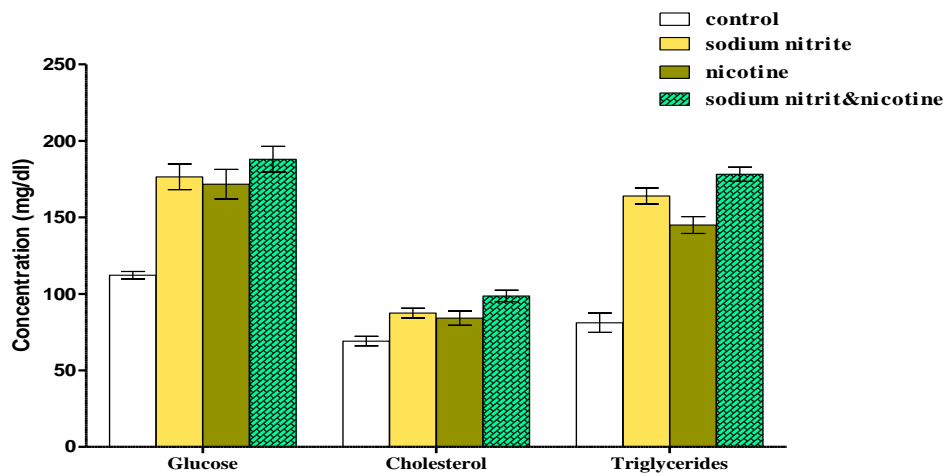


Fig.3 Effect of sodium nitrite and/or nicotine on serum concentration of glucose, Cholesterol and triglycerides in different groups

The liver sections of control group are showing a normal central vein, and lining endothelial, no bleeding observed, normal hepatocytes radiating arrangement from central vein and blood sinusoids appear between the hepatocytes. Hepatocytes are granular and acidophilic cytoplasm, normal arrangement of hepatic cords, normal sinusoids between the hepatocytes and containing normal number of

kupffer cells. In portal area, a typical portal canal contains branches of portal vein, hepatic artery and bile duct, the triad is clearly bordered by the surrounding normal hepatocytes and interlobular septa. Normal structure of functional metabolic zones between central vein and portal tract, zone, normal hepatic sinusoids connecting the zones (Figure. 4).

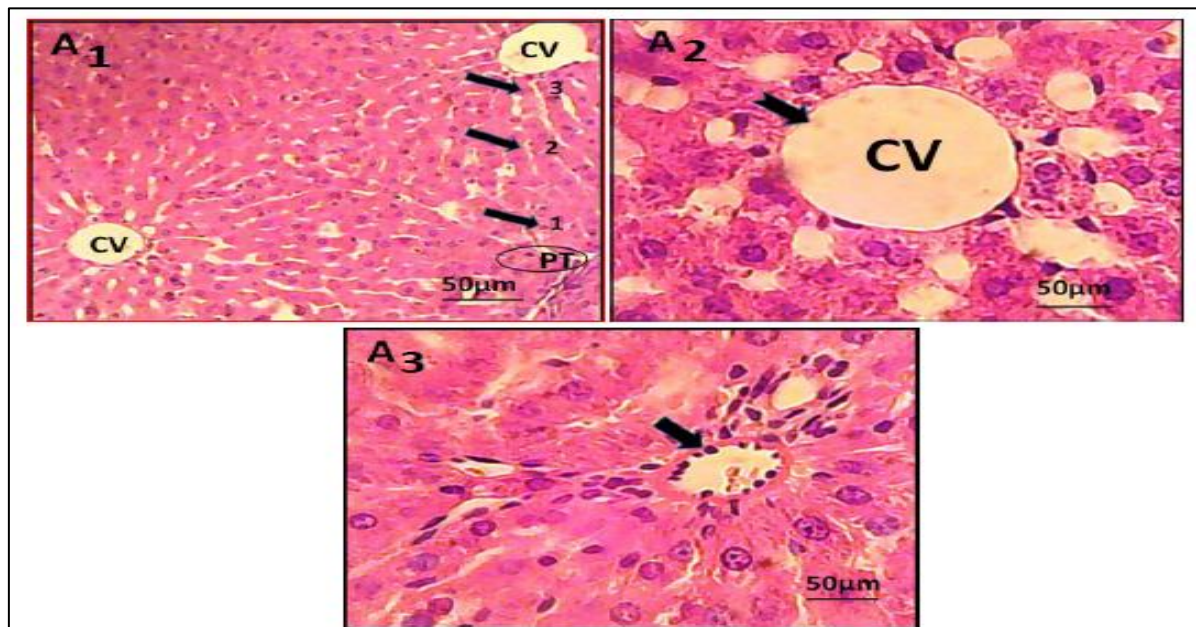


Fig.4: Light micrograph of sections in the liver of control albino rats showing.

A1: Normal structure of functional metabolic zones between central vein (CV) and portal tract (PT), zone 1 (periportal zone), zone 2 (middle zone) and zone 3 (perivenous zone), normal hepatic sinusoids connecting the zones (H&E x 400). **A2:** Normal rounded central vein (black arrow), normal lining endothelial, no bleeding observed, normal hepatocytes radiating arrangement from central vein and blood sinusoids appear between the hepatocytes. Hepatocytes are granular and acidophilic cytoplasm, normal arrangement of hepatic cords, normal sinusoids between the hepatocytes and containing normal number of kupffer cells (H&E x 1000). **A3:** A typical portal canal contain branches of portal vein, hepatic artery and bile duct; the triad is clearly bordered by the surrounding normal hepatocytes and interlobular septa (black arrow) (H&E x 1000).

The liver sections in sodium nitrite treated group show a mild congested central vein, damage in lining endothelium, leukocytic infiltration and inflammatory cells around portal blood vessels,

dilation of blood sinusoids in zone2, 3, hepatocytes appear with vacuoles in cytoplasm, disorganized, and focal necrosis associated with inflammatory cells (Figure. 5).

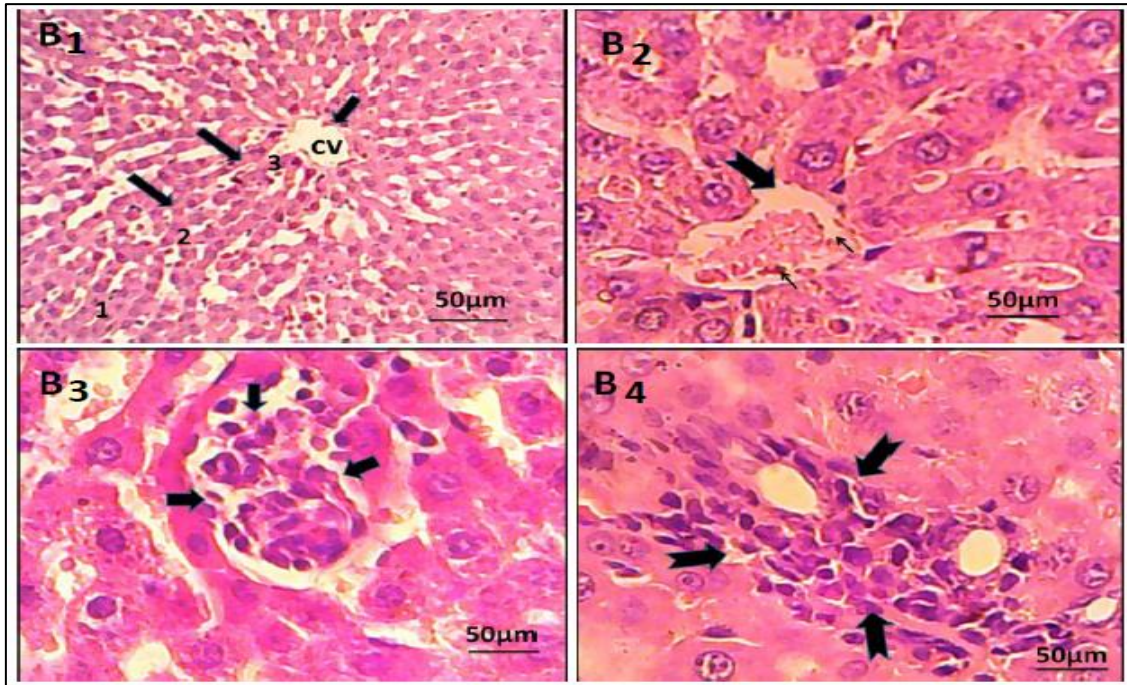


Figure.5: Light micrograph of sections in the liver of albino rats treated with sodium nitrite showing:

B1; Dilatation of blood sinusoids in zone2, 3 (black arrow) and injury in CV(head arrow) (H&E x 400)..B2; Congested central vein (black arrow) and damage in lining endothelium (H&E x 1000).. B3; Hepatocytes appear with vacuoles in cytoplasm, disorganized, cellular infiltrate and focal necrosis associated with inflammatory cells (H&E x 1000).. B4; Infiltration and inflammatory cells around portal blood vessels (small arrow) (H&E x 1000).

The liver sections of nicotine treated group shows a marked injury in central vein with hemorrhage, a marked congestion of portal triad, congestion of blood sinusoids in the 3 zones of acinus, degeneration disorder of hepatocytes especially zone 3 and adjacent area , and congestion with RBC's between hepatocytes (Figure. 6).

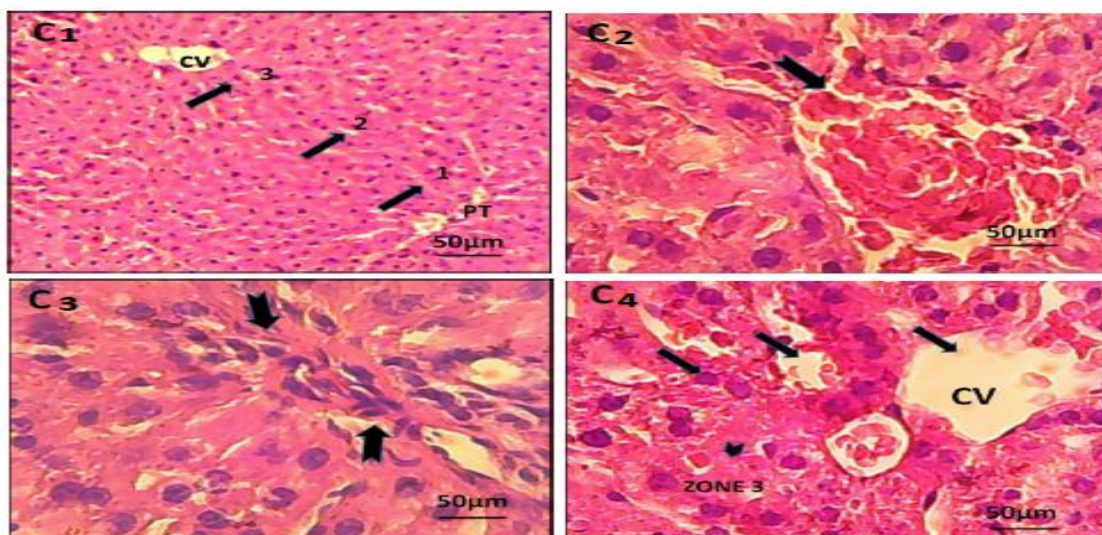


Figure.6: Light micrograph of sections in the liver of albino rats treated with nicotine showing

C1; Congestion of the blood sinusoids in the 3 zones of acinus (black arrow) (H&E x 400). C2; A marked injury in central vein with hemorrhage (black arrow). C3; A marked congestion of portal triad (small arrow) (H&E x 1000). C4; section from treated group (nicotine) shows degeneration disorder of hepatocytes especially zone 3 and adjacent area ,congestion with RBC's between hepatocytes (H&E x 1000).

The liver sections of rats treated with sodium nitrite and nicotine show sever histopathological change in central vein area such bleeding, damage in lining endothelium, congestion in sinusoids around central vein, disturbance of hepatic lobules, aggregation of inflammatory cells around portal triad, congestion in portal blood vessels, fibrosis of portal tract and distraction in hepatocytes surround portal tract. A

marked injury in central vein, focal hepatic necrosis associated with inflammatory cells, and congestion in periportal zone. Also, there are pyknosis, Karyorrhesis and karyolsis, apoptotic hepatocytes, prominent of kupffer cells, and vacuolar degeneration along with apoptosis, focal necrosis and inflammation characterized by a focal group of contiguous cells with cells swelling and loss cellular detail (Figure.7&8).

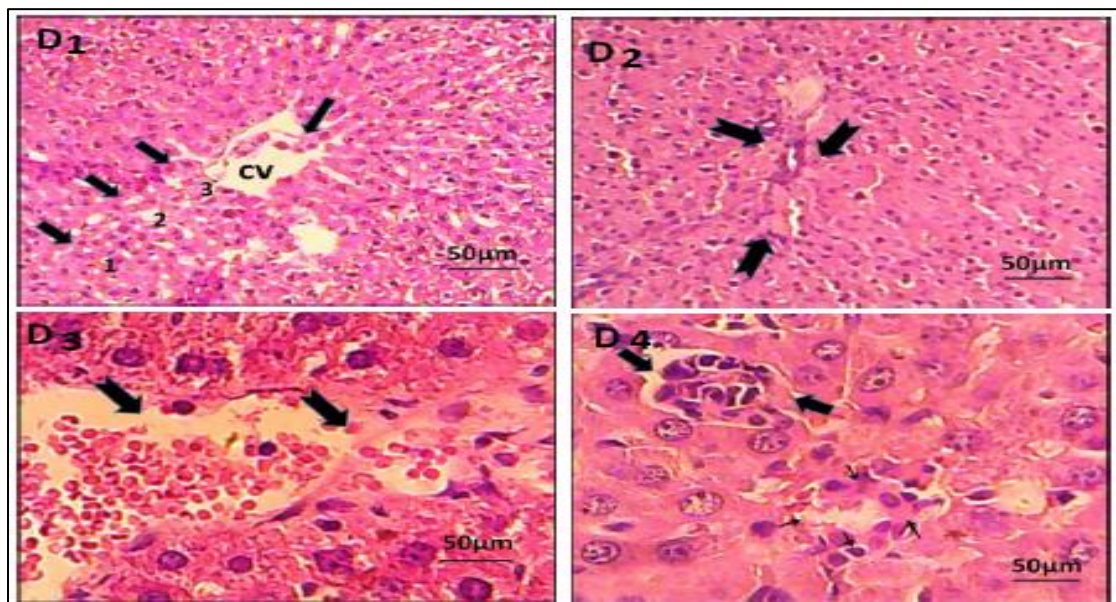


Figure.7: Light micrograph of sections in the liver of albino rats treated with sodium nitrite and nicotine showing
D01: A marked injury in CV and perivenous zone (black arrow), hepatic necrosis associated with inflammatory cells (head arrow) and congestion in periportal zone (H&E x 400). **D02:** Aggregation of inflammatory cell around portal triad, acute congestion in portal blood vessels, fibrosis of portal tract and distraction in hepatocytes surround portal tract (small arrow) (H&E x 400). **D03&04:** sever histopathological change in central vein area (CV) such bleeding, damage in lining endothelium (black arrow), cognation in sinusoids around CV, destruction in hepatocytes and leukocytic infiltration (H&E x 1000).

4. DISCUSSION

Liver is a principle organ of detoxification and the major site of intense metabolism in generally, thus undergoing to various disorders because of exposure to the toxins (RasGele, P., & KaymaK, F. 2013). Serum aminotransferase activities are known as toxicity markers in the hepatotoxicity studies caused by chemicals and an increase in the activities of these enzymes is termed as the early recognition of toxic hepatitis (AL-Shinnawy, M. S. 2009).

The current study has emphasized that treatment of male albino rats with sodium nitrite had a negative effect on activities of the serum Alanine aminotransferase, Aspartate aminotransferase, and alkaline phosphates, and concentrations of serum total proteins, goblin, albumin, glucose, cholesterol, and triglyceride compared with the control group. The current study showed that an increase in liver enzymes

activities (AST, ALT& ALP) in male albino rats treated with.

Sodium nitrite, which a consistent with a previous study carried out by Sherif in (2013). As well as the activities of the ALT, AST, and ALP enzymes were increased in rats treated with NaNO₂ for a period of three months (Hassan, H. A. *et al.*, 2009). The increment in the activities of ALT, AST and ALP in the serum of treated group by sodium nitrite could be attributed to oxidative stress and resulting damage to cell membrane of liver tissue (Salama, M. F. *et al.*, 2009). It became known that, an elevation of serum liver enzymes is causing hepatocellular injury ultimately (Kim, W. R. *et al.*, 2008). Furthermore, there are other factors related with elevation of liver enzymes such as alteration in permeability of cell membrane, increasing the synthesis of the enzyme or decreasing the rate of degradation of the enzyme.

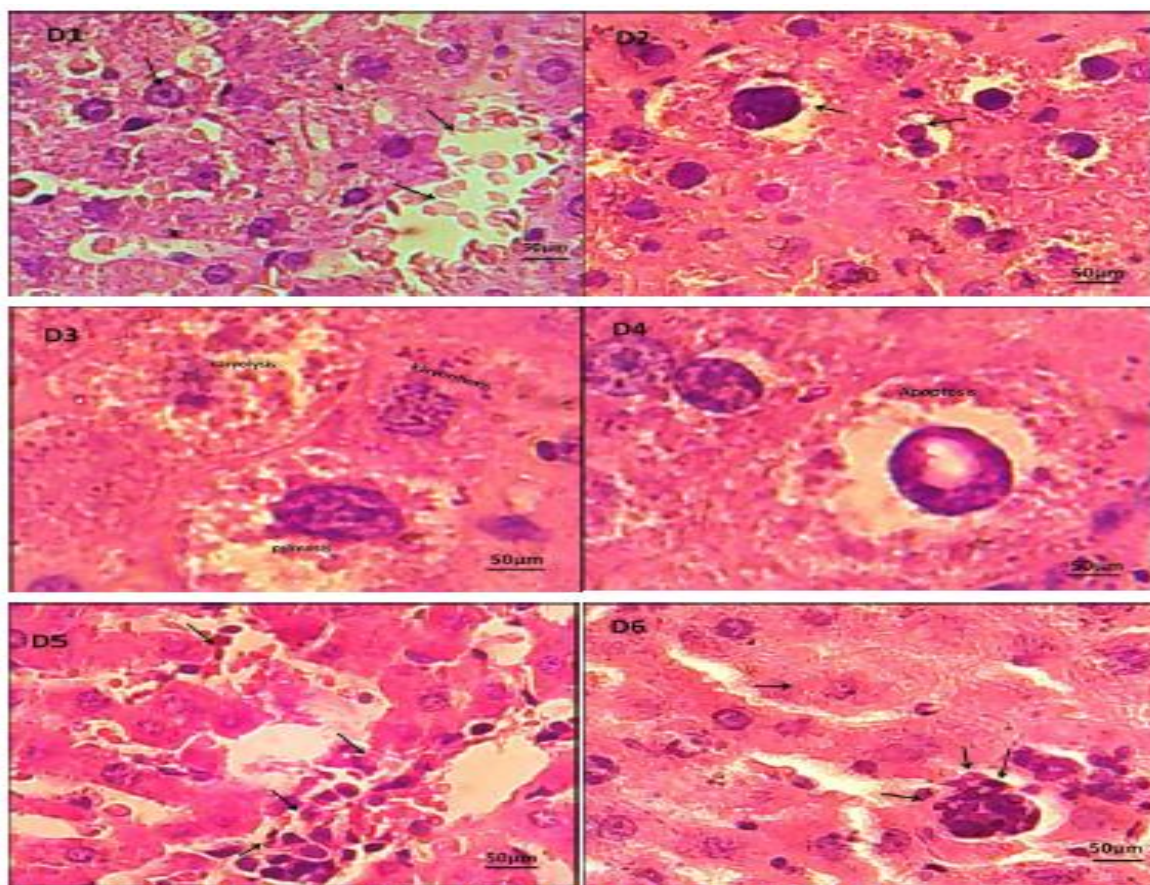


Fig.8: Light micrograph of sections in the liver of albino rats treated with sodium nitrite and nicotine showing focal necrosis with inflammatory cells.

D1; Distraction in hepatocytes, disturbance of hepatic lobules and RBC's in blood sinusoids and vessels (H&E x 400). **D2;** Apoptosis in the liver characterized by scattered single (H&E x 400). **D3;** A single cell necrosis, there are pyknosis, Karyorrhexis and karyolysis(H&E x 1000).. **D4;** Apoptotic hepatocytes (H&E x 1000).. **D5;** Aggregation of inflammatory cells, prominent of kupffer cells and vacuolar degeneration along with apoptosis (H&E x 400). **D6** Focal necrosis and inflammation characterized by a focal group of contiguous cells with cells swelling and loss cellular detail(D2, D4);example of apoptosis in the liver characterized by scattered single (H&E x 400).

The present work has established that administration of sodium nitrite caused a significant decrease in serum total protein and globulin. This reduction may be due to substantially of protein synthesis by the liver and an alteration in the intracellular protein synthesis mechanism, with noted that the oxidative enzyme change were probably secondary in altering proteins, this finding is consistent with two studies, where they are found significantly decreased in serum total protein level in treated rats with sodium nitrite (Helal, E. *et al.*, 2008). Another study suggested that a stimulation of the thyroid and adrenal glands by sodium nitrite can lead to a blockade in protein synthesis, fast breakdown, increased rate of free amino acids and decreased protein turnover (Eremin, I., & Tocharina, M. G. 1981). In addition, nitrite interactions result into nitric oxide release, which can inhibit total protein synthesis. In contrast our finding has shown an increase in serum albumin.

Several previous studies have proved that liver has storage role for glucose and preserves the natural levels of triglyceride and cholesterol. Above described data has displayed an imbalance in the enzymes and

hepatic proteins, also glucose levels in the blood were to be ascertained. The current study is confirmed that sodium nitrite caused a significant increase in levels of glucose, triglyceride and cholesterol. These results are in accordance with Hasan *et al.*, (2011) who found that there was a significant increase in serum glucose concentration, while he found a decrease in liver glycogen content of NaNO₂-treated rats. It was reported that, nitrite stimulates gluconeogenesis and glucose shift from tissue to blood or an impairment of glucose mobilization. Thus, nitroso-compounds can alter the antioxidant system causing disorder in the metabolic processes leading to hyperglycemia in the blood (Rahal, A. *et al.*, 2014; Hassan, H. A. *et al.*, 2009; and Wiechetek, M. *et al.*, 1993).

Hepatocytes occupy around 80% of total liver and perform much function including detoxification making it more susceptible to injury. Histological results in the liver of treated rats have revealed congestion in central vein and damage in lining endothelium, and inflammatory cells with infiltration in portal triad and dilatation in blood sinusoids. The most histological change in hepatocytes was vacuolar

degeneration in the cytoplasm, disorganized and focal necrosis. The dilation of blood sinusoids has been detected which can be attributed to the radial orientation of hepatic cords was lost. The current study consistent with Klatskin and Conn (1993), Galaly and Mahmoud (2012) who they are found that sodium nitrite causes separation of inner and outer membranes, and dilated in blood sinusoids.

In the present work, the focal necrosis and congestion occurred between central vein and portal zone in conditions of deficiency oxygen supply in liver cells and oxidative stress, whereas hepatocytes in this zone are more sensitive to anoxia which led to its injury and damage. On the other hand, some studies confirmed in other conditions have raised that injury with necrosis in mid-zone of the manifestation of low flow hypoxia (Zaidi, Z. F. 2010). All above histopathological changes those a resulting of sodium nitrite induction is infect reflecting the apoptotic, necrosis features, degeneration in epithelium lining CV and hepatocytes, further confirming usually DNA fragmentation formed. In addition, lipid peroxidation induced by the free radical of sodium nitrite combine with DNA to form adducts and accelerates DNA fragmentation (Kohn, M. C. *et al.*, 2002).

Although metabolism occurs to some extent in the kidney and lungs, liver is considered the major organ for nicotine metabolism. Nicotine is extensively metabolized to a number of metabolites by the liver. In humans, about 70 to 80% of nicotine is converted to cotinine (Benowitz, N. L., & Jacob III, P. 1994). This study has shown hepatomegaly, increased in liver enzymes, glucose and fat deposition with deficiency in liver proteins. These finding can be interpreted to suspicion of some degree of toxicity. With other words, this suggesting the possibility of cellular damage by nicotine which leads to accumulation of glucose and lipids in the hepatic cells, so the histological section revealed liver injury and hence an increase in liver weight (Iranloye, B., & Bolarinwa, A. 2009). It is worth to indicate that; the cytochrome P450 is mediated metabolic pathway for nicotine metabolism was recently reported by Hecht *et al.*, (1999).

Liver function test became the most important methods used to check the liver's safety from toxicity at the recent decades. Liver performance indices such as ALT, AST, and ALP are widely used to evaluate the liver injury. Necrosis or cell membrane damage can trigger the release of these enzymes into the blood circulation (Drotman, R. B., & Lawhorn, G. T. 1978). The nicotine has caused increases in serum aminotransferase enzymes (ALT, AST, and ALP) activities in the treated group of male rats injected with 0.8 mg/kg body weight for 45 days. This finding was supported by previous results of a study carried out by Jalili in (2015). Nicotine can induce the production of free radicals and consequently oxidative stress, which is

one of the most important causes of liver cells damage (Sánchez-Moreno, C. *et al.*, 1999). It seems that the increased level of serum enzymes indicate cellular leakage, structural damage, and performance dysfunction of membrane markers in the liver due to nicotine administration (Jalili, C. *et al.*, 2015). Nicotine can also cause lipid peroxidation by affecting the membrane of hepatocytes, which, in turn, causes a change in membrane permeability and lipid degeneration and accumulation in the liver cells. Free radicals seem to change the enzymatic activity and necrosis by attacking poly-unsaturated fatty acids and alkylating groups of proteins and other cellular macromolecules (Khorsandi, L. *et al.*, 2006). The results obtained in this study confirm the finding of Balakrishnan and Menon, indicated that nicotine administration can significantly increase marker enzymes in liver (Balakrishnan, A., & Menon, V. P. 2007). Our results also indicated that an inhibitory effect of nicotine on the biosynthesis of total protein and globulin. On the other hand there was increase in albumin level. It was demonstrated that the liver is the sole source for the synthesis of total protein, albumin and most of α & β globulins, while the immunoglobulin is formed in the lymphoid tissues by the plasma cell (Mohamed, T. *et al.*, 1992). Thus, the liver affected by nicotine caused dysfunctions and modify the synthesis and metabolism of all these proteins. This explains the significant decrease in total protein and globulin. This was in agreement with the results of Sershen *et al.*, (1982) and Villablanca (1998).

The present results indicated that nicotine causes increase in serum glucose, cholesterol and triglycerides concentrations. The results obtained are coinciding with EL- Safy, (1994), Khairia, B. L. (2009). Similar study on the effect of nicotine administration on carbohydrate metabolism of albino rats has demonstrated same finding (Sershen, H. *et al.*, 1982; Sharif, S. *et al.*, 2014).

Interestingly, nicotine impairs glucose tolerance and alters serum levels of hormones involved in glucose metabolism, but the role of nicotine in such hormonal alterations are not well understood. Some researchers have concluded that nicotine may lead to mild hyperglycemia and lowered insulin sensitivity (Morgan, T. M. *et al.*, 1951).

It is known that, liver is the main regulating organ by which the synthesis, esterification, degradation and excretion of cholesterol take place in the body triglycerides. Therefore, any dysfunction in liver cells affects on these regulation process.

The histological examination of liver tissues have shown toxic effect, which seen in the structural appearance changes of all tissues of liver and its units in treated rats. Our results have emerged as injury in CV, congestion in portal triad and zones of acinus with

inflammatory cells and degeneration disorder of hepatocytes. Liver disorders can be occurred as a result of oxidative stress, exposure to nicotine produces oxidative tissue injuries in the rodents. The current study and Gawish's work in 2012 have found same results of nicotine on liver tissues (Gawish, A. M. *et al.*, 2012). Oxidative stress by nicotine occurs when there are excess free radicals or low antioxidant defense, and result in chemical alteration of biomolecules causing structural and functional modification (Neogy, S. *et al.*, 2008). Hence, logically there is association between nicotine and liver cell inflammation & activation of Kupffer cells which may be attributed to pro-inflammatory cytokines (El-Zayadi, A.R. 2006).

The following issue was addressed; exposure to two or more xenobiotics as simultaneously can take place in the environment or under occupational conditions. The investigation of interactions between toxic substances is an important problem currently. In terms of the simultaneous effect of sodium nitrite and nicotine on liver through biochemical analysis and histopathological study, the present results showed a significant increase in serum aminotransferase enzymes (ALT, AST, and ALP) activities compared with the effects of sodium nitrite or nicotine treated groups. The observed elevations in serum AST & ALT activity may reflect severe hepatotoxicity and chronic injury in liver cell. Other authors also reported about the effect of exposure two chemicals simultaneously (Tandon, S., & Tewari, P. 1987; Gupta, V., & Gill, K. D. 2000). our results were consistent with others; they were found increase in serum aminotransferase activities, following cadmium and ethanol administration in animals receiving simultaneously develop where statistically significant difference between the treated and control groups. In addition there was a significant decrease in serum protein and globulin which can interpreter into harmful effect of sodium nitrite and nicotine, reflects on the biosynthesis of protein (Eremin, I., & Tocharina, M. G. 1981). They found that serum proteins of rats are decreased due to the stimulatory effect of the nitrite on the thyroid and adrenal glands that leads to block of protein synthesis while fast breakdown occurs. This leads to an increase of free amino acids and to a decrease of protein turnover. Similar changes have been demonstrated by other authors (Helal, E. *et al.*, 2008; Yanni, M. *et al.*, 1991). Also, administration of both sodium Nitrite and sun set yellow for one month to rats induced a decrease of serum total protein and globulin. In contrast; the albumin was high level between simultaneous groups comparing with all groups. They recommended that even the permitted doses of colorants and food preservatives may be harmful (Helal, E. G. 2001). Nevertheless; others have found difference in albumin level, between control and treated rats according to ages and time of taking samples at day time or night, also whether rats fasting or not (Peters, T., & Peters, J. C. 1972). In contrast, current study has demonstrated level of albumin been increased.

Triglycerides are store excess energy from diet, combined with cholesterol. Cholesterol is linked with fatty buildup within the artery walls, which increases the risk of diseases. Current study has showed significant increase in cholesterol, triglyceride and serum glucose as a result of effect a chronic administration of sodium nitrite and nicotine. May be due to its high their interaction as oxidative stress reasons and production of free radicals that leading to liver damage. Helal's (2001) study in 2001; was used two agents sodium nitrate and selenium 10 mg/kg and 50 mg/kg/day, administered orally respectively. After a month of treatment she found that serum cholesterol was a significant increased ($P < 0.01$), this finding goes with the result of current study.

The histological examination alongside with functional tests show that sodium nitrite and nicotine when administered simultaneously, led to injury of liver in different zones. Our results revealed many liver injury indications; bleeding, damage in lining endothelium of central vein, cognation in hepatic sinusoids, distraction in hepatocytes surround portal tract, and hepatic necrosis associated with inflammatory cells, focal necrosis and inflammation characterized by a focal group of contiguous cells with cells swelling and loss cellular detail. Interestingly, three phases of necrosis were detected nuclear pyknosis, Karyorrhexis and karyolysis for hepatocytes. The liver is undergoing to injury by a variety of causes and its injury may lead to profound metabolic disorders. Liver injury induced by chemicals has been recognized as one of the most toxicological problems (Kaplowitz, N. 2000). In the present study, nicotine and sodium nitrite have caused a marked injury to the liver where sinusoidal congestion formed then developed as an irregular radial direction of the hepatic cords and lost ultimately. Hepatocellular necrosis is probably due to attach of a cell membrane by the hepatotoxin or interaction with some specific components of the metabolic pathways leading to the alteration of their structure and function (Crăciun, C., & Rusu, M. 1980). In addition, the hepatocytes response to toxic lesion was also reflected by irregular shape of nuclei and nuclear condensation. Similar results were established in rats by Crăciun and Rusu, (1980) and Gordienko and Didenko, (1977), It is known that using of animal models mimic human health problems is very common method use at last decades. Current study was conducted to mimics some human health aspects. It's become known that a majority of drugs administered in humans are eliminated by a combination of hepatic metabolism and renal excretion.

5. CONCLUSION

It can be concluded that treatment of rats with nicotine or sodium nitrite caused a serious pathophysiological changes in the liver. Simultaneous administration of nicotine and sodium nitrite caused a more pathophysiological change in the liver. Therefore,

we should reduce the use of preservatives, frozen meat and other recommended to stop smoking, as well liquid substances it containing, because of its harmful effects to the liver and other body organs. Also, it would be beneficial to further more studies by administration of two other chemicals simultaneously and examining harmful effects on other body systems such as reproductive, digestive system and lungs. As well as administrate for different time courses at different doses.

REFERENCES

1. Abdel Aziz HO. (2010). Morphological evaluation on the protective effect of curcumin on nicotine induced histological changes of the adrenal cortex in mice. *Egypt. J. Histol*, 33(3), 552-559.
2. Jana, K., Samanta, P.K., & De, D.K. (2010). Nicotine diminishes testicular gametogenesis, steroidogenesis, and steroidogenic acute regulatory protein expression in adult albino rats: Possible influence on pituitary gonadotropins and alteration of testicular antioxidant status. *Toxicol. Sci*, 116(2), 647-659.
3. Benowitz, N. L., Hukkanen, J. & Jacob, P. (2009). Nicotine chemistry, metabolism, kinetics and biomarkers. *Nicotine psychopharmacology*, Springer, 29-60.
4. Dani, J. A., Ji, D., & Zhou, F. M. (2001). Synaptic plasticity and nicotine addiction. *Neuron*, 31(3), 349-352.
5. Suleyman, H., Gumustekin, K., Taysi, S., Keles, S., Oztasan, N., Aktas, O., ... & Dane, S. (2002). Beneficial effects of Hippophae rhamnoides L. on nicotine induced oxidative stress in rat blood compared with vitamin E. *Biological and Pharmaceutical Bulletin*, 25(9), 1133-1136.
6. Ceyhun, S. B., Şentürk, M., Yerlikaya, E., Erdoğan, O., Küfrevioğlu, Ö. İ., & Ekinci, D. (2011). Purification and characterization of carbonic anhydrase from the teleost fish *Dicentrarchus labrax* (European seabass) liver and toxicological effects of metals on enzyme activity. *environmental toxicology and pharmacology*, 32(1), 69-74.
7. Van der Vaart, H., Postma, D. S., Timens, W., & Ten Hacken, N. H. T. (2004). Acute effects of cigarette smoke on inflammation and oxidative stress: a review. *Thorax*, 59(8), 713-721.
8. Rahal, A., Kumar, A., Singh, V., Yadav, B., Tiwari, R., Chakraborty, S., & Dhama, K. (2014). Oxidative stress, prooxidants, and antioxidants: the interplay. *BioMed research international*, 2014.
9. [O'malley, M., King, A. N., Conte, M., Ellingrod, V. L., & Ramnath, N. (2014). Effects of cigarette smoking on metabolism and effectiveness of systemic therapy for lung cancer. *Journal of Thoracic Oncology*, 9(7), 917-926.
10. Sherif, I. O., & Al-Gayyar, M. M. (2013). Antioxidant, anti-inflammatory and hepatoprotective effects of silymarin on hepatic dysfunction induced by sodium nitrite. *European cytokine network*, 24(3), 114-121.
11. Vaclavik, V. A., & Christian, E. W. (2014). Food Preservation. *Essentials of food science*, Springer, 323-342.
12. Griesenbeck, J. S., Steck, M. D., Huber, J. C., Sharkey, J. R., Rene, A. A., & Brender, J. D. (2009). Development of estimates of dietary nitrates, nitrites, and nitrosamines for use with the Short Willet Food Frequency Questionnaire. *Nutrition journal*, 8(1), 16.
13. Jakszyn, P., & González, C. A. (2006). Nitrosamine and related food intake and gastric and oesophageal cancer risk: a systematic review of the epidemiological evidence. *World journal of gastroenterology: WJG*, 12(27), 4296.
14. Abdeen, A. M., EL-Shayeb, A. F., Hassan, H. A., & El-Agamy, S. A. (2015). The protective role of garlic oil against the histopathological and histochemical changes induced by sodium nitrite toxicity in kidneys of albino rats. *J Jazan Univ Appl Sci Branch*, 4, 57-67.
15. De, G. S. B., Fritsch, P., & Cazottes, C. (1983). Effects of dietary nitrite and nitrate on experimentally-induced inflammation in the rat. *International journal of tissue reactions*, 5(2), 173-180.
16. Hassan, H. A., El-Agmy, S. M., Gaur, R. L., Fernando, A., Raj, M. H., & Ouhtit, A. (2009). In vivo evidence of hepato-and reno-protective effect of garlic oil against sodium nitrite-induced oxidative stress. *International journal of biological sciences*, 5(3), 249.
17. Matta, S. G., Balfour, D. J., Benowitz, N. L., Boyd, R. T., Buccafusco, J. J., Caggiula, A. R., ... & Gardiner, P. S. (2007). Guidelines on nicotine dose selection for in vivo research. *Psychopharmacology*, 190(3), 269-319.
18. Reitman, S., & Frankel, A. (1957). Colorimetric method for determination of serum glutamate oxaloacetate and glutamic pyruvate transaminase. *Amer J Clin Pathol*, 28, 56-58
19. Kind, P.R.N., King, E.J., Varley, H., Gowenlock, A.H., & Bell, M. (1980). *Method of practical clinical biochemistry*. Heinman, London, 899-900.
20. Dangerfield, W. G., & Finlayson, R. (1953). Estimation of bilirubin in serum. *Journal of Clinical Pathology*, 6(3), 173.
21. Weichselbaum, T.E. (1946). Determination of total protein. *Amer. Clin. Path*, 16, 40-48.
22. Doumas, B.T., Watson, W.A., & Homer, C.B. (1971). Albumin standard and measurement of the albumin with bromocresol green. *Clin Chem Acta*, 31, 87-96.
23. Trinder, P. (1969). Glucose GOD-PAP method enzymatic colorimetric method. *Ann Clin Biochem*, 6, 24.
24. Allain, C. C., Poon, L. S., Chan, C. S., Richmond, W. F. P. C., & Fu, P. C. (1974). Enzymatic

- determination of total serum cholesterol. *Clinical chemistry*, 20(4), 470-475.
25. Fosstoti, P., & Prencipe, L. (1982). Serum triglycerides determination calorimetrically with an enzyme that produces hydrogen peroxide. *Clin Chem*, 28(10), 2077 - 2080.
 26. RasGele, P., & KaymaK, F. (2013). "EffEcts of food PrEsErvativE NatamyciN oN LivEr ENzymEs aNd totaL ProtEiN iN Mus Musculus." *Bulgarian Journal of Agricultural Science*, 19(2), 298-302.
 27. AL-Shinnawy, M. S. (2009). "Physiological effect of a food additive on some haematological and biochemical parameters of male albino rats." *Egypt. Acad. J. Biol. Sci*, 2(1), 143-151.
 28. Salama, M. F., Abbas, A., Darweish, M. M., El-Hawwary, A. A., & Al-Gayyar, M. M. (2013). Hepatoprotective effects of cod liver oil against sodium nitrite toxicity in rats. *Pharmaceutical biology*, 51(11), 1435-1443.
 29. Kim, W. R., Flamm, S. L., Di Bisceglie, A. M., & Bodenheimer, H. C. (2008). Serum activity of alanine aminotransferase (ALT) as an indicator of health and disease. *Hepatology*, 47(4), 1363-1370.
 30. Helal, E., Zahkok, S., Soliman, G. Z., Al-Kassas, M., & Abdel Wahed, H. (2008). Biochemical Studies On The Effect Of Sodium Nitrite And/Or Glutathione Treatment On Male Rats. *Egyptian Journal of Hospital Medicine*, 30.
 31. Eremin, I., & Tocharina, M. G. (1981). Effect of nitrites on the state of thyroid gland in iodine deficiency and different diets. *Voprosy pitaniia*, (5), 60.
 32. Wiechetek, M., Garwacki, S., Karlik, W., Lewicki, J., & Souffrant, W. (1993). Effect of nitrite on ureagenesis and carbohydrate metabolism in isolated rat hepatocytes. *Archives of environmental contamination and toxicology*, 24(3), 375-380.
 33. Klatskin, G., & Conn, H. O. (1993). *Histopathology of the liver*, Oxford University Press.
 34. Galaly, S.R., & Mahmoud, M.S. (2012). The protective effect of vitamin A against sodium nitrate induced toxicity in liver and kidney of albino rats: histological and ultrastructural study. *J Am Sci*, 8(12), 293-308.
 35. Zaidi, Z. F. (2010). "Periportal necrosis in rat liver exposed to sodium nitrite-induced hypoxia." *Research Journal of Animal and Veterinary Sciences*, 5(2), 111-116.
 36. Kohn, M. C., Melnick, R. L., Ye, F., & Portier, C. J. (2002). Pharmacokinetics of sodium nitrite-induced methemoglobinemia in the rat. *Drug Metabolism and Disposition*, 30(6), 676-683.
 37. Benowitz, N. L., & Jacob III, P. (1994). Metabolism of nicotine to cotinine studied by a dual stable isotope method. *Clinical Pharmacology & Therapeutics*, 56(5), 483-493.
 38. Iranloye, B., & Bolarinwa, A. (2009). "Effect of nicotine administration on weight and histology of some vital visceral organs in female albino rats." *Nigerian Journal of Physiological Sciences* 24(1).
 39. Hecht, S. S., Carmella, S. G., & Murphy, S. E. (1999). Effects of watercress consumption on urinary metabolites of nicotine in smokers. *Cancer Epidemiology and Prevention Biomarkers*, 8(10), 907-913.
 40. Drotman, R. B., & Lawhorn, G. T. (1978). Serum enzymes as indicators of chemically induced liver damage. *Drug and chemical toxicology*, 1(2), 163-171.
 41. Jalili, C., Tabatabaei, H., Kakaberiei, S., Roshankhah, S., & Salahshoor, M. R. (2015). Protective role of Crocin against nicotine-induced damages on male mice liver. *International journal of preventive medicine*, 6.
 42. [Sánchez-Moreno, C., Larrauri, J. A., & Saura-Calixto, F. (1999). Free radical scavenging capacity and inhibition of lipid oxidation of wines, grape juices and related polyphenolic constituents. *Food Research International*, 32(6), 407-412.
 43. Khorsandi, L., Taherimobarakeh, M. & Kalantari, H. (2006). "The protective effect of turmeric (*Curcuma Longa*) (CL) extract on acetaminophen-induced liver damage in mice." *ZUMS Journal*, 14(55), 23-29.
 44. Balakrishnan, A., & Menon, V. P. (2007). Effect of hesperidin on matrix metalloproteinases and antioxidant status during nicotine-induced toxicity. *Toxicology*, 238(2-3), 90-98.
 45. Mohamed, T., El Aaser, A., & Abo El Alla, W. (1992). "Nicotine effects on total body weight, survival rate and serum protein content in mice." *J Egypt Ger Soc Zool*, 7, 209-217.
 46. Sershen, H., Reith, M. E. A., Banay-Schwartz, M., & Lajtha, A. (1982). Effects of prenatal administration of nicotine on amino acid pools, protein metabolism, and nicotine binding in the brain. *Neurochemical research*, 7(12), 1515-1522.
 47. Villablanca, A. C. (1998). "Nicotine stimulates DNA synthesis and proliferation in vascular endothelial cells in vitro." *Journal of Applied Physiology*, 84(6), 2089-2098.
 48. El-Saify, A. (1994). Effect of nicotine administration on serum lipids of adult male albino rats. *J. union Arab. Biol*, 12, 409-419.
 49. Khairia, B. L. (2009). Combined effect of nicotine and green tea on serum biochemical variables in male albino rats. the School of Science at the Academy of Graduate Studies, MSc thesis unpublished.
 50. Sharif, S., Farasat, T., Fatima, N., Farooq, A., & Naz, S. (2014). Effect of nicotine on hematology, lipid profile and liver enzymes in adult male mice (*Mus musculus*). *Adv Anim Vet Sci*, 2(0), 1.
 51. Morgan, T. M., Crawford, L., Stoller, A., Toth, D., Yeo, K. T. J., & Baron, J. A. (2004). Acute effects of nicotine on serum glucose insulin growth hormone and cortisol in healthy smokers. *Metabolism*, 53(5), 578-582.

52. Gawish, A. M., Issa, A. M., Bassily, N. S., & Manaa, S. M. (2012). Role of green tea on nicotine toxicity on liver and lung of mice: Histological and morphometrical studies. *African Journal of Biotechnology*, 11(8), 2013-2025.
53. Neogy, S., Das, S., Mahapatra, S. K., Mandal, N., & Roy, S. (2008). Amelioratory effect of *Andrographis paniculata* Nees on liver, kidney, heart, lung and spleen during nicotine induced oxidative stress. *Environmental Toxicology and Pharmacology*, 25(3), 321-328.
54. El-Zayadi, A.R. (2006). "Heavy smoking and liver." *World journal of gastroenterology: WJG*, 12(38), 6098.
55. Tandon, S., & Tewari, P. (1987). "Effect of co-exposure to ethanol and cadmium in rats." *Bulletin of environmental contamination and toxicology*, 39(4), 633-640.
56. Gupta, V., & Gill, K. D. (2000). "Influence of ethanol on lead distribution and biochemical changes in rats exposed to lead." *Alcohol*, 20(1), 9-17.
57. Yanni, M., Abd El-Dayem, S.M., & Abd El-Azim, B.H. (1991). Biochemical and histological changes due to preservative in rats. *Egypt. J. Histol*, 14 (2), 431-449.
58. Helal, E. G. (2001). "Progressive effects of the interaction of sodium nitrite and sunset yellow on different physiological parameters in albino rats." *Egypt J Hosp Med*, 2, 23-46.
59. Peters, T., & Peters, J. C. (1972). "The biosynthesis of rat serum albumin VI. Intracellular transport of albumin and rates of albumin and liver protein synthesis in vivo under various physiological conditions." *Journal of biological chemistry*, 247(12), 3858-3863.
60. Kaplowitz, N. (2000). "Mechanisms of liver cell injury." *Journal of hepatology*, 32, 39-47.
61. Crăciun, C., & Rusu, M. (1980). "Ultrastructural changes in the liver of aminophenazone-and nitrite-intoxicated rats." *Morphologie et embryologie*, 26(2), 163-166.
62. Gordienko, V., & Didenko, M. (1977). "Electron microscopic study of rat hepatocytes following exposure to dicyclohexylamine nitrite and an oil-soluble salt of cyclohexylamine." *TSitologija i genetika*, 11(1), 76-78.