

Case Report

Post-Tubercular Allergic Bronchopulmonary Aspergillosis: A Mystery of Clinico-Immunological Association

Jebin Abraham¹, Jawahar Lal Joshi², Arjun Bhatnager^{1*}, Komaldeep Kaur³, Anu Bharti¹ and Ajaypal Singh¹

¹Junior Resident, Department of Pulmonary Medicine, Government Medical College, Patiala, Punjab, India

²Assistant Professor, Department of Pulmonary Medicine, Government Medical College, Patiala, Punjab, India

³Senior Resident, Department of Pulmonary Medicine, Government Medical College, Patiala, Punjab, India

*Corresponding Author

Dr. Arjun Bhatnager

Abstract: Allergic bronchopulmonary aspergillosis (ABPA) is known to complicate asthma and cystic fibrosis. *Aspergillus* sensitization is known to be highly prevalent in patients with tuberculosis-related fibrocavitary disease. However, frank ABPA is uncommon in such patients. We present the case of a young lady who was diagnosed with sputum positive pulmonary tuberculosis who developed ABPA after completion of anti-tubercular treatment. Whether ABPA developed after tubercular infection or it was in asymptomatic stage while tuberculosis was diagnosed is a matter of dispute in this case. Coexistence of tuberculosis and ABPA in itself is an unusual entity as explained by the contrasting immune-pathogenesis of both these entities.

Keywords: Allergic bronchopulmonary aspergillosis; Tuberculosis; Fibrocavitary disease; Immuno-pathogenesis; *Aspergillus fumigatus*.

INTRODUCTION:

Allergic bronchopulmonary aspergillosis (ABPA) commonly occurs in asthma and cystic fibrosis patients and is described to be a hypersensitivity reaction to *Aspergillus fumigatus* that colonize the airways (Tillie-Leblond, I., & Tonnel, A.B. 2005). *Aspergillus fumigatus* is a ubiquitous fungus having variable clinical manifestations in affected human beings which includes saprophytic growth, invasive aspergillosis and ABPA. Allergic bronchopulmonary mycosis is a yet broader term used to include the similar disease caused by other fungi (Al-Mobeireek, A. F. *et al.*, 2001). Prevalence of ABPA is 13% in asthmatics at referral centers while up to 9% in cystic fibrosis patients (Denning, D. W. *et al.*, 2013; Maturu, V.N., & Agarwal, R. 2015). ABPA is very rarely diagnosed in patients without a history of asthma or cystic fibrosis (Gupta, M. *et al.*, 2012). Association of tuberculosis and ABPA has been a matter of clinical interest for long time. Occurrence of ABPA in old healed tuberculosis patients has been rarely documented in literature (Agarwal, R. *et al.*, 2008).

Here we present a case of allergic bronchopulmonary aspergillosis that manifested clinically after a short course of antitubercular treatment administered for microbiologically confirmed pulmonary tuberculosis.

Case Report:

A 24 years old lady was presented with dry cough, fever and loss of appetite for 2 months duration. She was a house wife and denied any exposure to pets or organic dust. There was no past history of allergies, asthma or any respiratory illness. On examination, pallor present. Vitals stable. Body mass index was 24.6 kg/m². Chest examination was unremarkable, except for crepitations heard in right infrascapular area.

Hematological parameters showed Hb-9.8g/dl, total leucocyte count- 11200 cells/mm³ with neutrophilia. Rest all parameters were within normal range. Chest X ray showed a well-defined cavitory lesion with air-fluid level in right lower zone. Rest of the parenchyma appeared normal [fig 1].

Quick Response Code



Journal homepage:

<http://www.easpublisher.com/easims/>

Article History

Received: 17.06.2019

Accepted: 29.06.2019

Published: 20.07.2019

Copyright @ 2019: This is an open-access article distributed under the terms of the Creative Commons Attribution license which permits unrestricted use, distribution, and reproduction in any medium for non commercial use (NonCommercial, or CC-BY-NC) provided the original author and source are credited.

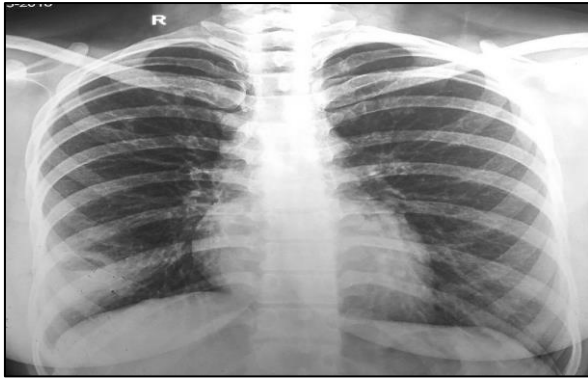


Figure 1: Showing a cavity with air-fluid level in right lower zone

Contrast enhanced CT scan of chest showed findings consistent with lung abscess in right lower lobe. Sputum induction was performed with 3% NaCl. Sputum Gram stain, culture and fungus were negative. Sputum AFB smear showed positive result, further confirmed by GeneXpert, which detected *Mycobacterium tuberculosis* sensitive to rifampicin. Hence she was started on standard antitubercular treatment as per Revised National Tuberculosis Control Programme (RNTCP). She had symptomatic improvement over few weeks. Her follow-up chest x ray showed improvement. Sputum AFB at end of continuation phase of treatment was negative. She completed the treatment course of 6 months successfully.

About 14 months after initial presentation, she developed right sided chest pain. It was dull aching type pain, without any radiation. She also had dry cough on and off. No history of breathlessness or chest tightness. She consulted a nearby physician who prescribed symptomatic medications. However, chest pain persisted. She also had cough with occasional expectoration of yellowish-white mucus plugs. After about one month of these symptoms, she had an episode of hemoptysis following which she attended our Emergency Department. Upon presentation, she was anxious, vitals stable, chest examination unremarkable. ECG was normal. Chest x ray showed ill-defined heterogeneous opacity in right lower zone [Fig 2].

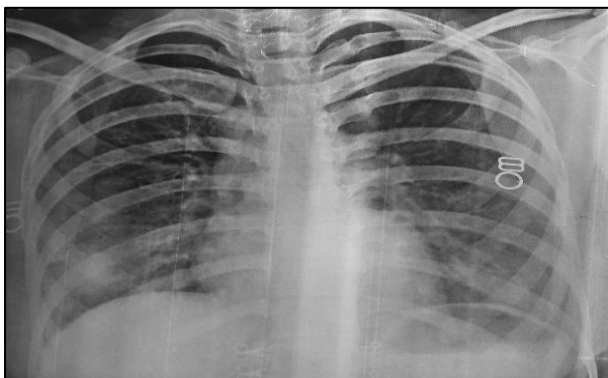


Figure 2: Showing ill-defined heterogeneous opacity in right lower zone

HRCT chest showed bronchiectasis, mucus plugs and nodular opacities scattered throughout lung field on either side [Fig 3b]. *Aspergillus* skin sensitivity test showed positive result for *Aspergillus fumigatus*. Absolute eosinophil count was 870 cells/mm³. Total IgE was 12400 IU/ml. Specific IgE for *Aspergillus fumigatus* was 8.6 kUA/L. Hence, she was diagnosed to have allergic bronchopulmonary aspergillosis. Her pulmonary function tests showed mild obstruction with partial bronchodilator reversibility. Sputum Gram stain, culture, fungus stain, AFB stain and liquid culture for *Mycobacterium tuberculosis* all were negative.

She was started on Prednisolone 0.5 mg/kg/day along with Itraconazole 200 mg twice daily. She had symptomatic improvement. Follow-up total IgE level was 8200 IU/ml after 6 weeks. Serial chest x rays showed clearing of opacities. However, she was lost to follow-up after 4 months of treatment.

DISCUSSION

Owing to high burden of tuberculosis in Indian subcontinent, it is not infrequent that ABPA getting misdiagnosed as pulmonary tuberculosis and treated with antitubercular drugs (Agarwal, R. *et al.*, 2006). An overlapping clinico-radiological spectrum of both these diseases often misleads the clinician especially in primary care settings.

ABPA has been described rarely in non-asthmatic patients (Agarwal, R. *et al.*, 2009). However, occurrence of ABPA in patients with past history of tuberculosis is an extremely rare entity. *Aspergillus fumigatus* is known to colonize pre-existing cavities in the lung, producing aspergilloma. Also, it is worth to mention evidence that revealed high prevalence of *Aspergillus* sensitization among subjects with pulmonary tuberculosis-related fibrocavitary disease. However, clinical significance of this finding needs yet to be established (Dhooira, S. *et al.*, 2014).

Immune mechanism associated with tuberculosis pathogenesis is Th1 mediated while that of ABPA is Th2 mediated. This contrasting immunological polarizations virtually incapacitates the coexistence of these two clinical conditions, at least on theoretical basis. It is postulated that, shift of Th2 to of Th1 response as a result of an effective antitubercular treatment might increase susceptibility to bronchial asthma and probably ABPA (Rajasekaran, S. *et al.*, 2001). However, can this change occur in such a shorter duration as in our case? It needs evidence based clarification.

Another possibility is that ABPA would have been in an asymptomatic or preclinical phase while patient got infected with tuberculosis. Lower lobe tuberculosis is a rare entity as such in people without any predisposing conditions. This fact points towards existence of subclinical ABPA in our patient during the

initial presentation itself. Tuberculosis could be considered to be a coincidental infection in this case. Upon comparing the CT scans taken 14 months apart, there is drastic variations in the lesions found [Fig-3]. Mucus plugs, cavitation, bronchiectasis, and centrilobular nodules has become apparent in the second CT scan which was taken at the time of ABPA

diagnosis. Though not significant, a few bronchiectatic lesions were visible on initial CT scan also. Hence, possibly ABPA could be considered as a differential diagnosis of post-tubercular obstructive airway disease and need to be excluded while such cases are encountered.

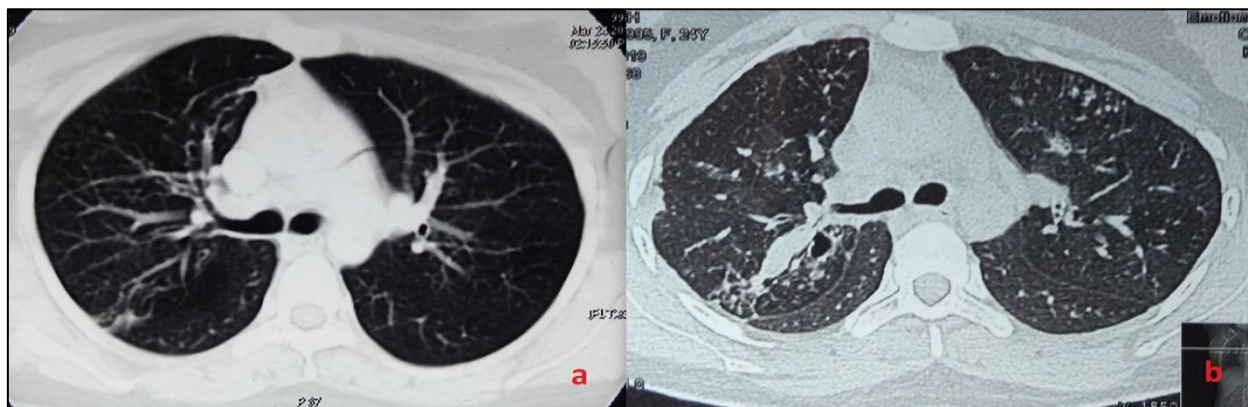


Figure 3: Comparing a section of contrast enhanced CT scan at the diagnosis of tuberculosis (a) with that of high resolution CT scan at diagnosis of ABPA (b). Mild bronchiectatic lesions are seen in initial scan (a) while there is mucus plugs and air space nodules in addition to bronchiectasis in latter (b).

Chest pain has not been mentioned as a chief presenting symptom of ABPA. Absence of features suggesting asthma further complicated this clinical scenario. ABPA, being a destructive lung disease requires early diagnosis and treatment for a better prognosis. Guidelines do not recommend treatment for asymptomatic cases. However, as in current scenario, there can be atypical presentations which might delay the diagnosis. Whether any medications given in the asymptomatic stage would have positive impact over the disease course is a subject of debate.

CONCLUSION

Occurrence of allergic bronchopulmonary aspergillosis outside the setting of underlying asthma or cystic fibrosis is rare. ABPA can occur in old tuberculosis-related cavitory lung disease. Possibility of ABPA should be considered in patients with post tubercular obstructive airway disease. More research should be carried out regarding association of tuberculosis and ABPA, with avid interest in their immuno-pathogenesis. Subclinical course of ABPA is an entity which needs to be studied further.

REFERENCE:

1. Tillie-Leblond, I., & Tonnel, A.B. (2005). Allergic bronchopulmonary aspergillosis. *Allergy*, 60, 1004–13.
2. Al-Mobeireek, A. F., El-Rab, M. G., Al-Hedaithy, S. S. A., Alasali, K., Al-Majed, S., & Joharjy, I. (2001). Allergic bronchopulmonary mycosis in patients with asthma: period prevalence at a university hospital in Saudi Arabia. *Respiratory medicine*, 95(5), 341-347.
3. Denning, D. W., Pleuvry, A., & Cole, D. C. (2013). Global burden of allergic bronchopulmonary aspergillosis with asthma and its complication chronic pulmonary aspergillosis in adults. *Medical mycology*, 51(4), 361-370.
4. Maturu, V.N., & Agarwal, R. (2015). Prevalence of Aspergillus sensitization and allergic bronchopulmonary aspergillosis in cystic fibrosis: systematic review and meta-analysis. *ClinExp Allergy*, Dec; 45(12), 1765-78.
5. Gupta, M., Roshan, R., & Chhabra, S.K. (2012). Allergic bronchopulmonary aspergillosis without asthma complicating pulmonary tuberculosis. *Lung India*, 29(3), 286–88.
6. Agarwal, R., Aggarwal, A.N., & Singh, N. (2008). An unusual association between *Mycobacterium tuberculosis* and *Aspergillus fumigatus*. *Monaldi Arch Chest Dis*, 69, 1, 32-34.
7. Agarwal, R., Gupta, D., Aggarwal, A.N., Behera, D., & Jindal, S.K. (2006). Allergic bronchopulmonary aspergillosis: lessons from 126 patients attending a chest clinic in north India. *Chest*, Aug; 130(2), 442-8.
8. Agarwal, R., Aggarwal, A.N., Gupta, D., Bal, A., & Das, A. (2009). Case report: A rare cause of miliary nodules – allergic bronchopulmonary aspergillosis. *Br J Radiol*, 82, e151–4.
9. Dhooria, S., Kumar, P., Saikia, B., Aggarwal, A.N., Gupta, D., Behera, D., Chakrabarti, A., & Agarwal, R. (2014). Prevalence of Aspergillus sensitisation in pulmonary tuberculosis-related fibrocavitary disease. *Int J Tuberc Lung Dis*, Jul;18(7), 850-5
10. Rajasekaran, S., Savithri, S., & Jeyaganesh, D. (2001). Post Tuberculosis Bronchial asthma. *Ind. J Tub*, 48, 139-42.