

## Case Report

## Giant Lipoma of the Back

Apoorva HC<sup>1</sup>, Amit Kumar C Jain<sup>2\*</sup> and Suresh Kumar<sup>2</sup><sup>1</sup>Clinical Coordinator and Research Assistant, Brindhavvan Areion Hospital, Bengaluru, India<sup>2</sup>Consultant, Brindhavvan Areion Hospital, Bengaluru, India

\*Corresponding Author

Amit Kumar C Jain

**Abstract:** Lipoma is a common benign tumor which can occur over any part of the body and that's why it's known as universal tumor. They often occur as solitary and are small sized. The lipoma is considered to be a giant lipoma if it is more than 10cm or if it weights more than 1000gm. We hereby presents and interesting case of giant lipoma over back in a female patient. The swelling was removed completely and her biopsy was consistent with the clinical diagnosis.

**Keywords:** Lipoma, Giant, Back, Surgery.

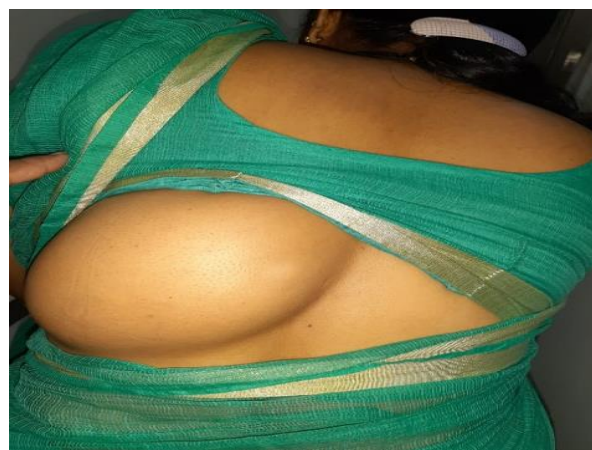
## INTRODUCTION

Lipomas are one of the most common benign soft tissue tumors of mesenchymal origin arising from primordial adipocytes rather than adult fat cells (Pattanayak, S. *et al.*, 2014; Adebayo, O.O. *et al.*, 2013; Skomorac, R. 2006; Salam, G.A. 2002). The lipoma can arise from anywhere in the body where fat is present and hence it is also known as ubiquitous or universal tumor (Jain, A.K.C. *et al.*, 2014; Emegoakor, C.D. *et al.*, 2017). The common sites where they occur regularly are trunk, neck, shoulders and axilla (Skomorac, R. 2006).

Most of the lipomas are small in size (Jain, A.K.C. *et al.*, 2014; Guler, O. *et al.*, 2015). Lipomas that are more than 10cm in size or those which weigh 1000gm are called as giant lipomas (Adebayo, O.O. *et al.*, 2013; Guler, O. *et al.*, 2015). We hereby present an interesting case of giant lipoma occurring over back.

## CASE REPORT

A 39 years old female presented with history of swelling over back from 1 year which was gradually increasing in size. There was pain, fever or any trauma. From past one month, she was having discomfort while lying supine. There was no history of diabetes. On local examination a swelling of 20cm×25cm in size was present over left side of the back [Figure 1].



**Figure 1** showing the swelling over the back

It was soft, nontender, well defined and mobile with pseudo fluctuation. The skin over the swelling was normal. A clinical diagnosis of lipoma was made. She was a known case of pancytopenia. Creatinine was normal. Ultrasound of the swelling showed a large well-defined isoechoic lesion in the lumbar region in subcutaneous plane suggestive of lipoma. Patient underwent surgical excision under general anesthesia [Figure 2]. The specimen was sent for histopathology which showed features consistent with lipoma. Her post-operative recovery was normal.

Quick Response Code



Journal homepage:

<http://www.easpublisher.com/easims/>

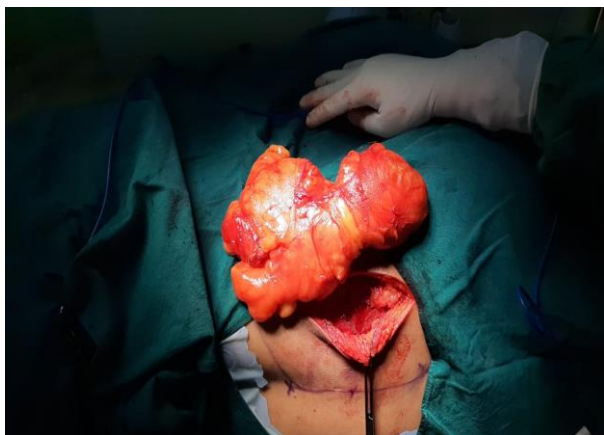Article History

Received: 17.06.2019

Accepted: 09.06.2019

Published: 26.07.2019

Copyright @ 2019: This is an open-access article distributed under the terms of the Creative Commons Attribution license which permits unrestricted use, distribution, and reproduction in any medium for non commercial use (NonCommercial, or CC-BY-NC) provided the original author and source are credited.



**Figure 2 showing intraoperative picture of the Giant lipoma**

## DISCUSSION

Lipomas are asymptomatic, slow growing benign tumors which is often seen in adults aged between 40-60 years (Skomorac, R. 2006; Emegoakor, C.D. *et al.*, 2017). 80% of the cases are solitary and are less than 5cm in size (Skomorac, R. 2006). Their prevalence rate is 2.1 per 1000 tumors (Ricci, J. A. 2018). Giant lipomas are rare in clinical practice (Adebayo, O.O. *et al.*, 2013). One of the largest sizes of giant lipoma was reported in 1894 wherein it weighed 22.7 kg and was present on the scapula of the man (Pattanayak, S. *et al.*, 2014; Emegoakor, C.D. *et al.*, 2017; Guler, O. *et al.*, 2015). Adebayo et al (Adebayo, O.O. *et al.*, 2013) reported a giant lipoma of 24cm×15cm×10cm in the gluteal region whereas Guler et al (Guler, O. *et al.*, 2015) reported 38cm×2cm×21cm giant lipoma weighing 3575 gm over back.

Abdul Salam et al (Abdul Salam, T. *et al.*, 2015) reported a giant lipoma of 19cm×17cm×6.7cm over back whereas in our case it was 20cm×25cm×4.2cm over back.

The exact etiopathogenesis of lipomas are unknown (Guler, O. *et al.*, 2015; Ferraro, G.A. *et al.*, 2015). An association with obesity, diabetes, radiation, hyper cholesterolemia, familial tendency and trauma has been reported (Emegoakor, C.D. *et al.*, 2017; Guler, O. *et al.*, 2015; Ferraro, G.A. *et al.*, 2015). Trauma is considered to be an important factor in the lipoma (Emegoakor, C.D. *et al.*, 2017; Abdul Salam, T. *et al.*, 2015). It is believed that trauma leads to rupture of the fibrous septa accompanied by tears of the anchorage leading to proliferation of adipose tissue (Emegoakor, C.D. *et al.*, 2017; Guler, O. *et al.*, 2015; Ferraro, G.A. *et al.*, 2015).

It is also presumed that inflammation occurs locally due to trauma which results in differentiation of pre-adipocytes and disrupts the normal regulation of adipose tissue (Emegoakor, C.D. *et al.*, 2017). Genetically, it is reported that there is possible correlation between lipoma and deletion and

translocation of chromosome 12 (Serbest, S. *et al.*, 2015).

Although asymptomatic in most cases, they are often cosmetically disfiguring and can sometimes produce functional problems, pain or nerve compression based on location (Serbest, S. *et al.*, 2015; Waquar, S. H. *et al.*, 2014).

Most often the diagnosis is clinically, FNAC, ultrasound, CT scan and MRI can be used in lipoma diagnosis (Emegoakor, C.D. *et al.*, 2017; Serbest, S. *et al.*, 2015). Ultrasound is cheap, easily available, non-invasive in nature and shows lipoma to be iso or hyper echoic (Serbest, S. *et al.*, 2015).

Histologically, lipoma can be classic, angiolipoma, fibrolipoma, infiltrative lipoma, pleomorphic lipoma and a hibernoma (Serbest, S. *et al.*, 2015; Derin, A. T. *et al.*, 2017).

The treatment of giant lipomas is surgical excision though liposuction has been attempted in some cases (Jain, A.K.C. *et al.*, 2014; Emegoakor, C.D. *et al.*, 2017; Ferraro, G.A. *et al.*, 2015).

## CONCLUSION

Giant lipoma is rare in occurrence and can occur at any location. Though it can be diagnosed clinically, imaging modalities may be helpful in some cases especially when one has to rule out malignancy. Surgical excision is treatment of choice for giant lipomas.

## REFERENCES

1. Pattanayak, S., & Pramanik, S. (2014). Giant axillary lipoma –A rare case report with review of literature. *Hellenic J Surgery*, 86(6), 383-385.
2. Adebayo, O. O., Ranti, B. O., & Olateju, A. O. (2013). Giant lipoma of the right gluteal region. *J Med Tropics*, 15(2), 168-70.
3. Skomorac, R. (2006). A benign giant lipoma of the posterior neck. *Medicinski Glasnik*, 3(2), 67-68.
4. Salam, G. A. (2002). Lipoma excision. *Am Fam Physician*, 65, 901-904.
5. Jain, A. K. C., & Vishwanath, S. (2014). Giant lipoma in the cervico-shoulder region. *Int J Adv Med*, 1(1), 61-62.
6. Emegoakor, C. D., Echezona, C. N., Onwukamuche, M. E., & Nzeakor, H. O. (2017). Giant lipoma-A case report of two cases. *Niger J Gen Pract*, 15,46-9.
7. Guler, O., Mutlu, S., & Mahirogullari, M. (2015). Giant lipoma of the back-affecting quality of life. *Ann Med Surg*, 4, 279-282.
8. Ricci, J. A. (2018). Untreated for 20 years: A 14 Kilogram subcutaneous lipoma. *World J Plast Surg*, 7(3), 368-371.
9. Abdulsalam, T., Osuafor, N., Barrett, M., Daly, T. (2015). A Giant Lipoma. *BMJ Case Rep*.

10. Ferraro, G.A., Salzillo, R., & Francesco, F.D., et al. (2015). Approach and management of a giant lipoma in the left lumbar region. *Int J Surg Case Reports*, 14, 189-193.
11. Serbest, S., Tiftikci, U., Kesgin, E., & Tosun, H. B. (2015). Giant lipoma of the upper back: A case report. *Our Dermatol online*, 6(4), 447-449.
12. Waquar, S. H., Abdullah, M. T., Khan, S. A., Malik, Z. I., & Zahid, M. A. (2014). Giant lipoma of the thigh. *Ann Pak Inst Med Sci*, 10(1), 57-59.
13. Derin, A. T., & Yaprak, N. (2017). Lipomas: Review and evaluation of the literature. *Clin Surg*, 2, 1615.