

Research Article

Arthroscopic Ankle Arthrodesis in Ankle Joint Arthritis

Dr. Siddharth Gupta¹, Dr Gunjan Upadhyay², Dr. Nitin Kimmatkar*³ and Dr. Vinit Yadav⁴¹MS Orthopaedic Consultant orthopaedic Surgeon ILS Hospitals, West Bengal, India²Trainee Orthopedic Surgeon MBBS, DNB (Pursuing) Calcutta Medical Research Institute, Kolkata, India³MS Orthopaedic (GMCH Nagpur) Associate Professor, Department of Orthopaedics, GMCH, Nagpur, Maharashtra, India⁴Consultant orthopaedic Surgeon Popular Hospital, Varanasi, Uttar Pradesh, India

Article History

Received: 04.06.2020

Accepted: 16.06.2020

Published: 21.06.2020

Journal homepage:

<https://www.easpublisher.com/easjop>

Quick Response Code



Abstract: Introduction:- Tibio-talar arthrodesis remains the surgical procedure used most frequently for post-traumatic arthritis after conservative measures have been exhausted. Minimal invasive ankle arthrodesis with arthroscopic assistance have advantages over conventional one. **Methods:-** An evaluation of prospectively case series study done on 32 patients that underwent arthroscopic ankle arthrodesis in 2015-19. Clinical assessment was done foot and ankle disability index and visual analog scale score for pain. Radiological assessment was done by serial x rays. All patients underwent arthroscopic assisted ankle arthrodesis. Regular follow-ups were taken till one year. **Results:-** All cases showed radiological evidence of fusion at 3 months. After a mean 6 months follow up there was significant improvement in terms of foot and ankle disability index and visual analog scale in terms of pain. **Conclusions:-** Arthroscopic assisted ankle arthrodesis is a effective way to treat ankle arthritis where conservative management has failed.

Keywords: ankle arthritis, arthroscopic assisted arthrodesis

Copyright © 2020 The Author(s): This is an open-access article distributed under the terms of the Creative Commons Attribution **4.0 International License (CC BY-NC 4.0)** which permits unrestricted use, distribution, and reproduction in any medium for non-commercial use provided the original author and source are credited.

INTRODUCTION

Tibio-talar arthrodesis remains the surgical procedure used most frequently for post-traumatic arthritis after conservative measures have been exhausted. Other indications for ankle arthrodesis include pyogenic arthritis, degenerative or inflammatory arthritis, avascular necrosis of the talus, salvage of a failed ankle arthroplasty, and severe deformity resulting from a neurologic or neuromuscular disorder (Morrey, B. F., & Wiedeman, J. G. 1980; Stauffer, R. N. 1982; & Maurer, R. C. *et al.*, 1991). There have been numerous techniques described to obtain a stable arthrodesis of the tibio-talar joint (Maurer, R. C. *et al.*, 1991; Kennedy, J. C. 1960; Soren, A. 1968; ANDERSON, R. 1945; CAMPBELL, C. J. *et al.*, 1974; Cook, W. G., & Mader, J. T. 1989; GRAHAM, C. E. 1970; Marcus, R. E. *et al.*, 1983; Mazur, J. M. *et al.*, 1979; Morgan, C. D. *et al.*, 1985; MORRIS, H. D. *et al.*, 1971; Myerson, M.S., & Allon, S.M. 1989; Scranton, P.E. 1985; Myerson, M. S., & Quill, G. 1991; Mears, D. C. *et al.*, 1991; Malarkey, R. F., & Binski, J. C. 1991; Mann, R. A. *et al.*, 1991; & Ratliff, A. H. C. 1959). Several studies have found that, once fusion has occurred, patients have a high degree of satisfaction in relief of pain and function (Morrey, B. F., & Wiedeman, J. G. 1980; Mazur, J. M. *et al.*, 1979; Morgan, C. D. *et al.*, 1985; Mann, R. A. *et al.*, 1991; & Buck, P. *et al.*, 1987).

For ankle arthritis where conservative management failed, ankle arthrodesis by open technique had been a standard treatment.

In the year 1983, arthroscopy assisted ankle arthrodesis has become popular with time and lot of surgeon trying the technique. The rate of fusion between the two techniques is comparable, but the arthroscopic method is thought to have a decreased time to fusion, less blood loss, less morbidity, decreased complication rate, shorter hospital stays, decreased cost and more rapid mobilisation (O'Brien, T. S. *et al.*, 1999; & Myerson, M. S., & Quill, G. 1991). The arthroscopic technique also allows fusion in patients with both poor skin and wound healing potential which would previously have been a contraindication to the open technique. Recently, ankle arthroscopy has also been shown to be useful in the treatment of a variety of pathologies about the ankle, including loose bodies, osteochondral lesions, and debridement of synovitis and arthritic conditions (Myerson, M.S., & Allon, S.M. 1989; Myerson, M. S., & Quill, G. 1991; & Sisk, T.D. 1987). Over the past 2 decades, improvements in arthroscopic instrumentation and techniques have made it possible to perform an extensive debridement of the ankle also. In combination with per-cutaneous internal screw fixation, a successful arthrodesis can be performed through minimal incisions. The principles of

compression and rigid internal fixation of the tibio-talar joint, combined with the soft-tissue sparing advantage of arthroscopy, which allow for a successful fusion has made arthroscopic technique a better standard for ankle arthrodesis now.

MATERIAL AND METHODS

This is a prospective case series study done on 32 patients who underwent arthroscopic assisted ankle arthrodesis in 2015-19. Hospital and office records, and radiographs were studied for demographic data, prior operations, duration of symptoms, and time to clinical and radiographic union were taken into account. The patients who underwent arthrodesis were post-traumatic osteoarthritis. The indications for arthrodesis were pain and impairment of function that did not respond to conservative treatment. All patients described severe mechanical pain as the most important reason for undergoing the procedure. The mean duration of preoperative symptoms was 4.5 years (range- 1 to 9 years). Pre-operative weight bearing AP and lateral radiographs were assessed.

Union was defined as a clinically stable ankle, painless on manipulation and weight bearing and absence of tibio-talar motion at examination, along with no pain or crepitus on ambulation, with radiographic evidence of bridging trabeculae across the tibiotalar arthrodesis area without failure of internal fixation or change in position. Functional assessment was done in terms of foot and ankle disability index score and pain assessment by Visual Analog scale. Regular follow ups were taken 2 weeks, 6 weeks, 3 months, 6 months , 1 year and then yearly were done.

All patients were performed arthroscopic procedure spinal anesthesia with the patient in the supine position with a bolster under the thigh to flex the hip 30 degrees. A pneumatic tourniquet is used at the start of the procedure during preparation of the surfaces. Arthroscopy of the ankle is performed using a 2.7-mm 30° arthroscope. Four arthroscopic portals were used. The standard anteromedial and anterolateral portals are

established medial to the tibialis anterior tendon and lateral to the extensor digitorum communis tendons, respectively and two posterior portal beside tendoachilis. As debridement moves from anterior to posterior, arthroscopic visualization and instrumentation posteriorly are easily achieved as the joint space increases. The use of distraction devices was not been necessary. Denudation of articular surfaces done with straight and curved curettes, shaver clearing the remaining articular cartilage. A bony burr is then used to remove bone down to a healthy cancellous base demonstrating punctate bleeding which is readily demonstrated if the suction for the burr is maximal. After removal of anterior tibial osteophytes, it is often easiest to initially pass from anterior to posterior on the talar dome, then posterior to anterior on the tibia. Following adequate preparation of the joint surfaces, the foot is positioned correctly in neutral flexion, 0° to 5° hindfoot valgus and external rotation equal to the opposite side if normal, or 5° to 10° if abnormal. Two cannulated cancellous screws were passed across tibio-talar joint via stab incisions over medial surface of tibia. The screws were place from medial surface of tibia ,one anterior and other posterior. Compression was achieved and checked under image intensifier. Once fixation is completed, the arthrodesis is examined clinically for sub-talar motion and crepitus. Fluoroscopy is used to ascertain proper screw placement, with particular attention to verify that the subtalar joint has not been violated. The portals and stab incisions were closed with 3-0 nylon suture and a sterile bulky dressing and a back slab was applied. Postoperatively, the patient is instructed to be non- weight bearing in back slab for 2 weeks with crutch ambulation for the first 6 to 8 days. The splint is then removed, and a short leg walking cast or boot is applied. Partial weight bearing is progressed to weight bearing as tolerated over the next 3 to 6 weeks. Check x-ray is done at 6 weeks Full weight bearing in a walking cast is continued until there is radiographic union and the patient has no pain with ambulation. If there are signs of union, un-protected walking is allowed.

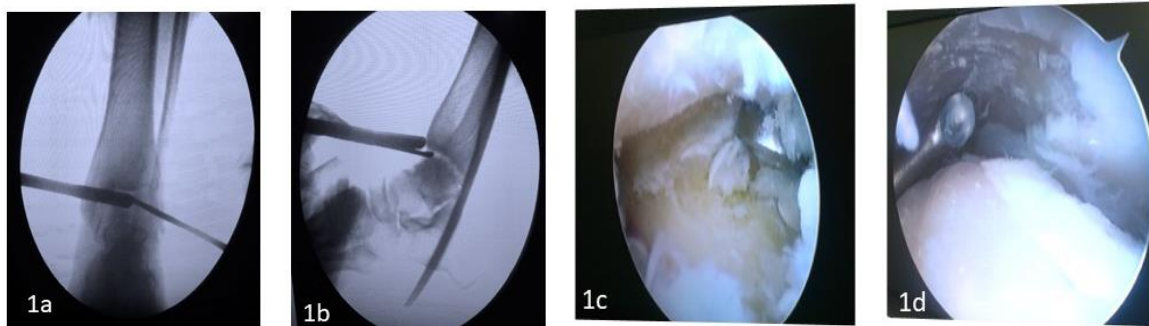

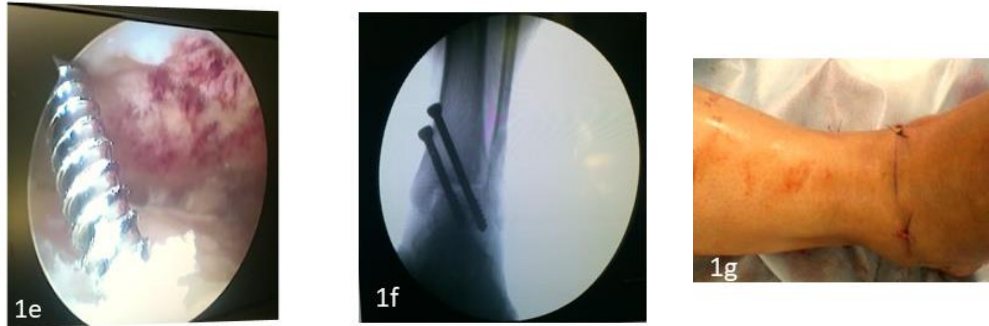
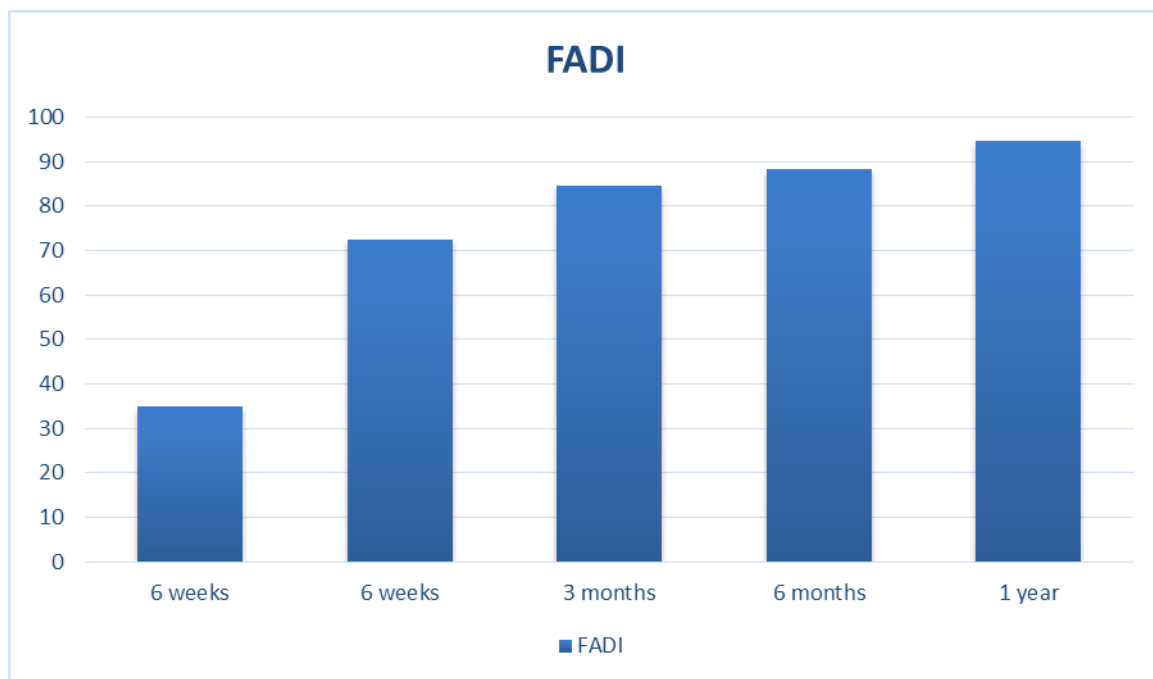


Image 1a&1b -fluoroscopic image of antero-medial and antero-lateral portals, **1c&1d -** shows arthroscopic assisted denudation of articular cartilage with curette, **1e -** shows insertion of screw under arthroscopic ,**1f –** fluoroscopic imaged after applying screws, **1g –** image shows suture site of arthroscopic portals.

RESULTS

The patients included in the study were 36 with 14 women and 22 men with a mean age at the time of arthrodesis of 47.2 years (range- 42 to 69 years). Hospital stays for these patients were less than 24 hours. The average follow up period of these 36 patients was range-12 months to 36 months. Fusion

occurred in all 36 patients (100%). The average time to clinical and radiographic union was 10 weeks (range 6 to 20 weeks). The foot and ankle disability index showed significant improvement as compared to pre-operative assessment. With an average Pre-operative index of 34.8, on 6 months follow up 88.4 and one year follow up index of 94.6.



Figures 1 – Shows average Foot and ankle index with regular follow-ups.

On evaluating individual criteria of Foot and Ankle Disability index(FADI) Pain at rest pre-operatively were severe in 88.9% of patients and 22.1% of patients had moderate pain. On post-operative pain at rest subsided significantly in 6 months to 1 year follow up being 97.2% with no pain and 2.8% of patients had mild pain. Pain on normal activity pre-operatively severe in all the patients, which was significantly

improved on post-operative follow up of 1years, being no pain in 91.7% of patients and mild pain in just 8.3% of patients. Pain first thing in the morning also subsided in all the patients.

On evaluating VAS score showed significant improvement on six to one year follow up.

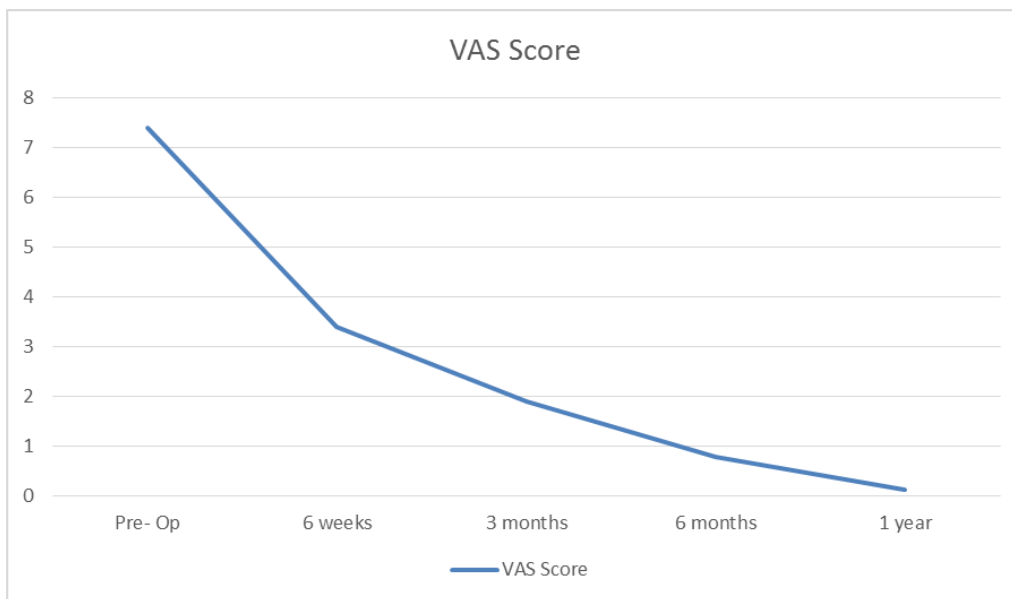


Figure 2 – Shows average Visual Analog Scale for pain with duration of time.

All wounds healed with 2 cases with superficial infection which was managed conservatively with antibiotics. There were no changes noted in the

position of the fusion site from operative to final follow-up radiographic examination.

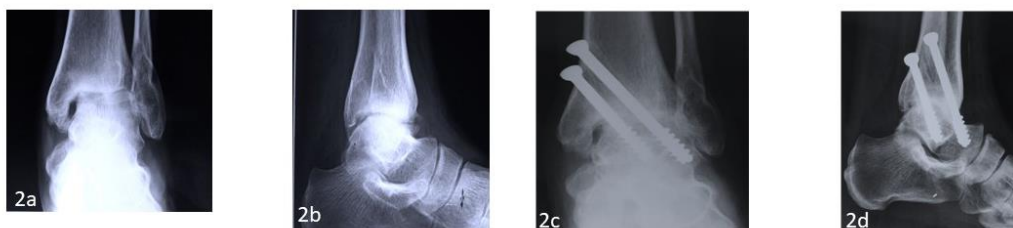

Image 2a&2b – Show pre-operative radiogram of a patient with post traumatic ankle arthritis
Image 2c&2d – Shows post-operative radiogram following arthroscopic assisted ankle arthrodesis.

DISCUSSION

With the advent of arthroscopy, it has become evident that adequate surface preparation for ankle arthrodesis can be performed through small incisions. In a study done by Duan *et al.*, on Arthroscopic assisted arthrodesis for post traumatic ankle arthritis without using bone graft fusion occurred in all 68 cases. On follow-up of one year (American Orthopaedic Foot & Ankle Society ankle) AOFAS ankle/hindfoot score were significantly improved (Duan, X. *et al.*, 2016), which was comparable in our study. Arthroscopically assisted arthrodesis allows for minimal soft-tissue dissection about the ankle area, minimizing de-vascularization of bone at the fusion site. These factors create a favorable environment for fusion to occur and have been credited as reasons for the relatively rapid fusion. In a systematic review by Jung ho *et al.*, on arthroscopic in comparison with open ankle arthrodesis, which include 7 comparative studies suggested that American Orthopaedic Foot & Ankle Society ankle-hindfoot score and the Ankle Osteoarthritis Scale score were better in arthroscopy group. Union rates and reoperation rates though were similar but intra-

operative blood loss and post-operative complications were less in arthroscopy group (Park, J. H. *et al.*, 2018).

In these times of ever-increasing awareness of hospital costs, the use of the arthroscopically assisted technique also appears to reduce the length of hospitalization. In general, this finding can be largely attributed to the relatively mild postoperative pain and swelling that the arthroscopic patients experienced and the reduced need for supervised postoperative pain management and neurovascular monitoring with earlier weight bearing, a reduction in the time to arthrodesis, and earlier return to activities as compared with reported results of traditional open procedures.

CONCLUSIONS

Arthroscopic assisted ankle arthrodesis is a effective way to treat ankle arthritis where conservative management has failed.

REFERENCES

- ANDERSON, R. (1945). Concentric arthrodesis of the ankle joint: a transmalleolar approach. *JBJS*, 27(1), 37-48.
- Buck, P., Morrey, B. F., & Chao, E. Y. (1987). The optimum position of arthrodesis of the ankle. A gait study of the knee and ankle. *The Journal of bone and joint surgery. American volume*, 69(7), 1052-1062.
- CAMPBELL, C. J., RINEHART, W. T., & Kalenak, A. (1974). Arthrodesis of the ankle: deep autogenous inlay grafts with maximum cancellous-bone apposition. *JBJS*, 56(1), 63-70.
- Cook, W. G., & Mader, J. T. (1989). Ankle arthrodesis in the presence of ongoing sepsis. Indications, methods, and results. *The Orthopedic clinics of North America*, 20(4), 709-721.
- Duan, X., Yang, L., & Yin, L. (2016). Arthroscopic arthrodesis for ankle arthritis without bone graft. *Journal of orthopaedic surgery and research*, 11(1), 154.
- GRAHAM, C. E. (1970). 11 A New Method for Arthrodesis of an Ankle Joint. *Clinical Orthopaedics and Related Research (1976-2007)*, 68, 75-77.
- Hagen, R. J. (1986). Ankle arthrodesis. Problems and pitfalls. *Clinical orthopaedics and related research*, (202), 152-162.
- Kellgren, J. H., & Lawrence, J. S. (1957). Radiological assessment of osteo-arthrosis. *Annals of the rheumatic diseases*, 16(4), 494
- Kennedy, J. C. (1960). Arthrodesis of the ankle with particular reference to the Gallie procedure: a review of fifty cases. *JBJS*, 42(8), 1308-1316.
- LANCE, E. M., Paval, A., Fries, I., Larsen, I., & PATTERSON JR, R. L. (1979). Arthrodesis of the ankle joint: a follow-up study. *Clinical Orthopaedics and Related Research*, (142), 146-158.
- Lynch, A. F., Bourne, R. B., & Rorabeck, C. H. (1988). The long-term results of ankle arthrodesis. *The Journal of bone and joint surgery. British volume*, 70(1), 113-116.
- Malarkey, R. F., & Binski, J. C. (1991). Ankle arthrodesis with the Calandruccio frame and bimalleolar onlay grafting. *Clinical orthopaedics and related research*, (268), 44-48.
- Mann, R. A., Van, J. M., Wapner, K., & Martin, J. (1991). Ankle fusion. *Clinical orthopaedics and related research*, (268), 49-55.
- Marcus, R. E., Balourdas, G. M., & Heiple, K. G. (1983). Ankle arthrodesis by chevron fusion with internal fixation and bone-grafting. *The Journal of bone and joint surgery. American volume*, 65(6), 833-838.
- Maurer, R. C., Cimino, W. R., Cox, C. V., & Satow, G. K. (1991). Transarticular cross-screw fixation. A technique of ankle arthrodesis. *Clinical orthopaedics and related research*, (268), 56-64.
- Mazur, J. M., Schwartz, E., & Simon, S. R. (1979). Ankle arthrodesis. Long-term follow-up with gait analysis. *The Journal of bone and joint surgery. American volume*, 61(7), 964-975.
- Mears, D. C., Gordon, R. G., Kann, S. E., & Kann, J. N. (1991). Ankle arthrodesis with an anterior tension plate. *Clinical orthopaedics and related research*, (268), 70-77.
- Miller, S.D., & Myerson, M.S. (1996). Tibiotalar arthrodesis. *Foot Ankle Clin* 1, 151-162.
- Morgan, C. D., Henke, J. A., Bailey, R. W., & Kaufer, H. (1985). Long-term results of tibiotalar arthrodesis. *The Journal of bone and joint surgery. American volume*, 67(4), 546-550.
- Morrey, B. F., & Wiedeman, J. G. (1980). Complications and long-term results of ankle arthrodeses following trauma. *The Journal of bone and joint surgery. American volume*, 62(5), 777-784.
- MORRIS, H. D., HAND, W. L., & DUNN, A. W. (1971). The modified Blair fusion for fractures of the talus. *JBJS*, 53(7), 1289-1297.
- Myerson, M. S., & Quill, G. (1991). Ankle arthrodesis. A comparison of an arthroscopic and an open method of treatment. *Clinical orthopaedics and related research*, (268), 84-95.
- Myerson, M. S., & Quill, G. (1991). Ankle arthrodesis. A comparison of an arthroscopic and an open method of treatment. *Clinical orthopaedics and related research*, (268), 84-95.
- Myerson, M.S., & Allon, S.M. (1989). Arthroscopic ankle arthrodesis. *Con-temp Orthop*, 19, 21-27.
- O'Brien, T. S., Hart, T. S., Shreff, M. J., Stone, J., & Johnson, J. (1999). Open versus arthroscopic ankle arthrodesis: a comparative study. *Foot & ankle international*, 20(6), 368-374.
- Ogilvie-Harris, D. J., Lieberman, I., & Fitsialos, D. (1993). Arthroscopically assisted arthrodesis for osteoarthrotic ankles. *The Journal of bone and joint surgery. American volume*, 75(8), 1167-1174.
- Park, J. H., Kim, H. J., Suh, D. H., Lee, J. W., Kim, H. J., Oh, M. J., & Choi, G. W. (2018). Arthroscopic versus open ankle arthrodesis: a systematic review. *Arthroscopy: The Journal of Arthroscopic & Related Surgery*, 34(3), 988-997.
- Ratliff, A. H. C. (1959). Compression arthrodesis of the ankle. *The Journal of bone and joint surgery. British volume*, 41(3), 524-534.
- Scranton, P.E. (1985). Use of internal compression in arthrodesis of the ankle. *J Bone Joint Surg Am*, 67, 550-555.
- Sisk, T.D. (1987). Arthroscopy of the ankle. In: Crenshaw AH, ed. *Campbell's operative orthopaedics*. Ed 7. *St. Louis: CV Mosby*, 2603-2605.
- Soren, A. (1968). Safe inlay of bone graft in arthrodesis. *Clin Orthop*, 58, 147.
- Stauffer, R. N. (1982). Salvage of painful total ankle arthroplasty. *Clinical orthopaedics and related research*, (170), 184-188.