

## Research Article

## Ophthalmic Manifestations and its Correlation to Platelet Count in Dengue Patients in a Tertiary Care Hospital of Eastern India

Dibya Prabha<sup>1\*</sup>, Yuvraj Lahre<sup>2</sup>, Lily Kumari<sup>3</sup>, Pawan Kumar<sup>4</sup>, Apeksha Singh<sup>5</sup><sup>1</sup>Senior Resident, Department of Ophthalmology, PMCH, Dhanbad, Jharkhand, India<sup>2</sup>Senior Resident, Department of Medicine, MGM Medical College and Hospital, Jamshedpur, Jharkhand, India<sup>3</sup>Senior Resident, Department of Medicine, PMCH, Dhanbad, Jharkhand, India<sup>4</sup>Senior Resident, Department of Medicine, Dumka Medical College and Hospital, Dumka, Jharkhand, India<sup>5</sup>Senior Resident, Department of Dermatology, PMCH, Dhanbad, Jharkhand, India**Article History**

Received: 11.12.2020

Accepted: 21.12.2020

Published: 24.12.2020

**Journal homepage:**<https://www.easpublisher.com>**Quick Response Code**

**Abstract: Purpose:** To determine clinical spectrum of ophthalmic manifestations and its correlation to platelet count in dengue patients. **Materials and methods:** Consecutive patients of dengue disease who presented during June 2019 to August 2019 were evaluated. Complete ocular examinations were done. **Results:** Out of 92 patients, 61.95% were male, 38.04% were female. Mean age of presentation was 32.65 years. Number of patients with ocular symptoms was 33.69% & with ocular signs was 45.65%. Subconjunctival haemorrhage was the commonest ocular findings (25%). Posterior segment findings were present in 11.95%, 7.60% had retinal haemorrhage. 40.50% DF, 72.72% DHF patients and 100% DSS had ocular findings. Ocular findings were present in 19.60% in patients with platelet count > 1 lakh & 83.33% in patients with platelets count < 20000. **Conclusion:** Ophthalmic manifestations are not uncommon but mostly under observed, so ocular examinations in all dengue cases is advised to prevent visual complications.

**Keywords:** Ophthalmic manifestations, Dengue, Subconjunctival haemorrhage, platelets.

**Copyright © 2020 The Author(s):** This is an open-access article distributed under the terms of the Creative Commons Attribution 4.0 International License (CC BY-NC 4.0) which permits unrestricted use, distribution, and reproduction in any medium for non-commercial use provided the original author and source are credited.

### INTRODUCTION

Dengue is vector borne viral disease. Causative virus belongs to Family Flaviviridae which includes four different serotypes (DEN1, DEN2, DEN3, DEN4)[1]. Dengue is one of the major public health problems in tropic and subtropic nations. Due to increasing population, global warming, increased urbanization, inefficient mosquito control, inadequate health care facilities etc there is rise in dengue infection worldwide [2]. First reported case of dengue in India was in Madras and first epidemic of dengue in India was occurred in Calcutta [3].

Dengue is transmitted by bite of female mosquito *Aedes aegypti* and *Aedes albopictus* [4]. Transmission is mostly in rainy season. Etiopathological factors for dengue infections are viral replication in macrophages, immunological reaction against viral antigens [5]. Clinically it is characterised by acute onset of high grade fever which last for 3 days to weeks, malaise, cough, vomiting, headache, body-ache, retro-orbital pain, joint pain, skin rash etc[6]. Other clinical manifestations are due to complications of thrombocytopenia.

Dengue is clinical diagnosis in most of cases, but can be confirmed by with laboratory test such as polymerase chain reaction PCR, immunoglobulin M (IgM, IgG) [7]. Dengue infection is usually self limiting. Recovery from one serotype provides lifelong immunity from that serotype only but not from other serotype so sequential infection from other serotype may cause serious systemic disease such as dengue hemorrhagic fever, dengue shock syndrome.

With increase in number of dengue cases, ocular manifestations associated with dengue also increased. It varies from mild conjunctival congestion to vision threatening complications [8]. So our aim is to highlight ocular manifestations of dengue and to find out correlation with platelet count.

### MATERIALS AND METHODS

- A cross-sectional analytical study of 92 patients with dengue disease who were admitted in dengue ward of department of medicine during June 2019 to August 2019 was done after informed consent and ethics clearance. Inclusion criteria for study

were patients who were serologically positive for NS1 and we excluded patients who were having concurrent febrile illness from malaria etc, DM, HTN, patients in which informed consent could not be obtained. Detailed clinical history, systemic examination, Laboratory reports of CBC, platelet count, serological assay of NS1, IgM, Ig G were noted. Malaria ruled out. Ocular examinations such as BCVA using Snellen chart, Pupillary light response, anterior segment examination using slit-lamp, fundoscopy with indirect ophthalmoscopy were done. Fundus photos were documented in patients with retinal findings. OCT done in patients with maculopathies. A follow up telephone call was made 2 weeks after the onset of fever to rule out any onset of new visual symptoms.

- A correlation study between platelet count and ocular manifestations was done using Pearson correlation coefficient. All statistical analysis were done using SPSS by IBM, version 19.0

## RESULTS

A total of 92 patients of age 15-60 years diagnosed as dengue were enrolled in our study out of which 57(61.95%) were male and 35(38.04%) were female [Table1]. Mean age of presentations was 32.65 years (15-60). Minimum interval between onset of fever and eye examination was 4 days. Patients mainly belong to lower socioeconomic status. In our study all cases presented with fever, myalgia (76.3%), headache 58.34%. other complains were nausea, pain abdomen, loose motions etc. Platelet counts in our study varied widely, lowest being 9000 and median count were 80000.

Ocular findings were seen in 42(45.65%) [Table1]. Out of which anterior segment findings were seen in 33.69% and posterior segment findings were in 11.95%. Among anterior segment findings subconjunctival haemorrhages were seen in 25% which was the most commonly seen ocular findings, chemosis in 7.60%, lid edema 1.08%. Among posterior segment findings retinal haemorrhages were most commonly seen in 7.06%, exudates 1.08%, disc edema 3.26% [Table1].

**Table-1: Ocular findings in patients of dengue**

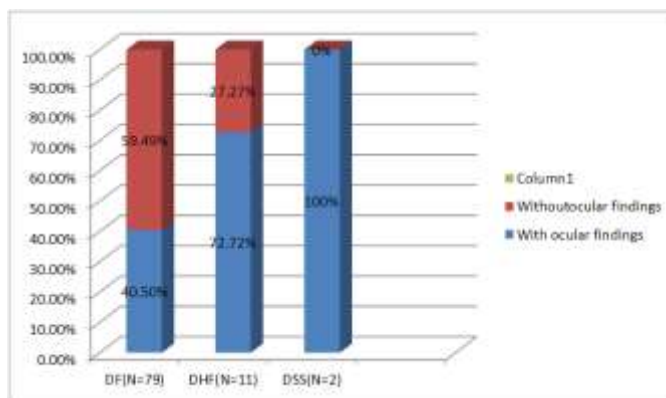
Ocular findings	Number	Percentage
<b>Anterior segment findings</b>	31	33.69%
Subconjunctival hemorrhage	23	25%
chemosis	7	7.60%
Lid edema	1	1.08%
<b>Posterior segment findings</b>	11	11.95%
Retinal hemorrhage	7	7.60%
exudates	1	1.08%
Disc edema	3	3.26%

In cases of dengue fever 40.50% patients had ocular findings, in DHF, 72.72% and in DSS

all 100% were having ocular findings [Table2] [Figure 1].

**Table-2: Ocular manifestations in different dengue patients**

	DF	DHF	DSS	Total
With ocular findings	32(40.50%)	8(72.72%)	1(100%)	42(45.65%)
Without ocular findings	47(59.49%)	3(27.27%)	0	53(54.34%)
Total patients	79	11	1	92



**Fig-1: showing percentage of patients with ocular findings in different dengue patients**

Ocular findings were present in 10(19.60%), 13(61.90%), 14(82.35%), 5(83.33%) in patients with

following Platelets count >100000, 100000-50000, 50k-20k and <20000 [Figure2].

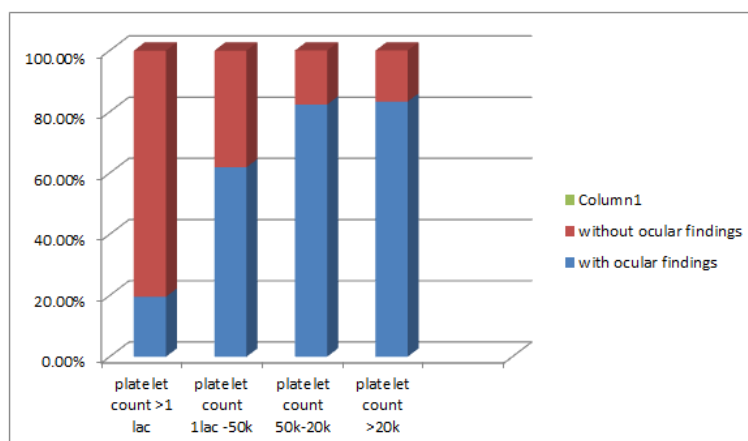


Fig-2: Platelet count and correlation with ocular manifestations

## DISCUSSION

Presently uprise surge in dengue cases are mainly attributable to increased population, increased global temperature, inefficient mosquito control and inadequate health facilities [2, 4, 7]. In our study we found mean age of presentation 32.65years with male preponderance which is similar to other studies [9, 10]. There are very few studies that correlated blood parameters with ocular findings. We reported 45.65% patients had ocular manifestations also noted in study by [11]. Among anterior segment findings 33.69%, SCH was most common in 25% cases which are almost similar to study done by [12]. Only 11.95% patients had posterior segment involvement which is also similar to Kapoor *et al.* [11]. Retinal haemorrhages, exudates, disc edema were most common posterior segment findings. In our study we found 40.50% patients of dengue fever had ocular findings while 72.72% and 100% patients had ocular findings in DHF and DSS which was seen in study done by [13]. In our study we found ocular findings increases with decrease in platelet count. This is also noted by study done by [13] while [14] reported no significant association between thrombocytopenia and hemorrhagic manifestations. In our study, a statistically significant correlation was seen between platelet count and ocular manifestations; this was supported by previous study done by [15].

Our limitation of study was we haven't follow up patients so cannot describe time taken to resolve as our study was non interventional. Smaller sample size, single hospital based study, only hospitalised patients were considered are other limitations which need to improve.

## CONCLUSION

With increase in cases of dengue infection, ophthalmic manifestations expected to rise. Patients with marked thrombocytopenia are more predisposed to ocular complications. It may be simple SCH or retinal haemorrhage which can impair vision. Physician should refer patients of DHF, DSS, with deteriorated blood parameters to ophthalmologist for early detection of ocular manifestations.

## REFERENCES

- Kurane, I. (2007). Dengue hemorrhagic fever with special emphasis on immunopathogenesis. *Comparative immunology, microbiology and infectious diseases*, 30(5-6), 329-340.
- World Health Organization, Special Programme for Research, Training in Tropical Diseases, World Health Organization. Department of Control of Neglected Tropical Diseases, World Health Organization. Epidemic, & Pandemic Alert. (2009). *Dengue: guidelines for diagnosis, treatment, prevention and control*. World Health Organization.
- Gupta, N., Srivastava, S., Jain, A., & Chaturvedi, U. (2012). Dengue in India. *The Indian journal of medical research*, 136(3), 373-390.
- Gubler, D. J. Dengue and dengue hemorrhagic fever. *Clin Microbial Rev.*[Internet]. 1998 [citado 13 de 2015]; 11 (3): 480-96.
- Whitehorn, J., & Simmons, C. P. (2011). The pathogenesis of dengue. *Vaccine*, 29(42), 7221-7228.
- Dhar, S. (2017). A Study on the Clinicopathological Profile and Outcome of a Dengue Epidemic in Western Odisha. *International Journal of Medical Science and Innovative Research*, 2(4):13- 20.

7. Guzman, M. G., Halstead, S. B., Artsob, H., Buchy, P., Farrar, J., Gubler, D. J., & Nathan, M. B. (2010). Dengue: a continuing global threat. *Nature reviews microbiology*, 8(12), S7-S16.
8. Yip, V. C. H., Sanjay, S., & Koh, Y. T. (2012). Ophthalmic complications of dengue fever: a systematic review. *Ophthalmology and therapy*, 1(1), 2.
9. Haritoglou, C., Scholz, F., Bialasiewicz, A., & Klauss, V. (2000). Okuläre Manifestation bei Dengue-Fieber. *Der Ophthalmologe*, 97(6), 433-436.
10. Intizar Hussain, F. C. P. S., Afzal, F., & DOMS, A. S. (2012). Ophthalmic manifestation of dengue fever. *AN OFFICIAL JOURNAL OF PESHAWAR MEDICAL COLLEGE*, 10(1), 93.
11. Kapoor, H. K., Bhai, S., John, M., & Xavier, J. (2006). Ocular manifestations of dengue fever in an East Indian epidemic. *Canadian journal of ophthalmology*, 41(6), 741-746.
12. Rani Sujatha, S. N., Nazlin, A., & Prakash, S. (2015). Ocular manifestations of dengue fever. *Int J Med Sci Public Health*, 4(5), 690-3.
13. Dhar, S. K., Samant, S., Mishra, S., Tripathy, D., Shah, R. D., & Prasad, R. C. Spectrum of Ophthalmic Manifestations of Dengue: Our Experience in a Tertiary Care Centre.
14. Gomber, S., Ramachandran, V.G., Kumar, S. (2001). Haematological observations and diagnostic markers in dengue haemorrhagic fever-a reappraisal. *Indian Pediatr*, 38:477-81.
15. Nagaraj, K. B., Jayadev, C., Yajmaan, S., & Prakash, S. (2014). An unusual ocular emergency in severe dengue. *Middle East African Journal of Ophthalmology*, 21(4), 347.