

## Research Article

### Prostatic Calcifications: About 78 Cases

Redouane Roukhsi<sup>1\*</sup>, Salah ben elhend<sup>1</sup>, Hassan Doulhousne<sup>2</sup>, Nabil Hammoun<sup>3</sup>, El Mehdi Atmane<sup>3</sup>, Abdelilah Mouhsine<sup>3</sup>, El fikri Abdelghani<sup>2</sup>

<sup>1</sup>Radiology service – 3th Military Hospital – Laâyoune – Morocco

<sup>2</sup>Radiology service – 5th Military Hospital – Guelmim – Morocco

<sup>3</sup>Radiology service – HMA Military Hospital – Marrakech – Morocco

Faculté de médecine et de pharmacie, Université Cadi Ayyad, Marrakech, Maroc

#### Article History

Received: 08.12.2020

Accepted: 17.12.2020

Published: 28.12.2020

#### Journal homepage:

<https://www.easpublisher.com>

#### Quick Response Code



**Abstract:** Calcifications of the prostate are frequent and benign. They are not linked to any particular symptom or disease. They are not precursors of prostate cancer. We evaluated in 78 patients, the characteristics of these calcifications and their prevalence according to the presence of urinary symptoms.

**Keywords:** Prostate - Calcifications - Ultrasound.

**Copyright © 2020 The Author(s):** This is an open-access article distributed under the terms of the Creative Commons Attribution **4.0 International License (CC BY-NC 4.0)** which permits unrestricted use, distribution, and reproduction in any medium for non-commercial use provided the original author and source are credited.

## INTRODUCTION

Prostate pathology is essentially tumor and infectious. Prostate imaging has evolved into high resolution spatial and contrast imaging, through precise analysis of all quadrants of the prostate and anatomical analysis of the prostate environment. Prostate calcifications particularly affect people after the age of 50. We evaluated in 78 patients, the characteristics of these calcifications and their prevalence according to the presence of urinary symptoms.

## MATERIAL AND METHODS

This is a prospective study involving 78 patients, collected at the Avicenne military hospital in Marrakech. These patients underwent a prostate ultrasound in which the discovery of prostatic calcification was fortuitous. We have established an operating sheet containing the epidemiological, clinical and ultrasound data for each patient.

## RESULTS

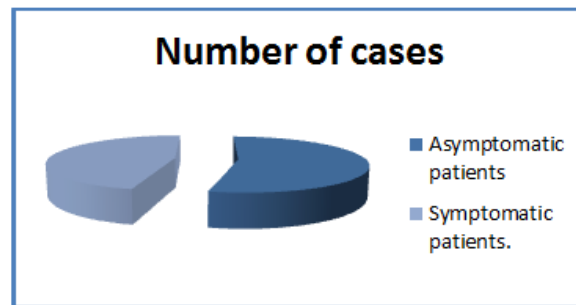
The urogenital antecedents of our patients were dominated by urogenital infections in 50 patients, while the antecedents were found in 13 of our patients, and only one patient with an old trauma (Table 1). Clinical examination found a painful rectal examination (TR) in 6 cases, and a prostate enlarged in 4 cases (Table 2). Clinically, 42 patients were asymptomatic, and 36 patients were symptomatic (Table 3 and Figure 1), 22 patients had signs of prostatism (Table 4), 05 had a urinary tract infection (Table 5 and Figure 2), and 03 had urinary tract stones (Table 6). The ultrasound revealed calcifications in all of us patients (Figure 2). While MRI was performed in 02 of us patients, in whom we suspected neoplastic pathology. These two examinations confirmed the benignity in these patients. The biological assessment found normal PSA in all patients.

**Table-1: The history of our patients**

Antecedents	Number of cases	Percentage %
Urogenital infections	50	64,10
Surgical	13	16,66
Trauma	1	1,28

**Table-2: Signs of the clinical examination**

Signs	Number of cases	Percentage %
TR painful	6	7,69
Prostate increase in size	4	5,12



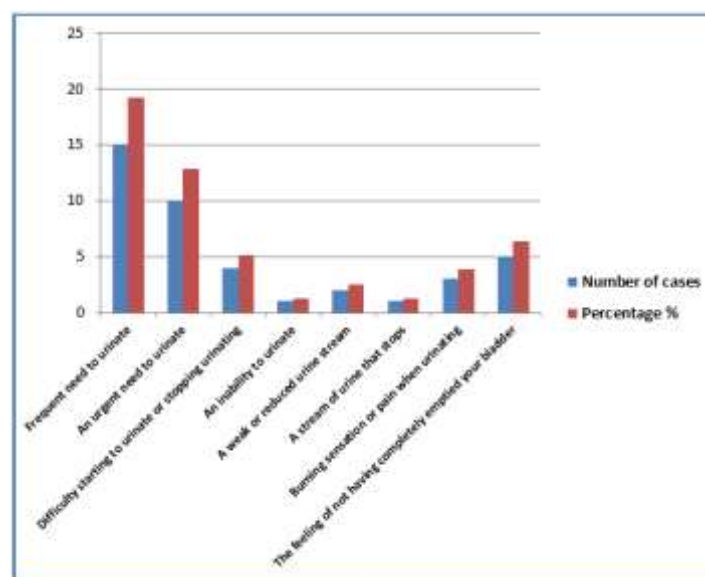
**Fig-1: Clinical Appearance**

**Table-3: Clinical Appearance**

Patients	Number of cases
Asymptomatic patients	42
Symptomatic patients.	36

**Table-4: Urological signs**

Signs	Number of cases	Percentage %
Frequent need to urinate	15	19,23
An urgent need to urinate	10	12,82
Difficulty starting to urinate or stopping urinating	4	5,12
An inability to urinate	1	1,28
A weak or reduced urine stream	2	2,56
A stream of urine that stops	1	1,28
Burning sensation or pain when urinating	3	3,84
The feeling of not having completely emptied your bladder	5	6,41



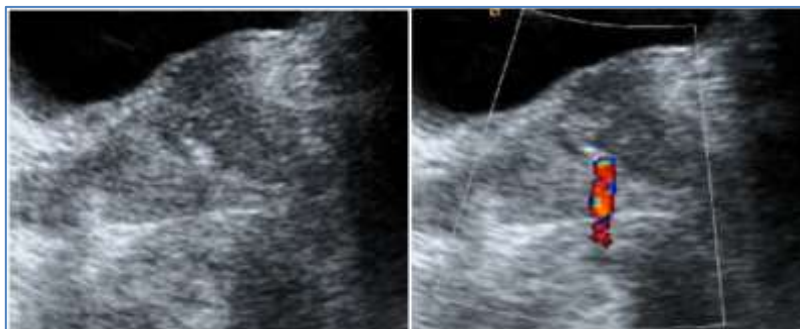**Fig-2: Urological signs**

**Table-5: ECBU results**

ECBU	Number of cases	Percentage %
Urinary tract infection	05	6,41
Sterile ECBU	73	93,58

**Table-6: Association with lithiasis of the urinary tract**

	Number of cases	Percentage %
Urinary tract lithiasis	03	3,84
No urinary tract stones	75	96,15

**Fig-2: Ultrasound appearance of prostatic calcifications.**

## DISCUSSION

Prostate calcifications are very common, their number and size increasing with age. Their association with prostate cancer is rare, and their discovery is likely accidental. Prostate calcifications are more common in men with chronic prostatitis [1]. The presence of prostatic calcifications also seems to increase the symptoms of the lower urinary tract in middle-aged men [2], regardless of the number, size or appearance of the stones [3]. These calcifications could potentially be used for localization of the prostate in radiotherapy on simple images without the invasive use of markers [4]. Their pathogenesis is controversial, either by progressive calcification of the starchy bodies existing in the prostate ducts, or by calcification of ductal ectasias secondary to infection.

Prostate imaging and in particular ultrasound can classify these calcifications into 3 categories:

- Punctiform of 1 mm with echogenic appearance, without posterior acoustic reinforcement, in connection with areas of sclerosis
- Small formation of about 2 mm, hyperechoic with posterior acoustic reinforcement, related to calcifications or real stones.
- Large formation, from a few mm to 1-2 cm, hyperechoic appearance, corresponding to large clusters of stones.

These calcifications are often visible in conventional radiology. MRI does not find any indication in the exploration of isolated calcifications of the prostate.

## CONCLUSION

The physiological importance of the prostate and the frequency of these pathologies with increasing age in men as well as the repercussions of prostate damage require close and regular monitoring, especially from the age of 50.

## Conflicts of interest

The authors declare that they have no conflict with this manuscript.

## REFERENCE

1. Shoskes, D. A., Lee, C. T., Murphy, D., Kefer, J. C., & Wood, H. M. (2007). 95: Incidence and Significance of Prostatic Stones in Men with Chronic Prostatitis/Chronic Pelvic Pain Syndrome. *The Journal of Urology*, 177(4S), 33-34.
2. Yang, H. J., Huang, K. H., Wang, C. W., Chang, H. C., & Yang, T. K. (2013). Prostate calcification worsens lower urinary tract symptoms in middle-aged men. *Urology*, 81(6), 1320-1324.
3. Hong, C. G., Yoon, B. I., Choe, H. S., Ha, U., Sohn, D. W., & Cho, Y. H. (2012). The prevalence and characteristic differences in prostatic calcification between health promotion center and urology department outpatients. *Korean journal of urology*, 53(5), 330-334.
4. Zeng, G. G., McGowan, T. S., Larsen, T. M., Bruce, L. M., Moran, N. K., Tsao, J. R., & MacPherson, M. S. (2008). Calcifications are potential surrogates for prostate localization in image-guided radiotherapy. *International Journal of Radiation Oncology\* Biology\* Physics*, 72(4), 963-966.