

Research Article

A Study of Fournier's Gangrene and its Management: Case Series of 35 Cases

Dr. Vijaykumar S Kappikeri¹, Dr. Yeshwanth V², Dr. Nitin Kalaskar^{3*}¹Professor and Head of Department, Department of General surgery, Basaveshwar Teaching and General Hospital, Mahadevappa Rampure Medical College, Kalaburagi Karnataka India²Junior Resident, Department of General Surgery, Basaveshwar Teaching and General Hospital, Mahadevappa Rampure Medical College, Kalaburagi Karnataka India³Associate professor, Department of General Surgery, Basaveshwar Teaching and General Hospital, Mahadevappa Rampure Medical College, Kalaburagi Karnataka India**Article History**

Received: 08.12.2020

Accepted: 24.12.2020

Published: 09.01.2021

Journal homepage:<https://www.easpublisher.com>**Quick Response Code**

Abstract: Fournier's gangrene is a necrotising fasciitis of the perineum due to synergistic infection. The aim of this study is to know the presentation and the predisposing factors of Fournier's gangrene and the various management modalities. This is a retrospective study over the period of 2 years from June 2018 to June 2020. In which there were a total of 35 patients included and were analysed for the age at presentation, duration of symptoms at presentation, associated co-morbidities, isolated organisms and the length of stay in the hospital. Most of the patient's age was above 50 years and had associated co-morbidities like diabetes mellitus. At presentation the patients were in SIRS and were subjected to immediate surgery followed by broad spectrum antibiotics and regular dressing. Once the wound was healthy either primary closure was done or skin grafting was done. Despite of advances in medical field the mortality remained pretty high in Fournier's gangrene cases.

Keywords: Fournier's gangrene, diabetes mellitus, surgical debridement, primary closure, skin grafting.

Copyright © 2021 The Author(s): This is an open-access article distributed under the terms of the Creative Commons Attribution 4.0 International License (CC BY-NC 4.0) which permits unrestricted use, distribution, and reproduction in any medium for non-commercial use provided the original author and source are credited.

INTRODUCTION

Fournier's gangrene is a rapidly progressive and potentially fatal condition. It is a type of necrotising fasciitis of the perineal and genital region due to rapidly progressive obliterative endarteritis of the subcutaneous arteries resulting in gangrene of the overlying skin. Fournier's gangrene usually affects male genitals but can also affect female and children [1]. In 1764, Baurienne originally described gangrene of male genitalia. However Jean-Alfred Fournier is more commonly credited for the disease for detailed description of the disease in 1883 as a fulminant gangrene of the penis and scrotum [2]. It is described with many terms including 'idiopathic gangrene of the scrotum', 'periurethral phlegmon', 'synergistic necrotizing cellulitis' [3, 4]. Fournier's gangrene usually manifests with severe intoxication with multiple organ failure [5] developing over a short duration of time. Surgical debridement with antibiotic therapy remains the main stay of treatment modality. Delay in treatment is accompanied by high mortality up to 80% due to development of septic shock and its associated complications [6]. The aim of our study is to identify the predisposing factors and management of the Fournier's gangrene.

METHODS AND METHODOLOGY

This is a retrospective study of the Fournier's gangrene cases presented to the department of surgery in Mahadevappa Rampure Medical College, Kalaburagi. The study period was from June 2018 to June 2020. We had a total of 35 cases included in the study. Patients presenting with necrotising fasciitis of the genitalia and perineum were included in the study and patients with perianal/ ischio rectal abscess were excluded from the study. Presenting symptoms included scrotal swelling, pain in scrotum, rapidly spreading cellulitis, fever and features of systemic toxicity. Debridement of the scrotum was done within 24 hrs of admission depending on the condition of the patient. Ultrasound abdomen and pelvis, ultrasonogram of scrotum were done in select patients to define the extent of the disease and to identify the source of infection. Routine haematological investigation including total count, differential counts, renal function tests and serum electrolytes were analysed. Antibiotics were modified according to the culture sensitivity report of the patients. Multiple debridements were done until a proper healthy granulation tissue was obtained and was closed by either primary closure or skin grafting.

RESULTS

Total of 35 patients were included in the study that were treated in department of general surgery, Mahadevappa Rampure Medical College, Kalaburagi. The highest incidence was found in the 7th decade of life, in a total of 15(42.85%) patient and mean age at presentation was 57.3 ± 15.87 years. The youngest patient was 20 years old and the maximum age was 85 years. The mean age of presentation for the deceased is 48.42 ± 10.40 years. Diabetes mellitus formed the most common co-morbid condition in 14(40%) patients, followed by alcoholism in 13(37.14%) patients.

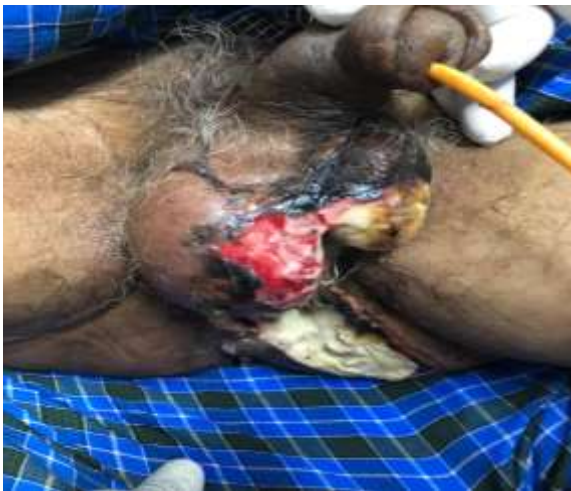

Fig-1: Fournier's gangrene of left hemi scrotum

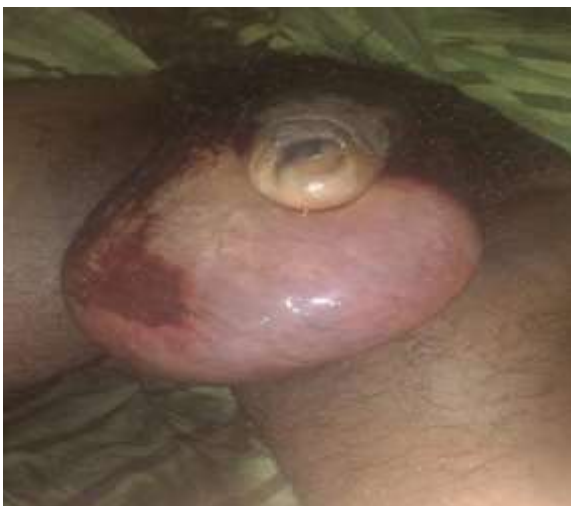

Fig-2: Fournier's gangrene of scrotum with involvement of the full circumference of penis

Most commonly the disease is polymicrobial and included staphylococcus aureus and Escherichia coli organisms as the most common cause. Multiple debridements were required in patients and regular dressing was done after wash with betadine and normal saline.

Table-1: Clinical features at presentation

Clinical features	Number of patients	Percentage
Pain	35	100
Swelling	34	97.14
Fever	22	62.85
Discharge	14	40.00
Others (breathlessness, maggots, stroke)	5	14.28

Table-2: Associated co-morbidities

Co-morbidities	Number of patients	Percentage
Diabetes mellitus	14	40
Alcoholism	13	37.14
Hyper tension	5	14.28
Tobacco	10	28.57
Others (copd, stroke, tb)	6	17.142

Table-3: Most common organisms isolated from Culture and Sensitivity

Isolated organism	Total number of patients	Percentage
Staphylococcus. Aureus	17	30.90
Escherichia coli	15	27.27
Klebsiella. Pneumoniae	12	21.81
Pseudomonas aeruginosa	5	09.10
Acinetobacter	3	05.46
Others	3	05.46

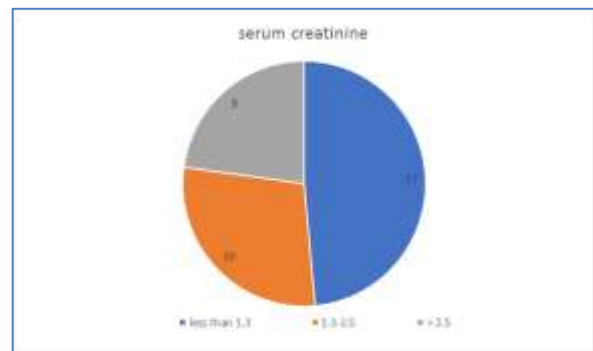


Chart-1: Serum Creatinine levels in the affected patients

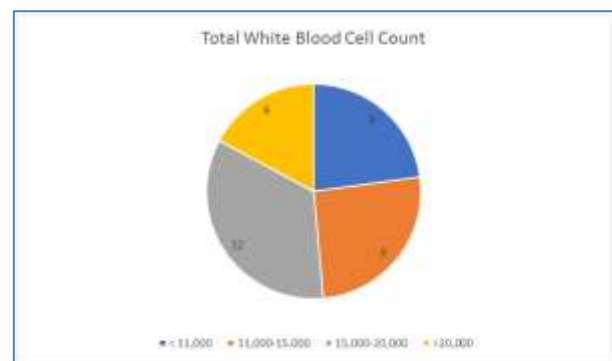


Chart-2: Total White Blood Cell Count in the affected patients

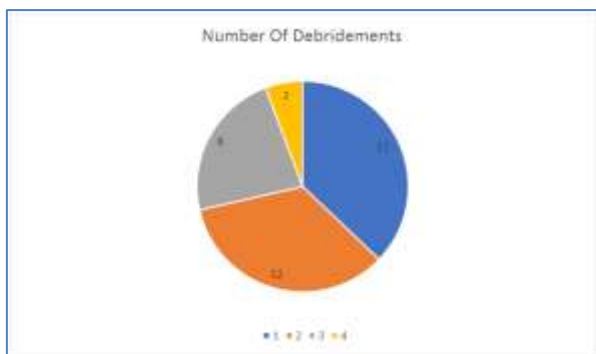


Chart-3: Number of Debridement's on each patient

In our study in 13 patient's single debridement was done, while 2 patients required more than 4 debridement's. Primary closure was possible in 16 of the patients while skin grafting was done in 4 cases and in 2 cases testis was placed in thigh pouch and skin closure done. While 6 patients went DAMA and wanted only regular dressing and follow up. In our study mortality was associated with 7 patients (20%).

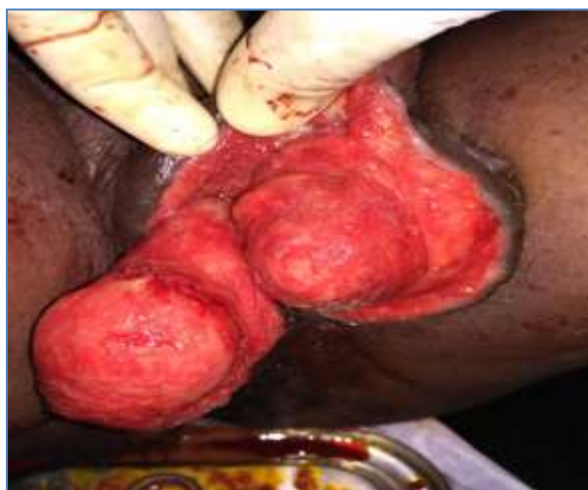

Fig-3: Fournier's gangrene post debridement (3rd) with healthy granulation tissue

Table-4: Surgical Management Modalities in various patients

Final surgery	Number of cases	Percentage
Primary skin closure	16	57.14
Skin grafting	4	14.29
Thigh pouch with primary closure	2	07.14
Regular dressing	6	21.43
Total	28	100

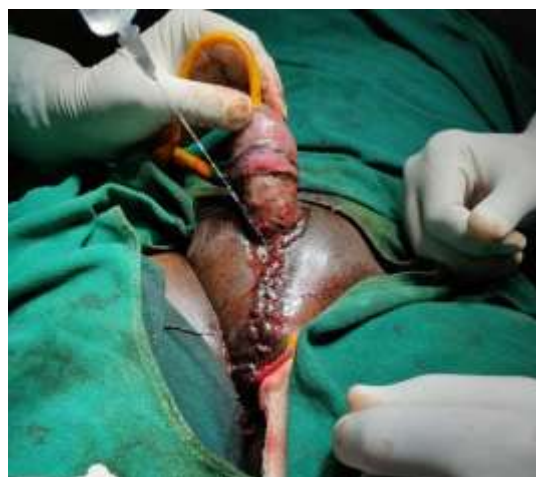

Fig-4: post op image with penile skin grafting and closure of testis with scrotal skin

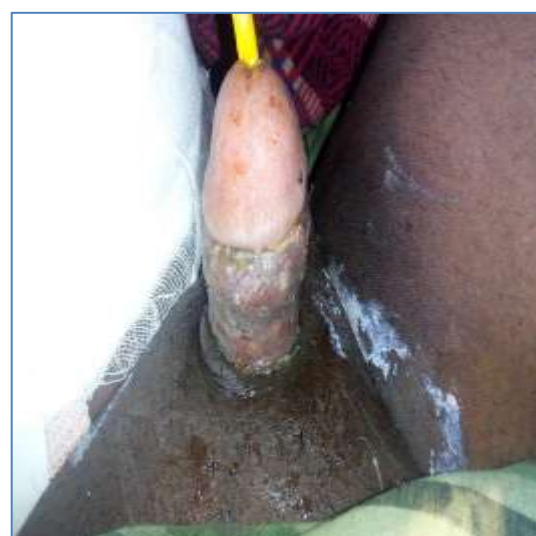

Fig-5: Post op day 7 image showing skin graft being taken up.

DISCUSSION

Fournier's gangrene is a rare disorder that commonly affects the perineum and genitals in male patients it can also affect female patients. In a study by Eke *et al.* male to female ratio was 10:1[7] even though in our series there were no female cases. It commonly affects the immunocompromised patients [8, 9].

In most of the previous studies it was noted that diabetes mellitus formed the most common co-morbid condition as a predisposing factor [10], similar results were obtained in our study where diabetes mellitus was present in 14(40%) patients followed by alcoholism in 13(37.14%) patients, Which was in close relation of being most commonly associated with Fournier's gangrene as in the study by Smith *et al.* [1]. Fournier's gangrene is believed to be polymicrobial in origin. Hejase *et al.* and ferreria *et al.* had a polymicrobial isolation in 90% and 82.9% of cases respectively [7, 11]. In our present study polymicrobial infection was found in 22(62.85%) patients. The average number of organisms isolated were 2, which

was in similar range with various studies showing 2-3 organisms [12].

In a study of 43 patients by Ferreria *et al.* single debridement was sufficient in 35 patients, 7 patients were debrided twice while 1 patient was debrided thrice [7]. But contrastingly in a study by Chawla *et al.* the average number of debridement's was 3.5 per patient [13]. In our study the average debridement per patient was 2.02.

In our study group the patient who presented within 5 days of onset of symptoms had a normal white blood cell count and renal function test. While if the patient presented late both these parameters were deranged which showed in the increase in the total white cell count and a deranged renal function. Both these were essential at time of admission to access the condition of the patient and the average duration of stay and prognosis.

If left untreated the mortality with Fournier's gangrene is reported to be 100% [14]. Emergency debridement of the septic foci is of paramount importance. In our study all the patients were subjected to emergency debridement within 12 hours of admission and the reconstructive procedure was done after the acute phase has subsided and there was a healthy granulation tissue and the patient was hemodynamically stable. In our series primary closure of the defect with scrotal skin was done in 14 patients, while split thickness skin grafting was done in 4 patients and testis being placed in the thigh pouch was done in 2 patients while in rest regular dressing was all that was needed. Skin grafting was done only in cases that involved the whole circumference of the penis with loss of the penile skin. While some studies advice reconstructive procedures at the same admission. The mortality rate in our study was 20% that is 7 patients that were included in the study.

CONCLUSION

Fournier's gangrene is a rare necrotising fasciitis of the genital region affecting males predominantly. It is most commonly associated with immunocompromised patients and elderly suffering from diabetes mellitus, chronic alcoholism. *Escherichia coli* and *staphylococcus* formed the most common group of organisms that were isolated from the culture and sensitivity of the affected part. Most of the patients if presented early would have a normal total white cell count and renal function tests, but in delayed presentation both are deranged. Emergency debridement at the earliest with the use of IV antibiotics is the main stay of treatment. While simple

reconstruction is enough in patients with early presentation, few cases will need skin grafting or complex reconstructive procedure. Even though the advances in the management of Fournier's gangrene, the mortality remains pretty high.

REFERENCES

1. Smith, G. L., Bunker, C. B., & Dinneen, M. D. (1998). Fournier's gangrene. *British journal of urology*, 81, 347-355.
2. Fournier, J. (1883). Gangrene foudroyante de la verge. *Semaine Medicale*, 3: 345-348.
3. Meleney, F. (1924). Hemolytic streptococcus gangrene. *Arch Surg*, 9: 317-364.
4. Shyam, D., & Rapsang, A. (2013). Fournier's gangrene. *Surgeon*, 11: 222-232.
5. Aliev, S.A., Rafiev, S.F., Rafiev, F.S., Aliev, E.S. (2008). Fournier's disease in surgeon practice. *Surgery J n.a. N.I.Pirogov*; 11: 58-63.
6. Morpurgo, E., & Galandiuk, S. (2002). Fournier's gangrene. *Surg Clin North Am* 82: 1213-1224.
7. EkeN. Fournier's gangrene: a review of 1726 cases. *Br J Surg*, 87(6): 718-728.
8. Milović, N., Bancević, V., Campara, Z., Kosević, B., Zoranović, U. (2008). Fournier's gangrene. *Vojnosanit Pregl*, 77 Oct;65(10):775-8.
9. Chen, Y., Wang, X., Lin, G., & Xiao, R. (2018). Successful treatment following early recognition of a case of Fournier's scrotal gangrene after a perianal abscess debridement: a case report. *Journal of medical case reports*, 12(1), 193.
10. Norton, K. S., Johnson, L. W., Perry, T., & Perry, K. H. (2002). Management of Fournier's gangrene: an eleven year retrospective analysis of early recognition, diagnosis, and treatment. *The American Surgeon*, 68(8), 709.
11. Tahmaz, L., Erdemir, F., Kibar, Y., Cosar, A., & YalcYN, O. (2006). Fournier's gangrene: Report of thirty-three cases and a review of the literature. *International journal of urology*, 13(7), 960-967.
12. Thwaini, A., Khan, A., Malik, A., Cherian, J., Barua, J., Shergill, I., & Mammen, K. (2006). Fournier's gangrene and its emergency management. *Postgraduate medical journal*, 82(970), 516-519.
13. Chawla, S. N., Gallop, C., & Mydlo, J. H. (2003). Fournier's gangrene: an analysis of repeated surgical debridement. *European urology*, 43(5), 572-575.
14. Hasdemir, A. O., Büyükaşık, O., & Çöl, C. (2009). The clinical characteristics of female patients with Fournier's gangrene. *International Urogynecology Journal*, 20(12), 1439-1443.

Cite this article:

Vijaykumar S Kappikeri *et al* (2021). A Study of Fournier's Gangrene and its Management: Case Series of 35 Cases. *East African Scholars J Med Surg*, 3(1), 1-4.