

Research Article

Short Term Outcome of Closed Intramedullary Fixation with Titanium Elastic Nail in Displaced Femoral Shaft Fractures in Skeletally Immature Children

Md. Munzur Rahman^{1*}, Md. Moshidur Rahman¹, Dr. Obaidul Haque¹, Mirza Osman Beg²

¹Assistant Professor, Department of Orthopaedic Surgery, Rajshahi Medical College, Rajshahi, Bangladesh

²Associate Professor, Department of Orthopaedic Surgery, North East Medical College, Sylhet, Bangladesh

Article History

Received: 25.01.2021

Accepted: 12.02.2021

Published: 16.02.2021

Journal homepage:

<https://www.easpublisher.com>

Quick Response Code



Abstract: **Introduction:** Femoral shaft fractures are most common fractures in paediatric age group having different options to treat them. Elastic stable intramedullary nailing is one for treating these fractures and has a reliable methodology. **Objective:** The aim of this study is to evaluate the Short Term Outcome of Closed Intramedullary Fixation with Titanium Elastic Nail in Displaced Femoral Shaft Fractures in Skeletally Immature Children. **Material and Methods:** 36 femoral shaft fractures in 36 children aged 6-14 years were fixed with titanium intramedullary elastic nail between July 2017 and December 2018 in the department of Orthopaedics, Rajshahi Medical College Hospital & Royal Hospital Ptv. Ltd. Rajshahi, Bangladesh. **Results:** All patients achieved complete healing at a mean of 9.1 (Range 810) weeks. 31 fractures were reduced by closed means but 5 needed open reduction. No major complication was recorded. Most common minor complication was entry site skin irritation recorded in 4 patients. 86% had excellent result and 14% had satisfactory. **Conclusion:** Elastic stable intramedullary nailing is the method of choice for the femoral shaft fractures in paediatric patients, because it is minimally invasive and shows very good functional and cosmetic result. It allows early ambulation and shorter hospital stay and higher parent satisfaction. It also provides flexural, translational and rotational stability as well.

Keywords: Elastic stable intramedullary nailing (ESIN), Titanium elastic nail (TEN), Femoral shaft fracture.

Copyright © 2021 The Author(s): This is an open-access article distributed under the terms of the Creative Commons Attribution **4.0 International License (CC BY-NC 4.0)** which permits unrestricted use, distribution, and reproduction in any medium for non-commercial use provided the original author and source are credited.

INTRODUCTION

Paediatric Femur fracture is among the most common and most disabling injuries in childhood. Many treatment options are reported for school age children [1, 2]. The treatment options for preschool femur fractures include immediate [3] or delayed spica cast immobilization [4], skin or skeletal traction on a splint [5], plating [6], elastic nail [4], and external fixators. Most of the femoral shaft fractures in children younger than six years of age can be managed with the traditional conservative methods due to high potential of healing [7, 8]. However above six years of age, non-operative management of such fractures may have complications such as loss of reduction, malalignment, malunion, plaster associated problems, intolerance and school absenteeism. These demerits lead to increasing trend towards operative procedures that permit rapid mobilization in children over six years of age [9-11]. Reeves *et al.*, reported that the cost of non-operative treatment is 40% higher than operative treatment [12]. Titanium Elastic Nailing, also known as Elastic Stable Intramedullary Nailing, has become the choice of

surgical procedure in pediatric femoral shaft fractures because of the various advantages such as early union due to repeated micromotion at the fracture site, less chance of physeal damage, early mobilization, early weight bearing, small scar and better patient compliance [13-15].

MATERIALS AND METHODS

The study group consisted 36 children (26 males, 10 females) having age between 6-14 years with fresh femoral shaft fractures which were fixed with Titanium Elastic Nail (TEN), between July 2017 and December 2018 in the department of Orthopaedics, Rajshahi Medical College Hospital & Royal Hospital Ptv. Ltd. Rajshahi, Bangladesh. No control group was used.

Inclusion Criteria

- Age group between 6-14years.
- Displaced fracture, with or without comminution.
- Multiple fractures.
- Closed fractures.

Exclusion Criteria

- Children <6 and >14 yrs of age.
- Metaphyseal fractures.
- Undisplaced fractures.
- Open fractures.
- Pathological fractures.

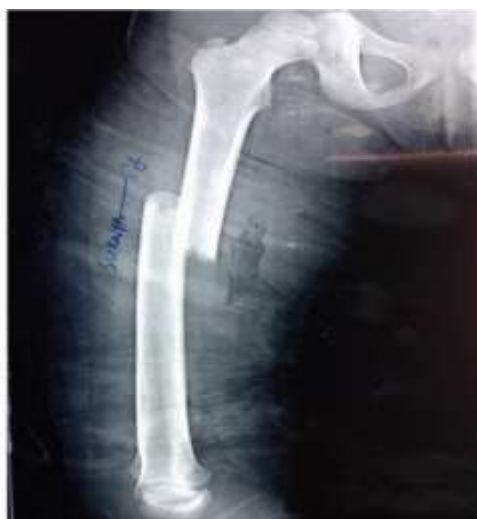The mean age was 9.44 (range 6-14) years and the right side was more commonly involved than the left. The predominant mode of injury was due to road traffic accident (n = 20, 56%) followed by fall from height (n = 16, 44%). Pre-operative evaluation included full length radiograph of the involved thigh including knee and hip joint (both anteroposterior and lateral views) (Pic-1). The locations of fractures in this study group were as follows: 3 fractures were in proximal third, 29 in middle third and 4 in distal third of femur. Subtrochanteric and supracondylar femur fractures were excluded from the study. 28 fractures were transverse, 6 were short oblique, 2 were spiral and of these 8 were minimally comminuted (Winquist-1).

Operative Technique

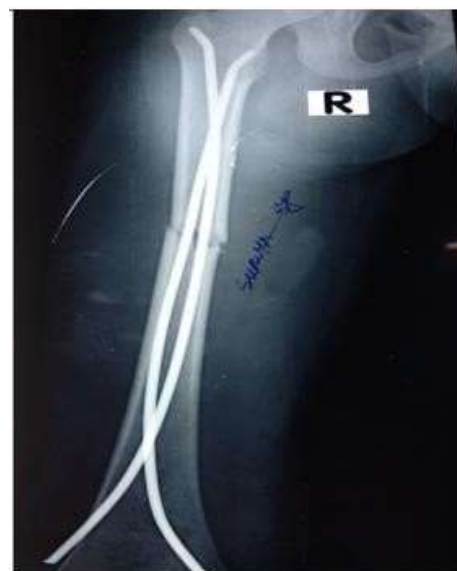The surgeries were performed under general anesthesia with the patients in supine position with the help of image intensifier. Two Titanium Elastic Nails of identical diameter were used and the diameter of the individual nail was selected as per Flynn *et al*'s formula¹⁶ (Diameter of nail = Width of the narrowest point of the medullary canal on anteroposterior and lateral view \times 0.4 mm). Its length was selected on the basis of pre-operative radiograph of known magnification, and confirmed on the limb before insertion. The nails were inserted in retrograde fashion with medial and lateral incisions 2-3 cm above the physis. The nails were prebent sufficiently so that apex of the bowed nails rested at the same level on the fracture site to ensure a good equal recoil force. Under image intensifier, the cortex was breached with an awl or drill according to individual. TENs of proper diameter and length tapped along the medulla with the tip angled away from the cortex. The temptation to rotate the nail clock or counterclockwise was resisted. The fracture was reduced by manipulation and the nail advanced across the fracture site. Insertion of the later nail was done in a similar fashion but from the opposite side of the bone. All nails were inserted up to the fracture site, starting at the distal fragment in retrograde fashion then the fracture reduced, and the nails tapped across the fracture site in an alternating manner for perhaps 1 to 2 cm into the proximal segment. All nails were then knocked home, leaving sufficient nail exposed at the site of insertion to enable subsequent removal. Open reduction was required in five cases due to soft tissue interposition. The nails were advanced proximally so that both were divergent and the tips got anchored minimum 1 cm distal to the physis.

Post-Operative Rehabilitation:

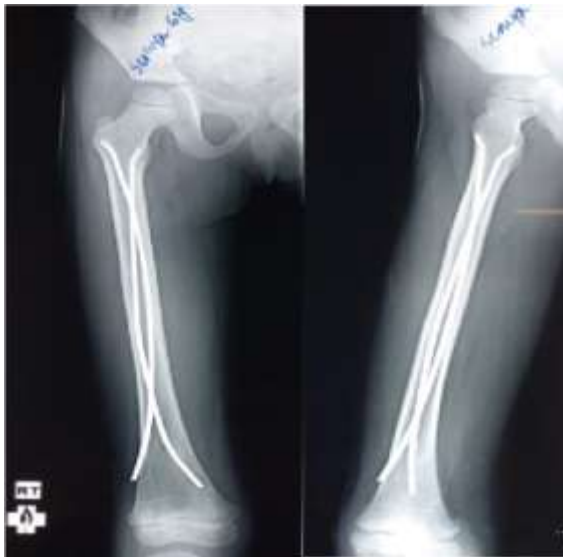No external splints were used. Postoperatively patient's limb was elevated on a pillow. Patients were mobilized without weight bearing on the eighth to tenth day postoperatively. Partial weight bearing was started at around four weeks and full weight bearing by eight weeks depending on the fracture anatomy, quality of reduction, callus response and associated injuries. All patients were followed up radiologically as well as clinically every 6 weeks for first 12 weeks, then once every 3 months (Pic 2 & 3). Parameters studied were clinical and radiological features of union, malalignment, range of motion of the knee of the affected side, limb length discrepancy and any other complications found during the study.



Pic-1



Pic-2



Pic-3

The study group consisted 36 children (26 males, 10 females) having age between 6-14 years with fresh femoral shaft fractures which were fixed with Titanium Elastic Nail (TEN) (Figure-1). All patients achieved complete healing at a mean of 9.1 (Range 8-10) weeks. 31 fractures were reduced by closed means but 5 needed open reduction. No major complication was recorded. Most common minor complication was entry site skin irritation recorded in 4 patients. 86% had excellent result and 14% had satisfactory. The results were evaluated using Flynn *et al.*,’s scoring criteria for TENS (Table-1). The mean duration of surgery was 38 (range 30- 45) minutes. The size of nail varied from 2-4 mm. The mean duration of hospital stay was 8.16 (range 7-12) days. Apart from the adequacy of fixation, the hospital stay also depended upon the associated injuries. All the 36 patients were available for evaluation after a mean duration of follow up for 70 weeks.

RESULTS

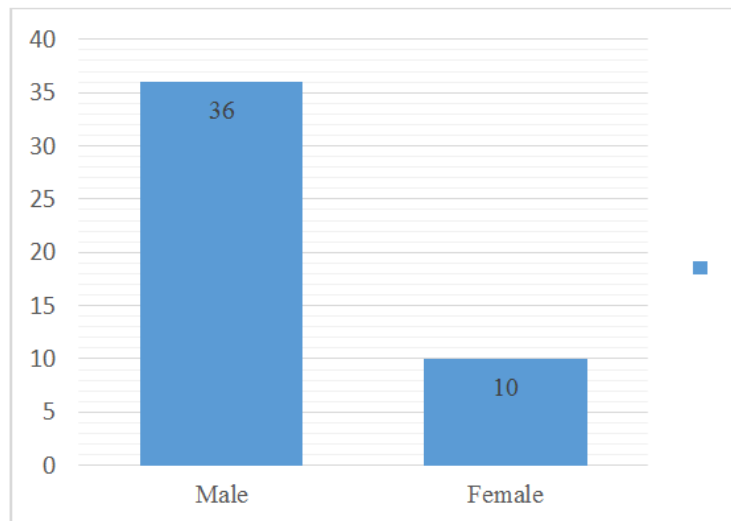


Fig-1: Sex distribution of Patients

Table-1: Flynn *et al.*,’s Scoring Criteria for TENS and present study result (N=36)

	Excellent	Satisfactory	Poor
Pain	None	None	Present
Malalignment	<5 ⁰	5-5-10 ⁰	>10 ⁰
Limb Length Discrepancy	<1 cm	1-2cm	>2cm
Complication	None	Minor	Major and/or lasting morbidity
No. patients (n=36)	n=31	n=5	n=0

Table-2: Complications in the Study (N=36)

Complications	No. of cases (n=36)
Entry site irritation/ bursitis	4
Superficial infection	2
Deep infection	0
Limb length discrepancy (up to 2 cm)	5

The mean time of the union was 7.9 (range 7-9) weeks. Full weight bearing was possible in a mean time of 8.6 (range 7-10) weeks. All the patients achieved full range of motion by an average of 9.6 (range 8-11) weeks. None of the patients developed any angular deformity of greater than five degrees. Limb length discrepancy of less than 2 cm was found in 5 cases, which was clinically insignificant (Table-2). Four patients developed bursitis at the entry point due to friction caused by cut ends of the nail and two patients developed superficial infection at the nail entry site (Table-2) which resolved within seven days of oral course of antibiotics. None of the cases developed any deep infection, joint penetration by nail, nail breakage and implant failure, iatrogenic fracture, nonunion or any neurovascular complications. The nails were removed after an average of 47 (range 42-54) weeks. No complication was associated with the nail removal procedure and no refracture was observed after nail removal till the last follow up.

DISCUSSION

The management of femoral shaft fractures in pediatric age group especially in 6 to 14 years age group has been controversial and the choice of treatment still remains a constant challenge to the orthopedic surgeons. The results were excellent in 31 patients (86%), satisfactory in 5 (14%) and poor in none of the patients as per the scoring criteria for TENS by Flynn *et al.*, [17]. The age old conservative method had been the treatment of choice for pediatric femur shaft fracture, but the union was usually achieved at the expense of extended period of immobilization, delayed mobilization, loss of school attendance, intolerance and prolonged hospital stay [18-20]. However, to overcome these problems in this age group, the operative approach has been gaining popularity for last two decades [21]. There are multiple options for operative fixation of these fractures such as external fixators, flexible and locked intramedullary nails, and compression plating [22]. Compression plating is widely used but has the disadvantages of larger soft tissue dissection, a large scar, increased risk of infection, delayed weight bearing and a second major operation for implant removal [23]. External fixation has been associated with problems of pin track infection and refractures through the pin tracks, but has advantage of good stability and early mobilization [24, 25]. Rigid intramedullary nailing is ideal for skeletally mature patient, but when introduced in skeletally immature child, it has been associated with problems of physeal damage, coxa valga, and avascular necrosis of the femoral head and growth disturbances [26, 27]. Titanium Elastic Nailing System (TENS) is a flexible intramedullary nail which is a load sharing implant, acts as an internal splint, and maintains length and alignment. It has a unique advantage of providing micro motion at the fracture site due to the elasticity of the fixation, which helps in rapid development of bridging

callus, early mobilization and early weight bearing. Further, being a closed procedure there is no disturbance of periosteum or fracture hematoma, thereby less risk of infection and nonunion. It also combines the advantages of titanium such as more strength, light weight, corrosion resistance and MRI compatibility. Ligier *et al.*, had highlighted the beneficial use of titanium elastic nails in the treatment of femur fractures in children for the first time [28]. Of his study population none of the patients complained of disability and no gait abnormalities were observed at one year of follow-up. Flynn *et al.*, studied the outcomes of 49 fractures treated with TENS and found no malalignment, angulation or limb length discrepancy of more than 1 cm but reported 8 cases of nail-tip irritation near the insertion site and had found TENS to be advantageous over hip spica in treatment of femoral shaft fractures in children [29]. An important factor in the management of paediatric femoral shaft fractures is fracture geometry. Titanium elastic nail is not capable of providing adequate stability in comminuted, long oblique or spiral fractures and some other alternative apart from TENS should be considered in such cases [17]. Lascombes *et al.*, reported that all femoral diaphyseal fractures except severe Type III open fractures could be fixed with TENS in children above six years of age [30]. We have conducted a prospective study on 36 patients focusing on the outcomes of fracture shaft femur in age group 6-14 year old children. All the fractures united with the mean duration of 7.9 weeks, which is comparable to the various studies in the literature. The mean time from surgery to full weight bearing was 8.6 weeks. All the patients achieved full range of motion by 9.6 weeks. The results were analyzed as per the scoring criteria by Flynn *et al.*, [17] which showed excellent results in 31 patients, satisfactory in 5 and none of the patients fell into poor category. The most common complication of Titanium elastic nail is entry site irritation and pain [17]. Other complications included limb length discrepancy, angulation of fracture, refractures and infection. In our study, 4 patients developed bursitis or entry site irritation due to friction by the cut ends of the nail. Two patients developed superficial infection which resolved with oral antibiotics. This complication was observed in the initial part of the study after which we rounded the sharp edges of the nail end. None of the patients developed angular deformity of greater than five degrees. Limb length discrepancy of less than 2 cm was found in five cases, which was clinically insignificant. However, the cases are being followed up further for a possible limb length discrepancy that may develop in future. The mean duration of follow up in our study is 64 weeks and this is the limitation of our study. There was no case lost to follow up as most of the cases were from the nearby village area has been the strength of our study.

CONCLUSION

Titanium elastic nailing seems to be more physiological and effective method of treatment of femoral shaft fractures in 6-14 years old children. It is simple, rapid and safe procedure with advantages of early union, early mobilization and early return to function with minimal complications.

REFERENCES

1. Reinberg, O., Frey, P., & Meyrat, B. J. (1994). Treatment of pediatric fractures by intramedullary stable elastic pinning. *Zeitschrift für Unfallchirurgie und Versicherungsmedizin: Offizielles Organ der Schweizerischen Gesellschaft für Unfallmedizin und Berufskrankheiten= Revue de Traumatologie et D'assurologie: Organe Officiel de la Societe Suisse de...*, 87(2), 110-8.
2. Wright, J. G. (2000). The treatment of femoral shaft fractures in children: a systematic overview and critical appraisal of the literature. *Canadian Journal of Surgery*, 43(3), 180-189.
3. Allen Jr, B. L., Schoch 3rd, E. P., & Emery, F. E. (1978). Immediate spica cast system for femoral shaft fractures in infants and children. *Southern medical journal*, 71(1), 18-22.
4. Wainwright, A. M., & Narayanan, U. G. (2007). A new technique for reduction of paediatric femoral fractures using elastic stable intramedullary nails. *The Annals of The Royal College of Surgeons of England*, 89(4), 432-434.
5. Ali, M., & Raza, A. (2005). Union and complications after Thomas splint and early hip spica for femoral shaft fractures in children. *Journal of the College of Physicians and Surgeons--pakistan: JCPSP*, 15(12), 799-801.
6. Kanlic, E. M., Anglen, J. O., Smith, D. G., Morgan, S. J., & Pesántez, R. F. (2004). Advantages of submuscular bridge plating for complex pediatric femur fractures. *Clinical Orthopaedics and Related Research®*, 426, 244-251.
7. Buckley, S. L. (1997). Current trends in the treatment of femoral shaft fractures in children and adolescents. *Clinical Orthopaedics and Related Research®*, 338, 60-73.
8. Gwyn, D. T., Olney, B. W., Dart, B. R., & Czuwala, P. J. (2004). Rotational control of various pediatric femur fractures stabilized with titanium elastic intramedullary nails. *Journal of Pediatric Orthopaedics*, 24(2), 172-177.
9. Canale, S. T., Tennessee, M., & Tolo, V. T. (1995). Fractures of the femur in children. *JBJS*, 77(2), 294-315.
10. Narayanan, U. G., Hyman, J. E., Wainwright, A. M., Rang, M., & Alman, B. A. (2004). Complications of elastic stable intramedullary nail fixation of pediatric femoral fractures, and how to avoid them. *Journal of pediatric orthopaedics*, 24(4), 363-369.
11. Metaizeau, J. P. (2004). Stable elastic intramedullary nailing for fractures of the femur in children. *The Journal of bone and joint surgery. British volume*, 86(7), 954-957.
12. Reeves, R. B. (1990). Internal fixation versus traction and casting of adolescent femoral shaft fracture. *Journal Pediatr Orthop*. 19:551.
13. Flynn, J. M., Skaggs, D. L., Sponseller, P. D., Ganley, T. J., Kay, R. M., & Leitch, K. K. (2003). The surgical management of pediatric fractures of the lower extremity. *Instructional course lectures*, 52, 647-659.
14. Bhaskar, A. (2005). Treatment of long bone fractures in children by flexible titanium elastic nails. *Indian Journal of Orthopaedics*, 39(3), 166-168.
15. Sanders, J. O., Browne, R. H., Mooney, J. F., Raney, E. M., Horn, B. D., Anderson, D. J., ... & Robertson, W. W. (2001). Treatment of femoral fractures in children by pediatric orthopedists: results of a 1998 survey. *Journal of Pediatric Orthopaedics*, 21(4), 436-441.
16. Flynn, J. M., Skaggs, D. L., Sponseller, P. D., Ganley, T. J., Kay, R. M., & Leitch, K. K. (2003). The surgical management of pediatric fractures of the lower extremity. *Instructional course lectures*, 52, 647-659.
17. Flynn, J. M., Hresko, T., Reynolds, R. A., Blasler, R. D., Davidson, R., & Kasser, J. (2001). Titanium elastic nails for pediatric femur fractures: a multicenter study of early results with analysis of complications. *Journal of Pediatric Orthopaedics*, 21(1), 4-8.
18. Salem, K. H., Lindemann, I., & Keppler, P. (2006). Flexible intramedullary nailing in pediatric lower limb fractures. *Journal of Pediatric Orthopaedics*, 26(4), 505-509.
19. Beaty, J. H., & Kasser, J. R. (2001). Femoral shaft fractures. Rockwood and Wilkins' fractures in children. Sixth ed. Philadelphia: Lippincott, Williams & Wilkins: 893-936.
20. Carey, T. P., & Galpin, R. D. (1996). Flexible intramedullary nail fixation of pediatric femoral fractures. *Clinical Orthopaedics and Related Research®*, 332, 110-118.
21. Saikia, K. C., Bhuyan, S. K., Bhattacharya, T. D., & Saikia, S. P. (2007). Titanium elastic nailing in femoral diaphyseal fractures of children in 6-16 years of age. *Indian journal of orthopaedics*, 41(4), 381-385.
22. Beaty, J. H. (2005). Operative treatment of femoral shaft fractures in children and adolescents. *Clinical Orthopaedics and Related Research (1976-2007)*, 434, 114-122.
23. Hansen, T. B. (1992). Fractures of the femoral shaft in children treated with an AO-compression plate: Report of 12 cases followed until

- adulthood. *Acta Orthopaedica Scandinavica*, 63(1), 50-52.
24. Aronson, J., & Tursky, E. A. (1992). External fixation of femur fractures in children. *Journal of pediatric orthopedics*, 12(2), 157-163.
25. Krettek, C., Haas, N., Walker, J., & Tscherne, H. (1991). Treatment of femoral shaft fractures in children by external fixation. *Injury*, 22(4), 263-266.
26. Beaty, J. H., Austin, S. M., Warner, W. C., Canale, S. T., & Nichols, L. (1994). Interlocking intramedullary nailing of femoral-shaft fractures in adolescents: preliminary results and complications. *Journal of pediatric orthopedics*, 14(2), 178-183.
27. Letts, M., Jarvis, J., Lawton, L., & Davidson, D. (2002). Complications of rigid intramedullary rodding of femoral shaft fractures in children. *Journal of Trauma and Acute Care Surgery*, 52(3), 504-516.
28. Ligier, J. N., Metaizeau, J. P., Prévot, J., & Lascombes, P. (1988). Elastic stable intramedullary nailing of femoral shaft fractures in children. *The Journal of bone and joint surgery. British volume*, 70(1), 74-77.
29. Flynn, J. M., Luedtke, L. M., Ganley, T. J., Dawson, J., Davidson, R. S., Dormans, J. P., ... & Drummond, D. S. (2004). Comparison of titanium elastic nails with traction and a spica cast to treat femoral fractures in children. *JBJS*, 86(4), 770-777.
30. Lascombes, P., Haumont, T., & Journeau, P. (2006). Use and abuse of flexible intramedullary nailing in children and adolescents. *Journal of Pediatric Orthopaedics*, 26(6), 827-834.

CITATION: Munzur Rahman *et al* (2021). Short Term Outcome of Closed Intramedullary Fixation with Titanium Elastic Nail in Displaced Femoral Shaft Fractures in Skeletally Immature Children. *EAS J Orthop Physiother*, 3(1): 6-11.