

Research Article

Outcome of Surgical Management of Unstable Dorso-Lumbar Spine Injuries with Transpedicular Screws and Rods Fixation with Posterior Decompression

Md. Munzur Rahman^{1*}, Md. Shah Alam²¹Assistant Professor, Department of Orthopaedic Surgery, Rajshahi Medical College, Rajshahi, Bangladesh²Professor & Head, Department of Orthopaedic Surgery, Dhaka Medical College Hospital, Dhaka, Bangladesh**Article History**

Received: 25.01.2021

Accepted: 14.02.2021

Published: 17.02.2021

Journal homepage:<https://www.easpublisher.com>**Quick Response Code**

Abstract: Background: Dorsolumbar trauma is the most common cause of paraparesis or paraplegia. Optimal goals of the management include establishment of a painless, balanced and stable spinal column with vertebral fusion. One of the general cause of Paraplegia is Dorsal-lumbar spine injury where damage to the dorsal- lumbar spinal cord that causes temporary or permanent changes in its function. **Objective:** The aim of our study is to evaluate Outcome of Surgical Management of Unstable Dorso-Lumbar Spine Injuries with Transpedicular Screws and Rods Fixation with Posterior Decompression. **Method:** This observational descriptive study was conducted at Rajshahi Medical College Hospital, Rajshahi, Bangladesh from January 2017 to January 2019 where 59 cases was observed and clinically Patients were graded using Frankel classification of neurological deficits pre-and postoperatively. **Results:** In this result injury where most of the patients face fall of height and D12 vertebra was fractured in 20 cases. Also Majority of the patients belonged to frankel grade A (71.18%). **Conclusion:** After much analysis we can conclude that this rapid surgical management is safe and helps in early.

Keywords: Paraplegia, Dorsal-Lumbar Spine Injury, Thoracic and Lumbar.

Copyright © 2021 The Author(s): This is an open-access article distributed under the terms of the Creative Commons Attribution **4.0 International License (CC BY-NC 4.0)** which permits unrestricted use, distribution, and reproduction in any medium for non-commercial use provided the original author and source are credited.

INTRODUCTION

Spinal column injuries represent around 3% of all trauma cases and 90% of these injuries involve the thoraco-lumbar region [1-5]. The thoraco-lumbar segment of spine (D10 to L2) is an unstable zone between fixed dorsal and mobile lumbar spine and an acute injury to this segment is the second most frequent site after cervical spine injury in adults. Trauma to the thoracic and lumbar vertebra is one of the most collective cause of traumatic paraparesis or paraplegia. These can occur with or without bowel bladder involvement. Dorsolumbar fractures frequently cause a neurologic deficit and present a significant economic burden to the family and civilization. Recognized methods of treatment of dorsolumbar burst fractures include conservative therapy, posterior reduction and instrumentation, and anterior decompression and instrumentation. Early mobilization and rehabilitation is the most important aim of the management. Majority of the dorsolumbar fractures are unstable [1, 2]. Trauma to the thoracic and lumbar vertebra is one of the most collective cause of traumatic paraparesis or paraplegia. These can occur with or without bowel bladder involvement. Dorsolumbar fractures frequently cause a neurologic deficit and present a significant economic

burden to the family and civilization. Recognized methods of treatment of dorsolumbar burst fractures include conservative therapy, posterior reduction and instrumentation, and anterior decompression and instrumentation. Majority of the dorsolumbar fractures are unstable. Thoraco-lumbar burst fractures occurs as a result of axial load on the spinal column after trauma which often causes displacement of the middle column into the vertebral canal and reduces the diameter. This retropulsion bone fragment is unstable and can be the cause of neural injury. The injury, although not associated with high mortality, causes severe morbidity. It is mobilization and rehabilitation, thus facilitating possible neurological recovery and achieving a betterment of life. Estimated that approximately 75% of patients with thoraco-lumbar injuries sustain some degree of neurological deficit. Though these types of injuries are best treated by vertebral column decompression and stabilization, management plan differs between many of the researchers regarding operative and non-operative method.³ In this study our main objective is to evaluate the management of traumatic unstable Dorsal-lumbar spine injuries with transpedicular screw and rod fixation.

OBJECTIVES

General Objective

- To assess the Outcome of Surgical Management of Unstable Dorso-Lumbar Spine Injuries with Transpedicular Screws and Rods Fixation with Posterior Decompression.

Specific Objectives

- To detect types of injury of the patients.
- To identify correlation of prognosis with Frankel grade on admission.

MATERIALS AND METHODS

The present study was conducted using a cohort of 200 subjects. This study was conducted for 3 months duration in the Department of Orthopaedic Surgery, Rajshahi Medical College Hospital, Rajshahi, Bangladesh. The study included subjects between 20-60 years of age and out of 200 subjects, 100 were obese with body mass index of more than 30 and 100 had normal body mass index. Ethical committee clearance was obtained from institutional ethical board and all the subjects were informed about the study and a written consent was obtained from all in their vernacular language. All the subjects were age and gender matched. A complete demographic detail was obtained from all the subjects. Body mass index was assessed by dividing weight in kilograms divided by height in square meter. Beck Depression Inventory was used for the assessment of rate of depression. All the data was arranged in a tabulated form and analysed using SPSS software. Chi square test was used to analyse the results. P value of less than 0.05 was regarded significant.

METHODOLOGY

Study Type: This study was an observational descriptive study.

Study Place and Period: This study was accompanied at Rajshahi Medical College Hospital, Rajshahi, Bangladesh from January 2017 to January 2019 where 59 cases were observed.

Sample Size: During this study 59 consecutive patients of dorsal-lumbar spine injuries with neurological deficit ranged from 14–65 years were included in this study. Out of them 56 (94.91%) patients were male and remaining 3 (5.09%) were female.

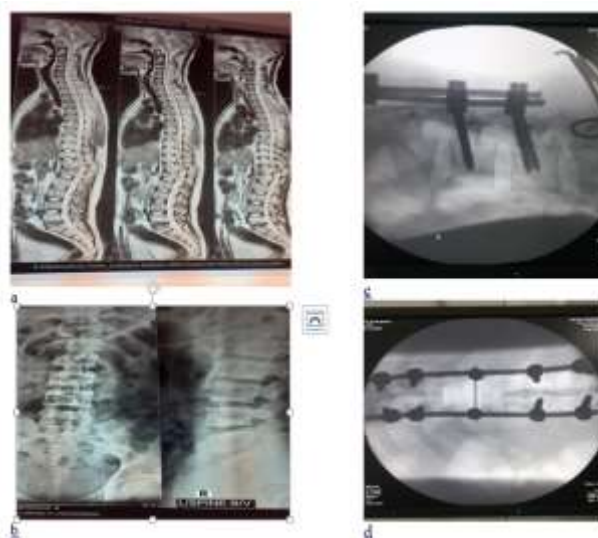
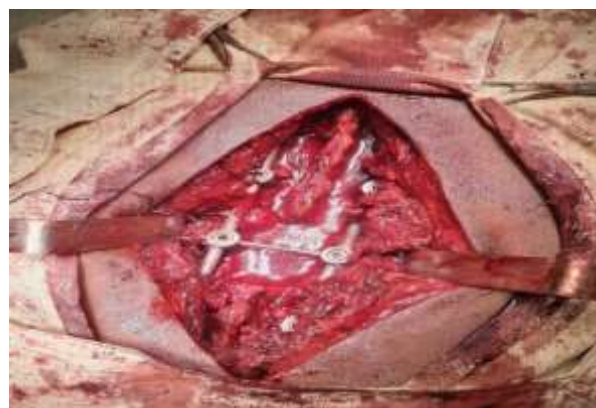

Fig 1a and 1b: Shows spinal cord injury operation and 40 year old male with fall from height with burst fracture L2 vertebra

METHOD

In the study clinically Patients were graded using Frankel classification of neurological deficits pre- and postoperatively as follows:

- Absent motor and sensory function.
- Sensation present, motor function absent.
- Sensation present, motor function active but not useful (Grade 2—3/5).
- Sensation present, motor function active and useful (Grade 4/5).
- Normal motor and sensory function.

STATISTICAL ANALYSIS

Statistical Package for Social Sciences (SPSS) version 20 for windows was used to analyze the data. Descriptive statistics were computed. Chi- square test was carried out to assess association of qualitative data.

To compare the mean differences between the groups student's t-tests and ANOVA were done. Strength of associations and their corresponding 95% confidence interval (CI) were calculated. Statistical significance was defined as $p < 0.05$.

RESULTS

In Figure-2 shows types of injury where most of the patients face fall of height 84.85%. In Table-1 shows fracture in 59 case where D12 vertebra was fractured in most of the cases followed by L1 vertebra was fractured in 19 cases. In Figure-3 shows that Correlation of prognosis with Frankel grade on admission where Majority of the patients belonged to frankel grade A (71.18%) and 13% belongs to frankel grade B/C. In Table-2 shows after posterior approach 17 patients presented with partial neurological deficit showed significant improvement after surgery. In Figure-4 shows Fracture Pattern in Dorsal-lumbar Spinal Injuries where Common type of fractures were compression and burst fractures. In Table-3 shows Correlation with the timing of surgery where early surgery is beneficial in neurological recovery of these patients. However, the P value was not statistically significant ($p = 0.08$). There was a statistically significant correlation between the cord change on MRI and the neurological recovery at final follow up.

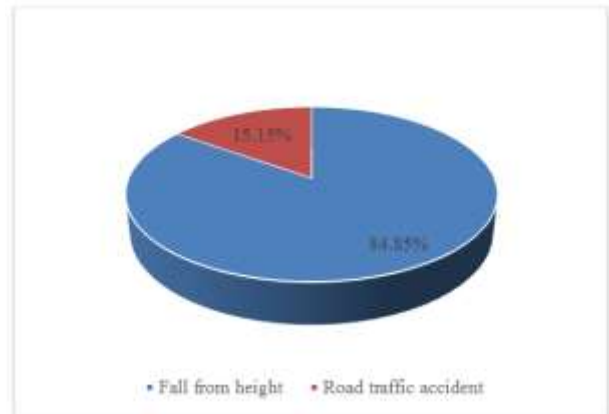


Fig-2: Types of injury

Table-1: Fracture in 59 case

Fracture	Case (n=59)
L1	19
L2	4
L3	4
L4	2
D12	20
D12/L1	2
L1/L2	2
D9	1
D11	1
D10/D11	1
D11/D12	1
D12/L3	1
D5/D6	1

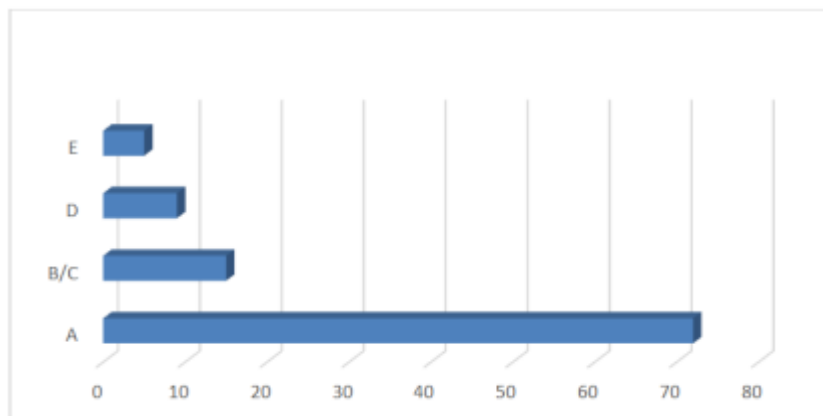


Fig-3: Correlation of prognosis with Frankel grade on admission

Table-2: Improvement after surgery

Number of patients (n=59)	Improved level after surgery
17 patients with partial neurological deficit	Significant Improvement
42 patients who presented with complete paraplegia	
13	Mild Neurological Improvement
29	No Improvement

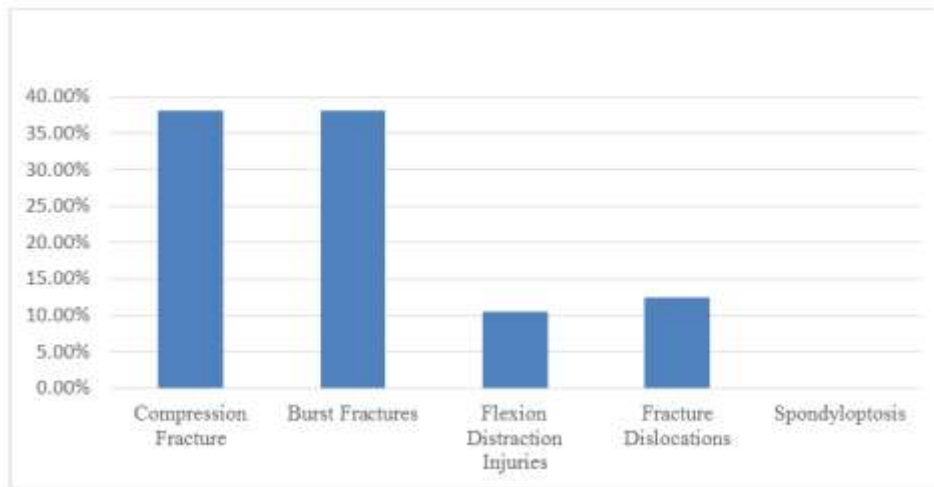


Fig-4: Fracture Pattern in Dorsal-lumbar Spinal Injuries

Table-3: Correlation with the timing of surgery

Duration before surgery	<7 days (N=17)	>7 days (N= 42)	P value
Improvement	8	6	0.08
Same	9	36	

DISCUSSION

Dorsolumbar spine fractures account for the most common cause of traumatic paraplegia. Most of the affected belong to the productive age group, thus having a major economic burden on the society. The aim of treatment is restoration of function of the patient by creating a healing environment to allow a stable pain free spinal column, with the minimal risk to the patient [5-7]. Paraplegia is a paralysis of the legs and lower body, typically caused by spinal injury. In Bangladesh Dorsal-lumbar spine fractures account for the most common cause of traumatic paraplegia. Most of the affected patients belong to the productive age group, thus having a main economic burden on the society. The goal of treatment is restoration of function of the patient by creating a healing environment to allow a stable pain free spinal column, with the minimal risk to the patient. During the study Fracture Pattern in Dorsal-lumbar Spinal Injuries where Common type of fractures were compression and burst fractures which was 38.5%. Most of the patients got their injury from fall of height (84.85%). Fracture in 59 case where D12 vertebra was fractured in 20 cases. During study 42 cases presented with complete paraplegia while 17 presented with incomplete neurological deficit. All patients were operated using posterior approach, by decompression of the cord by laminectomy at the site of injury with stabilization by interpedicular screws and rods above and below the level if injured vertebral body. There was no deterioration in neurological status in any of the patients where <7 days (N=17) only improve 8 and in

>7 days (N= 42) only improve [9]. The management of fractures in the thoracolumbar region is a controversial subject. Disadvantages of conservative treatment include deterioration in neurological status in 17% of the patients, progressive kyphotic deformity in 20%, persistent backache, decubitus ulcer and deep venous thrombosis. Most of these complications can be avoided by early mobilization and decreased hospital stay by early surgery [6, 7, 10]. But many studies reported that disadvantages of conservative treatment include deterioration in neurological status in 17% of the patients, progressive kyphotic deformity in 20%, persistent backache, decubitus ulcer and deep venous thrombosis. Most of these complications can be avoided by early mobilization and decreased hospital stay by early surgery. Even in complete cord injury the incidence of complication due to immobilization of patients were reduced dramatically with improved quality of life. We suggest that for better correction and maintenance of kyphotic angle global fixation along with fusion should be taken into consideration.

CONCLUSION AND RECOMMENDATION

After many studies and observation. We conclude that fall from height is the most common cause of dorsal-lumbar spine fracture with majority affected belonging to young population and had significant deficits, thus causing significant burden on the society. This rapid surgical management is safe and

helps in early mobilization and rehabilitation, thus facilitating possible neurological recovery and achieving a betterment of life. We can hope in near future with various new technology can minimize this type of injury. For more effective outcome need big sample size and high technical instrument for further study.

REFERENCES

1. Lukas R, Suchomel P, Sram J. Surgical treatment of thoracolumbar spine fractures. *Coluna/columna*. 2006;5(2):84-9.
2. Kraemer WJ, Schemitsch EH, Lever J, McBroom RJ, McKee MD, Waddell JP. Functional outcome of thoracolumbar burst fractures without neurological deficit. *Journal of orthopaedic trauma*. 1996 Nov 1;10(8):541-4.
3. Esses SI, Botsford DJ, Kostuik JP. Evaluation of surgical treatment for burst fractures. *Spine*, 1990;15(7):667-73.
4. McDonough PW, Davis R, Tribus C, Zdeblick TA. The management of acute thoracolumbar burst fractures with anterior corpectomy and Z-plate fixation. *Spine*. 2004 Sep 1;29(17):1901-8.
5. Dashti H, Lee HC, Karaikovic EE, Robert W. Gaines Jr Decision making in dorsolumbar fractures. *Neurology India*. 2005;53.
6. Lemons VR, Wagner Jr FC, Montesano PX. Management of thoracolumbar fractures with accompanying neurological injury. *Neurosurgery*. 1992 May 1;30(5):667-71.
7. Hitchon PW, Torner JC, Haddad SF, Follett KA. Management options in thoracolumbar burst fractures. *Surgical neurology*. 1998 Jun 1;49(6):619-27.
8. Rehtine 2nd GR, Cahill D, Chrin AM. Treatment of thoracolumbar trauma: comparison of complications of operative versus nonoperative treatment. *Journal of spinal disorders*. 1999 Oct 1;12(5):406-9.
9. Denis F. Spinal instability as defined by the three-column spine concept in acute spinal trauma. *Clinical Orthopaedics and Related Research*. 1984 Oct 1;189:65-76.
10. Hitchon PW, Torner JC. Recumbency in thoracolumbar fractures. *Neurosurgery Clinics of North America*. 1997 Oct 1;8(4):509-17.

Cite This Article: Munzur Rahman & Shah Alam (2021). Outcome of Surgical Management of Unstable Dorso-Lumbar Spine Injuries with Transpedicular Screws and Rods Fixation with Posterior Decompression. *East African Scholars J Med Sci*, 4(2), 42-46.