

## Research Article

# Diagnostic Performance of CT Scan in the Evaluation of Brain Abscess

Md. Hafizur Rahman<sup>1\*</sup>, Zakir Hossain ASM<sup>2</sup>, Md. Anisur Rahman<sup>3</sup>, Nashid Amir<sup>4</sup>

<sup>1</sup>Professor, Department of Radiology and Imaging, Rajshahi Medical College, Rajshahi, Bangladesh

<sup>2</sup>Professor, Department of Radiology and Imaging, NIDCH, Dhaka, Bangladesh

<sup>3</sup>Assistant Professor, Department of Radiology and Imaging, Rajshahi Medical College, Rajshahi, Bangladesh

<sup>4</sup>Radiologist, Department of Radiology and Imaging, Rajshahi Medical College Hospital, Rajshahi, Bangladesh

### Article History

Received: 13.02.2021

Accepted: 24.02.2021

Published: 27.02.2021

### Journal homepage:

<https://www.easpublisher.com>

### Quick Response Code



**Abstract:** **Introduction:** Brain abscess is a life threatening disease that present a formidable challenge to the physicians. Despite the development of effective antibiotics & modern surgical techniques significant mortality & morbidity persist among patients with CNS infections. **Aim of the study:** To assess the CT scan findings, sensitivity and specificity of CT scan in the diagnosis of brain abscess. **Material & Methods:** This cross sectional consecutive observational study was conducted at the Department of Radiology and Imaging of Rajshahi Medical College Hospital from January, 2018 to December, 2018. Fifty-five (55) patients were selected using consecutive, non-randomized and open sampling method considering the inclusion and exclusion criteria. All the relevant data were collected, compiled and then organized by standard appropriate statistical formulae. Statistical analyses of the results were obtained with Statistical Packages for Social Sciences (SPSS-13). Statistical tests for significance of difference were done using t test, chi square test, or 'Z' test where applicable. A 'p' value < 0.05 was considered as significant. For Z test of proportion window based computer software devised with MINIT AB-12 was used. **Results:** The age range was from 11 to 65 years and the mean  $\pm$ SD age was 34.18 $\pm$ 16.81 years. Statistical analysis of patients of both sex has revealed that they were within similar age distribution (p value= 0.385). Single lesion was present in 83.6% patients and 16.4% had multiple lesions in the brain. 94.5% patients had abscess in gray-white matter junction and rests had within white matter. A total 52.7% patients had brain abscess on right cerebral hemisphere followed by 43.6% on left hemisphere and 3.6% had on cerebellum. 94.5% lesions were hypodense on CT and rests had both hypo and isodense feature. Ring enhancement and surrounding edema were the most common characteristic CT features in the diagnosis of brain abscess. **Conclusion:** Culturally and cytopathologically diagnosed 52 brain abscess cases had ring enhancement on CT. They were true positive. Three cases had this feature on CT but they were not confirmed as brain abscess by cultural and cytopathological findings. They were false positive. No false negative and true negative case was diagnosed.

**Keywords:** Brain Abscess, Antibiotics, CT scan evaluation, Sensitivity, Specificity.

**Copyright © 2021 The Author(s):** This is an open-access article distributed under the terms of the Creative Commons Attribution 4.0 International License (CC BY-NC 4.0) which permits unrestricted use, distribution, and reproduction in any medium for non-commercial use provided the original author and source are credited.

## INTRODUCTION

Brain abscess is a life threatening disease that presents a formidable challenge to the physicians. Despite the development of effective antibiotics & modern surgical techniques significant mortality & morbidity persist among patients with CNS infections. Mortality from brain abscess is still around 10% though it was about 40-50% before the advent of cross sectional imaging [1-3]. Pyogenic bacteria produce most abscesses. Overall the organism most frequently isolated from cerebral abscesses is streptococcus (aerobic/anaerobic), staphylococcus, Gram (-) ve organisms are increasing cause of cerebral abscess. In neonates the most frequently implicated organisms are Citrobacter, Proteus, Serratia & S. aureus. Increasingly

opportunistic infection is a cause of brain abscess including M. tuberculosis, fungi such as actinomyces, Candida species, Aspergillums & parasites. Brain abscess was found to occur in 1 or every 49 bone marrow transplant recipients at one large center. Central nervous system (CNS) infections occur in approximately 2.7 to 12% of all solid organ transplant recipients, and the CNS is one of the most common sites of infection in these patients. In one series of solid organ transplantations, the overall rate of brain abscess was 0.61 % with the highest rate occurring in heart and heart-lung transplant recipients (1.17%) [4]. The presenting features of brain abscess may include fever, headache, nausea, vomiting, drowsiness & full-blown coma, focal neurological signs & seizures. Brain abscess is a serious, life-threatening condition which,

until a decade ago, was associated with a mortality of about 40%. Over the last ten to fifteen years the mortality has fallen to less than 10%. This reduction has been attributed mainly to the introduction of computerized tomography, allowing earlier diagnosis and more precise localization of the abscess. The mainstay imaging modalities for the diagnosis of brain abscess includes Computed Tomography, Magnetic Resonance Imaging & Nuclear Imaging. Brain abscess continues to be a problem in neurosurgery and associates with morbidity and mortality even in the antibiotics and computed tomography (CT) era. CT scan has led to improved accuracy in identifying and diagnosing abscesses, and the benefits of being able to follow the clinical course by this modality through the period of treatment are obvious as the authors record a fall in mortality to 10%. The use of CT has brought a marked decrease in mortality and morbidity among patients with brain abscess [5]. And the advent of MRI has accelerated the trend. Currently MRI has become the modality of choice in the evaluation of CNS infections but it is at least 3-4 times expensive investigation & is available in very few hospitals. So in our set up CT scan is a useful investigation in the early diagnosis of brain abscess [6]. Therefore, this study is intended to assess the CT scan findings, sensitivity and specificity of CT scan in the diagnosis of brain abscess.

## OBJECTIVES

### a) General objective

- To assess the CT scan findings, sensitivity and specificity of CT scan in the diagnosis of brain abscess.

### b) Specific Objectives

- To establish diagnostic usefulness of CT in evaluation of brain abscess
- To determine the location of brain abscess.

## METHODOLOGY AND MATERIALS

This cross sectional consecutive observational study was conducted at the Department of Radiology and Imaging of Rajshahi Medical College Hospital. The study period was from January, 2018 to December, 2018. Fifty-five (55) patients were selected using Consecutive, non-randomized and open sampling method. At first all the patients were evaluated by detail history and clinical examination with special emphasis on nervous system. All the selected cases underwent burr-hole operation. Aspirated materials were sent accordingly both for culture-sensitivity and cytopathological examinations for further evaluation and management. Those patients who were operated upon for brain abscess were continuously followed up after surgery up to pathological diagnoses were done. Ring enhancement, hypodense area, location of abscess in gray-white matter junction, sulcal & ventricular effacement were considered as positive CT findings for brain abscess. All information was collected in pre-

designed data sheets. Informed consent from the patients or their parents was obtained. The relevant collected data were compiled and then organized by standard appropriate statistical formulae. Further statistical analyses of the results were obtained by using window based computer software devised with Statistical Packages for Social Sciences (SPSS-13). For the validity of study outcome, sensitivity, specificity, accuracy, positive predictive value and negative predictive value of CT scan in the diagnosis of brain abscess were calculated out after confirmation of the diagnosis by pathological examinations according to formulae described by Knapp and Millar (1992). Statistical tests for significance of difference were done using t test, chi square test, or 'Z' test where applicable. A 'p' value < 0.05 was considered as significant. For Z test of proportion window based computer software devised with MINIT AB-12 was used.

### Inclusion Criteria

- Patient having clinical suspicion of brain abscess and supported by CT scan.

### Exclusion Criteria

- Patients who were not willing to undergo surgery and hence no pathological reports are available.
- Non co-operative patient.

## RESULTS

In this study, the age range was from 11 to 65 years and the mean age ( $\pm$ SD) was  $34.18 \pm 16.81$  years. Highest incidence of brain abscess, 29.1 %, was found in 10 to 20 years' age group followed by 20.0% between 21 to 30 years' age group and 20.0% between 41-50 years' age group. Statistical analysis of patients of both sex has revealed that they were within similar age distribution (p value= 0.385). Mean $\pm$ SD age of male was  $36 \pm 3.101$  years whereas the Mean $\pm$ SD of female was  $32 \pm 3.337$  years. Median age of both male and female was 35 and 28 years respectively. Out of 55 patients 30 were male and 25 were female, male to female ratio was 1.2: 1 (Figure I). Single lesion was present in 83.6% patients and 16.4% had multiple lesions in the brain. 94.5% patients had abscess in gray-white matter junction and rests had within white matter. 52.7% patients had brain abscess on right cerebral hemisphere followed by 43.6% on left hemisphere and 3.6% had on cerebellum. 94.5% lesions were hypodense on CT and rests had both hypo and isodense feature. CT feature of midline shifting was observed in 67.3% patients, 80% patients had sulcal and gyral effacement and 27.3% had ventricular dilatation (Table III). CT scan revealed that maximum patients 23 (41.8%) had brain abscess on temporal lobe followed by frontal lobe (29.1 %), parietal lobe (10.90/0), occipital lobe (3.6%), in cerebellum (3.6%), 5 (9.1 %) patients had brain abscess on temporoparietal lobes and 1.8% had frontoparietal lobes (Table IV). Sensitivity of ring

enhancement feature to diagnose brain abscess was 100.0%, positive predictive value 94.5%, and accuracy 94.5%. Negative predictive value and specificity cannot be calculated (Table V and Figure II). Presence of hypodense feature was found a reliable sign of brain abscess because sensitivity, specificity, positive predictive value, negative predictive value, and accuracy 98.1 %, 66.7%, 98.1 %, 66.7% and 96.4% respectively. In our series, out of 52 pathologically diagnosed brain abscess patients, 51 (98.1 %) had hypodense CT feature. One (33.3%) 'Other lesions' had hypodense CT feature. CT evaluation of location of abscess in gray-white matter junction in our series, out of 52 pathologically diagnosed brain abscess patients, 51 (98.1%) had abscess in gray-white matter junction. One (33.3%) 'Other lesions' had abscess in this location. Presence of abscess in this location was found a reliable sign of brain abscess because sensitivity, specificity, positive predictive value, negative predictive value, and

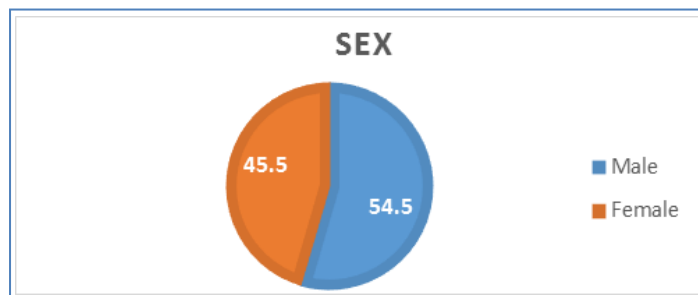
accuracy 98.1%,66.7%, 98.1%, 66.7% and 96.4% respectively (Table VII and Figure IV). In our series, out of 52 pathologically diagnosed brain abscess patients, 42 (80.80/0) had sulcal and ventricular effacement. Two (66.7%) 'Other lesions' had sulcal and ventricular effacement. Sulcal and ventricular effacement was found a reliable sign of brain abscess because sensitivity, specificity, positive predictive value, negative predictive value, and accuracy 80.8%, 33.3%,95.5%,9.1% and 78.2% respectively. This result is shown in table VIII and figure V. Out of all cases 52 were diagnosed as brain abscess by CT and confirmed by cultural and cytopathological evaluation. They were true positive. Three cases cytopathological findings. They were false positive. No false negative and true negative case was diagnosed. Sensitivity of CT to diagnose brain abscess was 100.0%, positive predictive value 94.50/0, and accuracy 94.5%. Negative predictive value and specificity cannot be calculated (Table IX).

**Table -I: Age distribution of the patients (N=55)**

Age (year)	Frequency	Percent	Mean± SD	Range
10-20	16	29.1	34.18±16.81	11-65
21-30	11	20.0		
31-40	7	12.7		
41-50	11	20.0		
51-60	6	10.9		
61-65	4	7.3		
Total	55	100.0		

**Table-II: Age of the patients (N=55)**

Age (Year)	Sex	
	Male (n=30)	Female (n=25)
Mean±SE	36.0±3.101	32.0±3.337
Range	11-65	12-62
Median	35	28



**Fig-I: Sex distributions of the patients**

**Table-III: CT feature of the patients (N=55)**

CT findings	Frequency	Percent	Z value	p value
<b>Number</b>				
Single	46	83.6	4.99	0.001
Multiple	9	16.4	-4.99	0.001
<b>Location of abscess</b>				
White matter	3	5.5	-6.61	0.001
Gray-white matter junction	52	94.5	6.61	0.001
<b>Involved hemisphere</b>				
Right cerebral hemisphere	29	52.7	0.40	0.686
Left cerebral hemisphere	24	43.6	-0.94	0.345
Cerebellum	2	3.6	-6.88	0.001
<b>Density</b>				
Hypodense	52	94.5	6.61	0.001
Mixed	3	5.5	-6.61	0.001
Surrounding edema	55	100.0	7.42	0.001
Midline shifting	37	67.3	2.56	0.010
Sulcal and ventricular Effacement	44	80.0	-4.45	0.001
Ring enhancement	55	100.0	7.42	0.001
Ventricular dilatation	15	27.3	-3.37	0.001

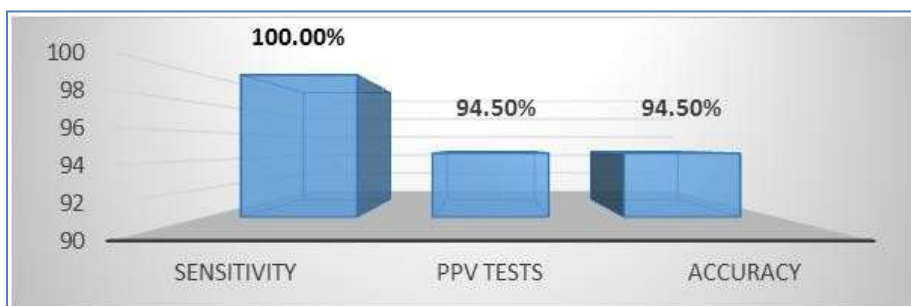
**Table-IV: CT evaluation of different sites of brain abscess**

Abscess site	Frequency	Percent
Temporal lobe	23	41.8
Frontal lobe	16	29.1
Parietal lobe	6	10.9
Occipital lobe	2	3.6
Cerebellum	2	3.6
Frontoparietal lobes	1	1.8
Temporoparietal lobes	5	9.1
Total	55	100.0

**Table-V: CT evaluation of ring enhancement and it's correlation with pathological diagnosis**

Ring enhancement	Pathological Diagnosis		Total
	Brain abscess	Other	
Brain abscess	52 (True positive)	3 (False positive)	55
Other	0 (False negative)	0 (True negative)	0
Total	52	3	55

Chi square value (after Yates correction) = 19.465, df=1, p value=0.001, Sensitivity= 100%, PPV=94.5% Accuracy= 94.5%

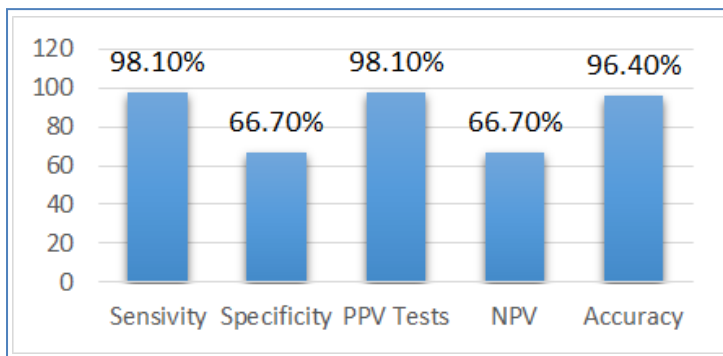


**Fig-II: Different types of validity test results in the evaluation of CT feature (ring enhancement) of brain abscess**

**Table-VI: CT evaluation of hypodense feature and its correlation with pathological diagnosis**

Density	Pathological diagnosis		Total
	Brain abscess	others	
Hypodense:	51 (98.1)	1 (33.3)	52 (94.5)
Mixed	1 (1.9)	2 (66.7)	3 (5.5)
Total	52 (100.0)	3 (100.0)	55 (100.0)

Chi square value (after Yates correction) = 12.209, df= 1, P value=0.001, Sensitivity=98.1%, Specificity=66.7%, PPV=98.1%, NPV=66.7%, Accuracy= 96.4%

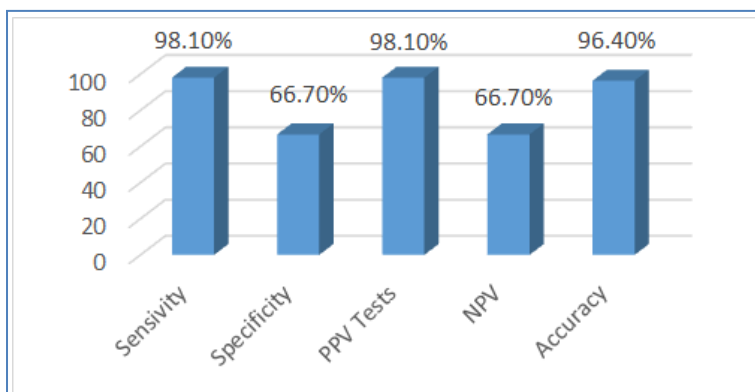


**Fig-III: Different types of validity test results in the evaluation of CT feature (hypodense feature) of brain abscess**

**Table-VII: CT evaluation of location of abscess in gray-white matter junction and it's correlation with pathological diagnosis**

Location	Pathological diagnosis		Total
	Brain abscess	others	
Gray-White Matter Junction	51 (98.1)	1 (33.3)	52 (94.5)
White Junction	1 (1.9)	2 (66.7)	3 (5.5)
Total	52 (100.0)	3 (100.0)	55 (100.0)

Sensitivity=98.1 %, Specificity=66.7%, PPV=98.1%, NPV=66.7%, Accuracy=96.4%

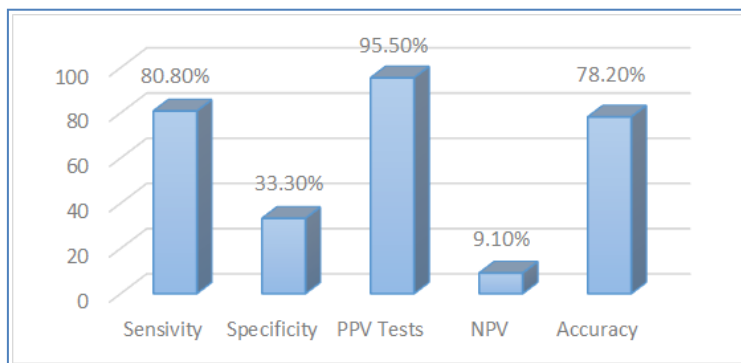


**Fig-IV: Different types of validity test results in the evaluation of CT feature (location of abscess in gray-white matter junction) of brain abscess**

**Table-VIII: CT evaluation of sulcal and ventricular effacement**

Sulcal & Ventricular effacement	Pathological diagnosis		Total
	Brain abscess	others	
Present	51 (98.1)	1 (33.3)	52 (94.5)
Absent	1 (1.9)	2 (66.7)	3 (5.5)
Total	52 (100.0)	3 (100.0)	55 (100.0)

Chi square value (after Yates correction) = .001, df=1, p value=1.00, Sensitivity= 80.8%, Specificity=33.3%, PPV=95.5%, NPV=9.1%, Accuracy=78.2%



**Fig-V: Different types of validity test results in the evaluation of CT feature (sulcal and ventricular effacement) of brain abscess**

**Table-IX: CT evaluation of brain abscess and its correlation with cultural and cytopathological findings.**

Ring enhancement	Pathological Diagnosis		Total
	Brain abscess	Other	
Brain abscess	52 (True positive)	3 (False positive)	55
Other	0 (False negative)	0 (True negative)	0
Total	52	3	55

## DISCUSSION

Brain abscess is a serious, life-threatening condition which, until a decade ago, was associated with a mortality of about 40%. Over the last ten to fifteen years the mortality has fallen to less than 10%. The mean±SD age of the patients of present study group was 34.18±16.81 years with a range of 11 to 65 years. Highest incidence of brain abscess, 29.1%, was found in 10 to 20 years' age group followed by 20.0% between 21 to 30 years' age group and 20.0% between 41-50 years' age group. The age distribution was from 3 days to 81 years in a study conducted by Berlit *et al*. [7]. Mean age of Bhand [8] series was 18 years with a range 05 months to 55 years. Study group of Demir *et al*. [9] consisted of 66 male and 30 female patients, mean age 29.7 years (range 5-80 years), with 29 patients (30%) being under the age of 15 years. Out of 55 patients of present study group 30 were male and 25 were female. Here male and female ratio was found 1.2: 1. Sixty-seven patients with brain abscess who were managed over 19 years (1975-1993) studied by Berlit *et al*. [7]. Their series had a 2.5 to 1 male predominance. Male predominance picture of this series was comparable with us. Male dominant picture was also reported by Bhand [8]. Out of 82 patients of their study group 58 were male and 24 were female. On CT 94.5% lesions were hypodense and rests were both hypo and iso dense feature. All patients of present study group had CT feature of edema around the lesions and presented with ring enhancement. CT feature of midline shifting was observed in 67.3% patients, 80% patients had sulcal and ventricular effacement and 27.3% had ventricular dilatation. Seidl [10] examined 29 patients with the diagnosis of brain abscess by computed tomography (CT). In 28 instances the CT finding was hypodense lesion with ring enhancement which became more marked after administration of the contrast substance. Faraji-Rad and Samini [11] stated the most

common sites of the brain abscess were the frontal (53%) and temporoparietal (28%) lobes. CT is highly sensitive (>95%) in detecting this type of lesion. Unfortunately, ring-enhancing lesions seen on CT images are not specific for brain abscess; cystic and necrotic neoplastic lesions, hematomas, and infarcted brain tissue may have the same CT characteristics [9]. In our series, out of 52 pathologically diagnosed brain abscess patients, 51 (98.1%) had hypodense CT feature. One (33.3%) 'Other lesions' had hypodense CT feature. We therefore consider that absence of hypo dense CT feature a very low possibility of being lesions other than brain abscess (p<. 00 I). Presence of hypodense feature was found a reliable sign of brain abscess because sensitivity, specificity, positive predictive value, negative predictive value, and accuracy 98.1%, 66.7%, 98.1 %, 66.7% and 96.4% respectively. Presence of abscess in gray white matter location was found a reliable sign of brain abscess because sensitivity, specificity, positive predictive value, negative predictive value, and accuracy 98.1%, 66.7%, 98.1%, 66.7% and 96.4% respectively. Sulcal and gyral effacement was found a reliable sign of brain abscess because sensitivity, specificity, positive predictive value, negative predictive value, and accuracy 80.8%, 33.3%, 95.5%, 9.1 % and 78.2% respectively. Out of all cases in present series 52 were diagnosed as brain abscess by CT and confirmed by cultural and cytopathological evaluation. They were true positive. Three cases were diagnosed as brain abscess by CT but not confirmed by cultural and cytopathological findings. They were false positive. No false negative and true negative case was diagnosed. Sensitivity of CT to diagnose brain abscess was 100%, positive predictive value 94.5%, and accuracy 94.5%. Negative predictive value and specificity cannot be calculated. Using CT by Kaufman and Leeds [12], no case of a brain abscess was overlooked or misdiagnosed; there were no false-

negative reports. All abscesses, as observed on CT scans, correlated exactly with location at surgical exploration (eight cases) or pathologic examination (one case). The computed tomography (CT) scans of 60 patients with intracranial infection have been reviewed by Shaw and Russell [13]. Computed tomography, particularly if used with contrast enhancement, is a valuable adjunct to the investigation of patients with suspected intracranial abscess.

## LIMITATIONS OF THE STUDY

The study period was relatively short. Also, the sample size was comparatively small. So, the findings may not reflect the scenario of the whole country.

## CONCLUSION AND RECOMMENDATIONS

Brain abscesses are usually diagnosed on the basis of findings from CT and MR imaging, together with the clinical manifestations. CT scan thus can be regarded as a primary imaging modality in the diagnosis of brain abscess. The study was limited to the patients who underwent CT with subsequent operation & pathological examination. The ability to make a rapid diagnosis of a brain abscess is very important in order to provide the correct medical treatment. CT scan thus can be regarded as a primary imaging modality in the diagnosis of brain abscess.

## REFERENCES

1. Claveria, L. E., Du Boulay, G. H., & Moseley, I. F. (1976). Intracranial infections: investigation by computerized axial tomography. *Neuroradiology*, 12(2), 59-71.
2. Rosenblum, M. L., Hoff, J. T., Norman, D., Weinstein, P. R., & Pitts, L. (1978). Decreased mortality from brain abscesses since advent of computerized tomography. *Journal of neurosurgery*, 49(5), 658-668.
3. Whelan, M. A., & Hilal, S. K. (1980). Computed tomography as a guide in the diagnosis and follow-up of brain abscesses. *Radiology*, 135(3), 663-671.
4. Calfee, D. P., & Wispelwey, B. (2000). Brain abscess. In *Seminars in neurology* (Vol. 20, No. 03, pp. 353-360). Copyright© 2000 by Thieme Medical Publishers, Inc., 333 Seventh Avenue, New York, NY 10001, USA. Tel.:+ 1 (212) 584-4662.
5. Osborn, A.G. (1994). *Diagnostic Neuroradiology* 1st edition, USA: Mosby, 673-715.
6. Imran, S., & Idrees, M. (2002). Role of ct scan in the diagnosis of brain infections. *Brain*, 54, 21-6.
7. Berlit, P., Fedel, C., Tornow, K., & Schmiedek, P. (1996). Bacterial brain abscess--experiences with 67 patients. *Fortschritte der Neurologie-psychiatrie*, 64(8), 297-306.
8. Bhand, A.A. (2004). Brain abscess--diagnosis and management. *J Coll Physicians Surg Pak*, 14(7):407-10.
9. Demir, M. K., Hakan, T., Kilicoglu, G., Ceran, N., Berkman, M. Z., Erdem, I., & Göktaş, P. (2007). Bacterial brain abscesses: prognostic value of an imaging severity index. *Clinical radiology*, 62(6), 564-572.
10. Seidl, Z. (1990). Diagnosis of brain abscess using computer tomography. *Casopis lekaru ceskych*, 129(17), 526-528.
11. FARAJI, R. M., & Samini, F. (2007). Clinical features and outcome of 83 adult patients with brain abscess.
12. Kaufman, D.M., Leeds, N.E. (1977). Computed tomography (CT) in the diagnosis of intracranial abscesses. *Neurology*, 27: 1069-1073.
13. Shaw, M. D., & Russell, J. A. (1977). Value of computed tomography in the diagnosis of intracranial abscess. *Journal of Neurology, Neurosurgery & Psychiatry*, 40(3), 214-220.

**Cite This Article:** Hafizur Rahman *et al* (2021). Diagnostic Performance of CT Scan in the Evaluation of Brain Abscess. *EAS J Radiol Imaging Technol*, 3(1), 22-28.