

Original Research Article

Role of High-Resolution Computed Tomography (HRCT) in COVID-19

Anisa Riaz^{1*}, Taiba Zulfiqar², Muhammad Ahmad Naeem³, Jazba Naseer⁴, Abid Ali⁵^{1,4}Medical Imaging Doctor, Department of Radiological Sciences and Medical Imaging, University of Lahore, Gujrat, Pakistan²Senior lecturer, Department of Radiological Sciences and Medical Imaging, University of Lahore, Gujrat, Pakistan³Lecturer, Department of Radiological Sciences and Medical Imaging, University of Lahore, Gujrat, Pakistan⁵Associate Professor, Department of Allied Health Sciences, University of Lahore, Gujrat, Pakistan

Article History

Received: 06.04.2021

Accepted: 15.05.2021

Published: 23.05.2021

Journal homepage:

<https://www.easpublisher.com>

Quick Response Code



Abstract: Background: Covid 19 is a highly contagious widespread disease-causing thousands of deaths daily. Early diagnosis of this disease proved to be one of the most effective methods for infection tree pruning. The large number of COVID-19 patients is rendering health care systems in many countries overwhelmed. Hence, a trusted automated technique for identifying and quantifying the infected lung regions would be quite advantageous. As many studies revealed that High resolution computed tomography HRCT scan one of the best imaging technique to evaluate the lung condition for proper diagnosis and treatment. **Objective:** The goal of this study was to investigate high resolution computed tomography findings among covid 19 patients for early detection of disease among symptomatic patients to reduce the risk of worsening of condition. **Methodology:** 118 participants were recruited from Gondal Medical Complex, Gujranwala. The data was collected through history forms and HRCT reports and the data was evaluated through mean and percentages%. **Results:** In this survey male participants were 63% and female participants were 55%. 14% of the participants were between the age ranges of less than 30 year, 49% of the participants were between age range of 30 to 45 years. HRCT findings revealed regarding Ground glass opacities, 53% of the participants were having GGO, and remaining 46% participants do not have history of GGO. 41% of the participants were having consolidation whereas remaining 58.9% participants do not have consolidation, 33% of the participants were having cavitation abscess, and 66% participants do not have cavitation abscess, 22% of the participants were having Nodules and remaining 77% participants do not have nodules. 13.6% of the participants were having mass and 77% participants do not have mass. **Conclusion:** The standard ground glass opacities and many other CT characteristics in the patients with the COVID-19 infection generally demonstrated important similarities with some diagnostic parameters Distinguishing characteristics of covid 19 have been illustrated in CT images.

Keywords: HRCT, COVID-19, Fever, SOB, Ground glass opacity.

Copyright © 2021 The Author(s): This is an open-access article distributed under the terms of the Creative Commons Attribution 4.0 International License (CC BY-NC 4.0) which permits unrestricted use, distribution, and reproduction in any medium for non-commercial use provided the original author and source are credited.

INTRODUCTION

One of most significant effects of Coronavirus Disease 2019 (COVID-19) is more than billion fatalities globally, arising in the world's demography as a consequence of serious acute respiratory disease (SARS-CoV-2). The result became the world's most fatal condition of human health since the 1918 influenza pandemic. Following the initial confirmed cases of this primarily breathing virus in Wuhan, Hubei Province, China, at the end of December 2019, SARS-CoV-2 quickly spread worldwide in a limited period, forcing the WHO to announce a global pandemic as of 11 March 2020. SARS-CoV-2 was documented in China. COVID-19 has devastated several nations around the world since it was announced a worldwide virus

outbreak, overpowering many health services. The pandemic also caused loss of livelihood strategies because of lengthy closures that affected the global economic situation. Although the considerable advancement has been made in medical research, there is still greater awareness in SARS-CoV-2 and COVID-19 treatment, there is a growing concern to restrict the continued spreading of this virus, as SARS-CoV-2 is still rampant around the universe, many nations suffering a third or a fourth wave of outbreaks mainly due to the rise of this viral disease [1, 15].

A new heat-sensitive coronavirus, the COVID-19. Based on genetic studies, the virus evolved from animals such as bats, mice and birds and this has been

noticed that in Wuhan initially occurred pneumonia with unfamiliar etiology [2-5]. A very infectious illness is severe acute coronavirus syndrome (SARS-CoV-2). (6) On 14 January 2020, there had been 81 320 incidences of fatalities and 2,188 deaths in 160 nations outside China, including Italy, Iran, the South Korean Federation, France Japan, Singapore, Thailand, Malaysia, Germany, United States of America. Other countries outside China, including Italy and Iran, included the United States and South Korea [7]. CT is an effective technique of detection of lung anomalies. CT is a useful technique of detection. It has an incredibly special function in suspicious patient surveillance, diagnostic and variance evaluation, clinical classification, treatment response determination, lung detection and follow-up after discharged [7, 8].

The newest study suggests that 70 per cent of the novel coronavirus is similar in the genomic sequence to a bat coronavirus, which suggests the origin of this modern coronavirus take place from bats [9]. It quickly spreads to the surrounding nations, namely Japan and across the globe. Total cases have been registered by the WHO-report-43 until March of 2020, with 3,221 patient deaths. The results of the (CT) were announced from China and their subsequent update [10]. The viral pathogen, which would have been a single-stranded envelope of the coronavirus, was designated from (SARS-CoV-2), which is very close to the pattern of the infection triggered by the contagious infection caused by pathological virus as of the severe acute respiratory syndrome. (SARS-COV-2). These are the Viruses which potentially cause SARS, Middle East Respiratory Syndrome (MERS), and COVID 19, have animal origins and are spread to humans by contact. Viruses are the component of zoonotic disease. About 13.9percent of COVID-19 victims expired and around half of patients that attended clinics and hospitals since seeking care have released [2, 3]. CT is strongly recommended for initial chest related conditions and for preliminary or initial assessments of confirmed COVID-19 situations. The relevance of Lung CT testing in COVID-19 clinicians with false-negative RT-PCR findings has been investigated in modern reports in comparison, CT tests also plays a vital and most crucial role in tracking and measuring the progression of the disease [6, 11, 12]. The Chest HRCT plays a significant role in detecting COVID-19, with high sensitivity in a study conducted by a researcher in an environment with high prevalence of diseases varying between 61 percent to 99 percent, apparently [11-13].

MATERIALS AND METHOD

It was a cross sectional study of 118 patients from age between 15-80 of either gender. The participants were selected from Gondal Medical Complex, Gujranwala. The duration of the study was four months and the convenient sample technique was used.

The tool for collecting the data to assess the HRCT findings among covid 19 patients were history forms and HRCT scan reports. The data was analyzed by using SPSS software (version 22) and was evaluated through means, percentage%.

RESULTS

In this survey male participants were 63% and female participants 55% (Figure 01) regarding fever 50% of the participants were having fever whereas remaining 50% participants having no any history of fever. 59% of the participants were having cough whereas remaining 40% participants having no any history of cough. Regarding SOB, 58% of the participants were having SOB whereas remaining 41% participants having no any history of SOB. Lungs were affected bilaterally but upper lobe is affected in 15% of the participants, lower lobe is affected among 49.2% participants whereas both lobes affected among 42% of the patients and 7. 53% of the participants were having GGO whereas 41 % were having consolidation.

Regarding cavitation abscess, 33% of the participants were having cavitation abscess, whereas remaining 66% participants having no any history of cavitation abscess. And 22 % were having nodules as well. 13.6% of the participants were having mass and rest of 77 % didn't had.

33.5% of the participants were having bronchiectasis and 30.5% were having pericardial effusion as well. Regarding pleural effusion, 39.8% of the participants were having pleural effusion and 22% have necrotic area as well. The pleural thickening was seen in 32% of total patients. 33% patients were positive for lymphadenopathy among which 23% have lung collapse. The crazy pavings were only present in 7.6% of the participants (Table 01).

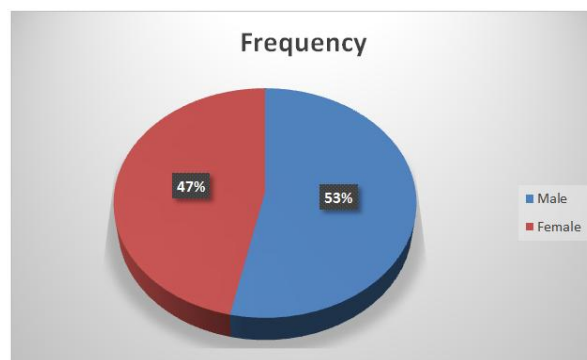


Fig-01: Gender Distribution

Table-01

HRCT Findings in COVID—19 patients		
Findings	Frequency	Percentage
Ground Glass opacities	63	53.4
Consolidation	49	41.5
Cavitation/Abscess	40	33.9

HRCT Findings in COVID—19 patients		
Nodules	27	22.9
Mass	16	13.6
Bronchiectasis	40	33.9
Pericardial effusion	36	30.5
Pleural effusion	47	39.8
Necrotic area	26	22
Pleural thickening	38	32.2
Lymphadenopathy	39	33.1
Lung collapse	28	23.7
Crazy paving	9	7.6

DISCUSSION

The COVID-19 is a viral illness recently identified. Early impression showed several regular results in clinical and HRCT symptoms. Fever (50%), dry cough (59%) and exhaustion (58%), which were compatible with earlier studies, have been the most prevalent signs. Most HRCT results, some identical with other virus pneumonia including, for example, SARS, MERS, have also shown including current one. The lower lobes are preferably influenced in terms of usability, in particular the left side lobe in the sub-pleural peribroncho-vascular region, which was most generally spread or spread diffusively in our sample groups. Initial stage penetration, convergence and interstitial thickening of several minor field, Ground glasses opacities could be observed. The progression of the disease means that serious patients are very typical and spectacular with greater convergence and air bronchograms in their respective lobes [14].

HRCT may support the identification of possible infectious patients by physicians and ant epidemic staff. According to individual therapies and heterogeneity of the individual [14].

In this sample, thin-section CT scores for GGO or ground glass opacity, multiple variables and clinical characteristics like SOB, nausea and fever have been discovered in a similar research of long-term care of patients after SARS [14].

A number of co analysis of diagnostic features in 2048 COVID-19 laboratory-confirmed patients showed that the concept of the monitoring event did not rely excessively on detection for fever, given that only 39.7 percent of the initial patients have fever. Our analysis showed that fever and peak temperature were not linked with initial CT anomalies but positively linked with disease progression. Such results suggest that high fever is a possible risk factor to negative CT outcomes on initial submission; however, small incidents must be noted in this report. Furthermore, some initial CT results were reverse-associated, including total score and max score for opacification magnitude and mass defect region in cross-section. A potential reason for such findings may be that the

original CT has improved in patients with comparatively chronic respiratory diseases [14].

CONCLUSION

Finally, it is concluded as the findings of the research showed that the detection and treatment of the COVID-19 infection is significant in chest CT. Despite careful therapies, the CT results of the clinical and radiological analysis indicate that Covid 19 is associated to Shortness of breath high temperature of the body, tiredness, cough and ground Glass opacities GGO, consolidation, mass, along with pleural effusion.

Conflict of Interest

Authors state that there is no conflict of interest regarding this research.

REFERENCES

1. Liu, C., Ye, L., Xia, R., Zheng, X., Yuan, C., Wang, Z., ... & Jin, M. (2020). Chest computed tomography and clinical follow-up of discharged patients with COVID-19 in Wenzhou City, Zhejiang, China. *Annals of the American Thoracic Society*, 17(10), 1231-1237.
2. Majidi, H., Bani-Mostafavi, E. S., Mardanshahi, Z., Godazandeh, F., Ghasemian, R., Heydari, K., & Alizadeh-Navaei, R. (2020). High-resolution computed tomography finding in 552 patients with symptomatic COVID-19: first report from north of Iran. *Emergency radiology*, 27(6), 633-639.
3. Sun, D., Li, H., Lu, X. X., Xiao, H., Ren, J., Zhang, F. R., & Liu, Z. S. (2020). Clinical features of severe pediatric patients with coronavirus disease 2019 in Wuhan: a single center's observational study. *World Journal of Pediatrics*, 1-9.
4. Su, S., Wong, G., Shi, W., Liu, J., Lai, A. C., Zhou, J., ... & Gao, G. F. (2016). Epidemiology, genetic recombination, and pathogenesis of coronaviruses. *Trends in microbiology*, 24(6), 490-502.
5. Chan, J. F. W., Yuan, S., Kok, K. H., To, K. K. W., Chu, H., Yang, J., ... & Yuen, K. Y. (2020). A familial cluster of pneumonia associated with the 2019 novel coronavirus indicating person-to-person transmission: a study of a family cluster. *The lancet*, 395(10223), 514-523.
6. Axiq, A., Almohtadi, A., Massias, S. A., Ngemoh, D., & Harky, A. (2021). The role of computed tomography scan in the diagnosis of COVID-19 pneumonia. *Current Opinion in Pulmonary Medicine*, 27(3), 163-168.
7. Lu, R., Zhao, X., Li, J., Niu, P., Yang, B., Wu, H., ... & Tan, W. (2020). Genomic characterisation and epidemiology of 2019 novel coronavirus: implications for virus origins and receptor binding. *The lancet*, 395(10224), 565-574.
8. Pan, F., Ye, T., Sun, P. (2019). Time course of lung changes on chest CT during recovery from 2019

- novel coronavirus (COVID-19) pneumonia [e-pub ahead of print]. *Radiology*.
9. Cui, J., Li, F., Shi, Z.L. (2019). Origin and evolution of pathogenic coronaviruses. *Nat Rev Microbiol*, 17(3):181–192.
 10. Chung, M., Bernheim, A., Mei, X., Zhang, N., Huang, M., Zeng, X., ... & Shan, H. (2020). CT imaging features of 2019 novel coronavirus (2019-nCoV). *Radiology*, 295(1), 202-207.
 11. Rodriguez-Morales, A. J., Cardona-Ospina, J. A., Gutiérrez-Ocampo, E., Villamizar-Peña, R., Holguin-Rivera, Y., Escalera-Antezana, J. P., ... & Sah, R. (2020). Clinical, laboratory and imaging features of COVID-19: A systematic review and meta-analysis. *Travel medicine and infectious disease*, 34, 101623.
 12. Team, C. S. I., Clarke, T. A., & Park, B. (2003). Preliminary clinical description of severe acute respiratory syndrome. *Morbidity and Mortality Weekly Report*, 52.
 13. Alhazzani, W., Møller, M. H., Arabi, Y. M., Loeb, M., Gong, M. N., Fan, E., ... & Rhodes, A. (2020). Surviving Sepsis Campaign: guidelines on the management of critically ill adults with Coronavirus Disease 2019 (COVID-19). *Intensive care medicine*, 46(5), 854-887.
 14. Xiong, Y., Sun, D., Liu, Y., Fan, Y., Zhao, L., Li, X., & Zhu, W. (2020). Clinical and high-resolution CT features of the COVID-19 infection: comparison of the initial and follow-up changes. *Investigative radiology*.
 15. Waseem, N. (2021). Role of Vascular Ultrasonography in COVID-19--Review Article. *Saudi J Med*, 6(2), 33-38.

Cite This Article: Anisa Riaz *et al* (2021). Role of High-Resolution Computed Tomography (HRCT) in COVID-19. *EAS J Radiol Imaging Technol*, 3(3), 146-149.