

Case Report

Neglected Fecal Impaction in HIV- Infected Patient leading to Stercoral Colonic Perforation with Fatal Peritonitis: A Case Report

Geofrey Giiti^{1*}, Noel Shija¹, Boniface Tresphory¹, Erasto Sylvanus², Rebecca Samweli³, Patrick Ngoya⁴, Augustino Hellar⁵, Gideon Mtalitinya⁶

¹Surgeon, Department of Surgery, Catholic University of Health and Allied Sciences-Bugando (CUHAS-Bugando), Mwanza Tanzania

²EMD Physician: Department of Emergency Medicine, Bugando Medical Centre (BMC), Mwanza, Tanzania

³Anesthesiologist: Department of Anaesthesiology, Bugando Medical Centre (BMC), Mwanza, Tanzania

⁴Radiologist: Department of Radiology, Bugando Medical Centre (BMC), Mwanza, Tanzania

⁵Surgeon and project Director: Safe Surgery Project, JHPIEGO, Dar-es- Salaam, Tanzania

⁶Surgeon and Director: Ghana Family Polyclinic, Gastroenterology Unit, Mwanza, Tanzania

Article History

Received: 22.05.2021

Accepted: 28.06.2021

Published: 02.07.2021

Journal homepage:

<https://www.easpublisher.com>

Quick Response Code



Abstract: Background: Untreated constipation can lead to fecaloma loading in colon, stercoral colonic perforation and subsequently stercoral peritonitis. Stercoral peritonitis is relatively uncommon presentation with a grave prognosis. **Case Presentation:** We recently managed a 46-year-old lady known HIV- infected who had a long standing history of constipation. She presented to us with history of acute generalized abdominal pain, fever, vomiting and signs of peritonism for four days. Abdominal radiography showed colonic fecal loading and pneumoperitoneum while abdominal ultrasound demonstrated free fluid in the peritoneal cavity. She underwent emergency exploratory laparotomy in which, we found a perforation at rectosigmoid junction with protruded fecaloma and significant feco-purulent peritoneal fluid. Evacuation of fecolomas, resection of perforated bowel and Hartmann's procedure was done. The patient was sent to a high dependent unit with standard post-operative orders. She unfortunately demised on day 2 post-operatively due to intractable sepsis. **Conclusion:** Fecal impactions should be promptly treated to avoid fatal complications like stercoral peritonitis. Judicious selection of patients with underlying risk conditions like HIV/AIDS for referral and expert definitive management can warrant relatively favorable surgical outcome.

Keywords: Fecal impaction, Stercoral perforation, Peritonitis, HIV.

Copyright © 2021 The Author(s): This is an open-access article distributed under the terms of the Creative Commons Attribution **4.0 International License (CC BY-NC 4.0)** which permits unrestricted use, distribution, and reproduction in any medium for non-commercial use provided the original author and source are credited.

BACKGROUND

Chronic constipation can lead to fecal impaction. If left untreated, it can also rarely lead to catastrophic complications like colonic obstruction, stercoral perforation and peritonitis [1, 2]. Although conservative management is sufficient in most cases of fecal impaction, the possibility of stercoral peritonitis should be considered when patient presents with acute abdominal symptoms. Timely management of stercoral peritonitis by attaining optimal pre-operative preparation; immediate treatment of any underlying sepsis; removal of all stercoral ulcerated diseased colonic tissue; extensive peritoneal lavage; aggressive post-operative management and appropriate treatment of any co-morbid medical conditions can warrant relatively good prognosis.

We report a rare case of neglected fecal impaction in HIV-infected patient leading to stercoral

colonic perforation with fatal peritonitis in Northwestern Tanzania.

CASE PRESENTATION

A 46-year-old lady known HIV-infected for the past nine years was admitted to the Emergency Department (EMD) of Bugando Medical Centre (BMC), a referral, teaching and consultant hospital in Mwanza, Northwestern Tanzania. She presented with history of constipation and abdominal discomfort for three weeks. She has been attending Care and Clinic (CTC) for the past 9 years in a district hospital for routine highly active antiretroviral therapies (HAART) re-fills and Peptic Ulcer Disease (PUD) treatment till four days when her condition deteriorated and started to experience worsening abdominal pain, vomiting and low grade fever prompting her to be admitted at BMC for further management.

Upon arrival at EMD she was full conscious, restless, with a cannula on hand running normal Saline 500mls at the rate of 36 drops per minute and urethral catheter draining concentrated urine volume of 320mls for the past 24 hours. She looked dehydrated with dry mucous membrane, mild pale, febrile with a temperature of 38⁰C, pulse rate (PR) of 92 beats per minute, blood pressure (BP) of 98/78mmHg, Saturation partial Pressure of Oxygen (SPO₂) of 96% in room air, Fasting Blood Glucose (FBG) 7.7mmol/l and respiratory rate (RR) 26/min.

Abdomen was uniformly distended with reduced movement during respiration. She had mild generalized abdominal tenderness on superficial palpation with dough like mass felt on each flank. On deep palpation there was severe tenderness, generalized guarding and marked rebound tenderness. Digital rectal examination revealed hard impacted stool in the rectum. Other systems were essentially normal.

An abdominal radiograph (Figure 1) revealed colonic fecal loading with mottled sign and pneumoperitoneum abdomino-pelvic ultrasound showed colonic fecal loading, absent peristalsis movement and free fluid in the peritoneum. She had electrolyte imbalance with severe Hypokalaemia {Serum-Potassium [K] 1.47 mmol/l, Sodium [Na] 136.95 mmol/l, Chloride [Cl] 96.6 mmol/l and calcium [Ca] 1.9mmol/L}. Complete Blood Cell count (CBC) revealed Normochromic Microcytic Anaemia (Hb 8g/dl), Leucocytosis (WBC 18000mm³). Serum Urea level was normal with an elevated Serum Creatinine (128 mmol/litre).

A diagnosis of peritonitis secondary to perforated hollow viscus; Anaemia and Hypokalaemia in HIV-Seroconverted patient was concluded.

We prepared her for an emergency exploratory laparotomy by rehydration with Ringers Lactate 3 Litres to run in 2 hours, management of severe hypokalaemia as per standard guideline and preoperative management of anemia with blood transfusion. Anaesthesiologist informed to review and later patient taken into operating theatre after attainment of optimal condition for an emergency exploratory laparotomy. She also received Ceftriaxone 1gm and Metronidazole 500mg intravenously 15 minutes before incision as pre-operative antibiotics in line with BMC treatment guidelines.

Intra-operatively, we found a 2cm perforation at anti-mesenteric border of the rectosigmoid junction with an extra-murally protruded fecaloma (Figure-2), whole of colon was distended with palpable fecalomas from ascending colon to rectum and significant feco-purulent peritoneal fluid (about 1.5litres) with fibrinous process matting the ileum to colon. Most parts of bowel were edematous with reduced peristaltic movement.

Inspection of the colon did not reveal clinical features suggestive of neoplasms or diverticula. Other viscera were essentially normal.

An intraluminal lavage was performed and we managed to evacuate fecalomas of about 1.2Kgs, (Figure-3) from the full length of larger bowel through the perforation. Suctioning feco-purulent fluid was done from peritoneal cavity followed by clearing of fibrinous process. Segmental resection of perforated sigmoid colon was done followed by Hartmann's procedure with rectal mucous fistula. Resected segment sent for histopathology examination. Abdominal lavage was done by copious irrigation with 10 litres of warm saline, we succeeded to achieve haemostasis and abdominal drainage tube inserted. Inspection of the full length small bowel from the ligament of Treitz to all sides of the mesentery to the ileocecal junction and larger bowel to the distal sigmoid colon was done. There were no any other perforations, obstructions or ischemic changes seen.

Abdominal wall closed using simple interrupted suture by using PDS no 1 to the fascia without skin closure. Estimated blood loss was 200mls and she received one unit (450mls) of whole blood intra-operatively. Patient tolerated well the operation which took 3 hours and later sent to high dependency unit (HDU) following recovery from Anaesthesia.

In HDU, the patient was given intramuscular (IM) Pethidine 50mg 6-hourly for 24hours, Intravenous (IV) Paracetamol 1gram 8-hourly for 2 days, Ringers Lactate and Dextrose Saline IV 4.5 litres in 24hours, KCL20mEq IV in 500mls of 0.9% Normal Saline, Enoxaparin 40mg subcutaneously 12 hourly for 3 days, Ceftriaxone 1gm IV once per days for 5 days, Metronidazole 500mg IV 8hourly for 5days, Pantoprazole 40mg IV 12-hourly for 5 days. We continued to monitor for fluid input and output, BP, PR, RR and SPO₂ after every 2 hours.

She progressed well despite spikes of fever after 6 hours and first day post Laparotomy and we instructed her to resume HAART. Her condition suddenly changed on second day, she become dyspnoeic (RR 27/min), hypotensive (BP 98/68mmhg), sinus tachycardia (PR 123b/min), hypothermia temp (35.0⁰C), Hyperglycaemia (FBG 7.7mmol/l) and SPO₂ 92% in room air. We ordered Arterial Blood Gas (ABG) which showed PH 7.247 and serum electrolytes - [K] 1.5mmol/l, [Na] 153.0 mmol/l and [Cl] 120.0mmol/l.

We had an impression of septic shock and severe Hypokalaemia, blood sample was taken for Blood Culture and Sensitivity as well as control Complete Blood Count (CBC). She was kept warm and given supportive Oxygen therapy 5 to 7 litres per minute and later transferred to Intensive Care Unit

(ICU). We started management of severe hypokalemia again as per standard guideline. Control CBC showed Leukocytosis of 18,000mm³ and thrombocytopenia of Platelets of 80,000 per microliter of blood. Her condition kept on deteriorating and she succumbed 6

hours after being transferred to ICU. Histopathology results of a resected colon revealed a perforation and ulcers along the anti-mesenteric border with features suggestive of acute ischemic necrosis.

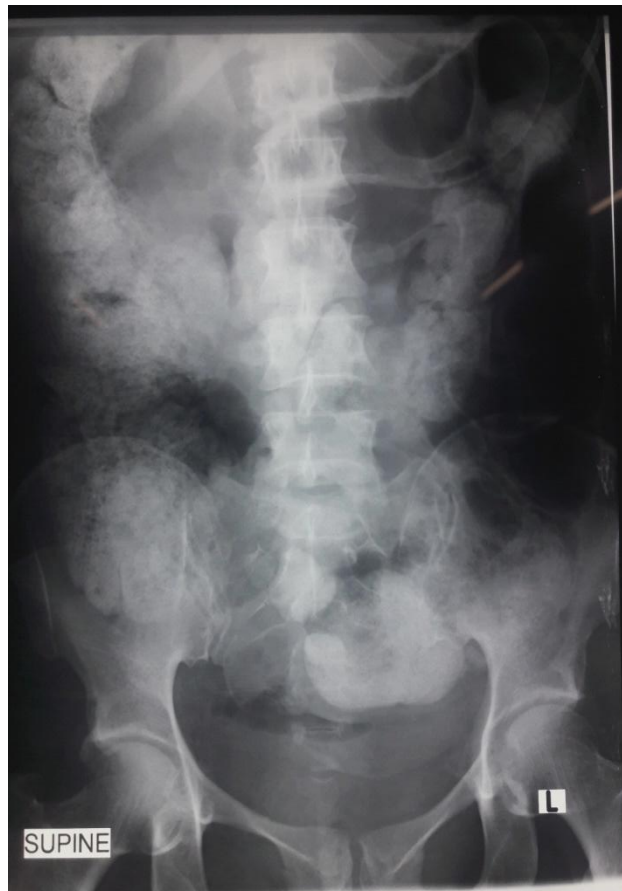

Figure-1: Supine abdomen radiography showed marked large bowel fecal loading with a mottled gas appearance and hyperlucency in the upper abdomen with gas outlining both sides of the bowel wall ('Rigler's sign') in keeping with intra-abdominal free air

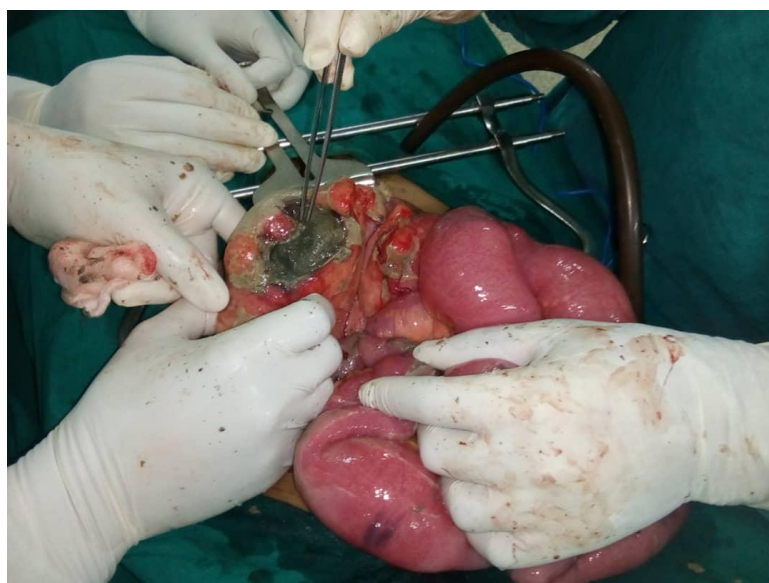


Figure-2: The Image taken intraoperatively showing stercoral perforation at anti-mesenteric border of recto-sigmoid junction with an extramural protruded fecoloma pointed out by a pair of forceps

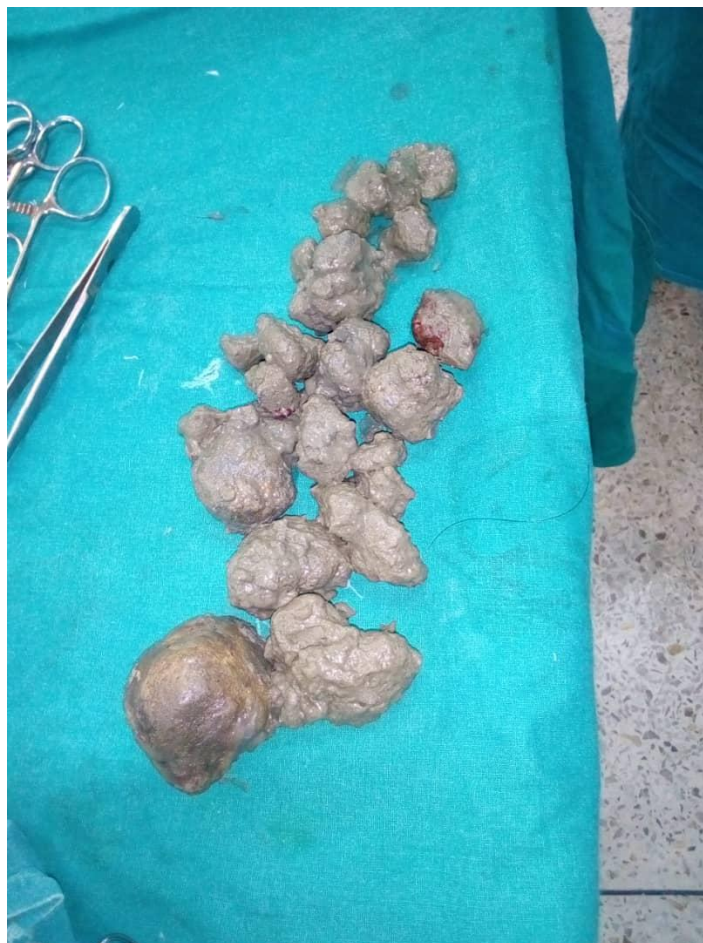

Figure-3: The image showing Fecalomas milked out through a stercoral perforation of HIV-infected patient who had longstanding history of constipation

DISCUSSION AND CONCLUSION

Stercoral colonic perforation is an infrequent acute abdominal emergency occurring due to the pressure effect of hard fecalomas on the wall of an otherwise normal colon, in the absence of any other established pathology [1]. The pathogenesis is due to poor hydration of the feces, resulting in hard and impacted feces, also called fecaloma. Progressive loading of fecaloma in bowel led to increases intraluminal pressure and causes ischemic necrosis of the colonic wall, stercoral ulcer formation, colonic perforation and subsequently stercoral peritonitis [2]. Literature review has revealed that chronic or intermittent constipation has been implicated to be the common cause of fecal impaction that may led to fecalomas [3, 4]. This finding is similar to our case, in which patient had history of constipation for more than three weeks without any appropriate medical or nutritional intervention. The other probable risk for constipation and eventually stercoral ulcer perforation in our patient is the history of longstanding use antacids for treatment of PUD. Erckenbrecht *J et al.*, [5] in their study on effects of high dose antacids on bowel motility, associated use of antacid to constipation and eventually stercoral ulcer perforation. Other risk factors for stercoral ulcer perforation are use of non-steroidal

anti-inflammatory drugs (NSAIDs) or drugs-like Amitriptyline, Steroids, Codeine, and Heroin [5, 6].

Our patient had a perforation on the anti-mesenteric border of the rectosigmoid colon. This is one of the common sites of stercoral ulcer and/or perforation, other anatomical locations are the sigmoid colon and the anterior rectum (just proximal to the peritoneal reflection) [2, 7]. These sites are related to decrease perfusion at the anti-mesenteric border [2, 8] as well the narrow diameter of the distal colon, due to which it is difficult for hard stools to pass through, leading to increased intraluminal pressure and colonic ischemia [8].

Despite the wide range of laboratory and radiographic tests available and their utility in evaluation of abdominal pain, secondary peritonitis remains primarily a clinical diagnosis [9]. In our case patient presented with history of worsening abdominal pain, low grade fever and vomiting which supported with signs of peritonism (tenderness, guarding and rebound tenderness). These are minimal clinical features that warrant a diagnosis of peritonitis in most of resource limited setting. The history of constipation for 3 weeks and palpable hard stool on digital rectal

examination raised suspicion for stercoral peritonitis in our patient.

On imaging, supine abdominal radiographs usually show fecal impaction within the bowel and it can be utilized as confirmatory investigation in most of resource limited setting [10]. As presented in our case report, supine abdominal X-ray showed marked colonic fecal loading with mottled sign and pneumoperitoneum which signified that perforation has already occurred. However, chest x-rays demonstrate free-air under the diaphragm in only 30% of colonic perforations, so we didn't request chest x-ray in our case which is usually ordered in patient with suspected visceral perforation. In resourceful setting, CT of the Abdomen and Pelvis should be considered in cases with suspected stercoral perforation for preoperative diagnosis which has a reported accuracy ranging from 82 and 90% [11].

The principles of management of secondary peritonitis due to stercoral perforation are optimal pre-operative preparation; immediate treatment of any underlying sepsis; removal of all stercoral ulcerated diseased colonic tissue; extensive peritoneal lavage; aggressive post-operative management and appropriate treatment of any co-morbid medical conditions [9, 12]. In our case, we managed to attain optimal condition for emergency laparotomy by resuscitation and adequate correction of electrolyte imbalance. Treatment of intra-abdominal sepsis was achieved by massive saline irrigation and perforation control with the intention of decreasing the bacterial load in the abdominal cavity and deterring the development of overwhelming sepsis which is similar to interventions recommended in literature review [13].

Broad spectrum antibiotics were initiated 15 minutes before incision and continued to be administered as part of post-operative care to combat sepsis caused by polymicrobial peritoneal cavity contamination resulting from intestinal perforation this concurred with several articles [11, 12]. Emergency exploratory laparotomy, resection of segment with perforation and Hartmann's procedure performed in our case. These are recommended surgical interventions that give an optimal clinical outcome and comparatively low mortality as reported in two review articles [14, 15] and one series [16]. In general, septic sequelae and death occur most frequently after anastomosis following colectomy rather than diversion [14].

Stercoral perforation in our case was not purely a surgical condition as it was probably complicated by immuno-compromised state which imparts a poor prognosis [12]. Our patient was known HIV-infected for 9 years and was on medications. We could not manage to get details of her recent CD4 count and viral load. However, studies of the value of viral load and CD4 counts (alone or in combination) in predicting operative morbidity and mortality did not

produce conclusive results and these tests are not ideal for every day practical use [17, 18]. Four factors that have been found to increase operative morbidity and mortality in HIV/AIDS patients are (a) a compromised physiological state - as in general surgery the best predictors of peri-operative morbidity and mortality appear to be scores that measure general health such as ASA (American Society of Anaesthesiology) risk classes or the Korkor's performance scale; (b) physiologically demanding surgery; (c) emergency surgery as opposed to elective procedures and; (d) operations in contaminated fields, such as anorectum or oral cavity [18, 19]. Our patient demised on the second day post operation and she had almost all factors mentioned to increase operative morbidity and mortality. In general, stercoral peritonitis can be life threatening with mortality rates ranging between 32 to 57% [2, 3, 20].

This case report highlights how a neglected fecal impaction can lead to fatal stercoral peritonitis. Early and accurate diagnosis of a preventable and treatable cause such as constipation could have changed the prognosis, reduces resources used and time wasted in management. In our case report, delay in diagnosis and promptly treatment of constipation at the district hospital and late referral when a patient started to manifest with features of peritonitis could have contributed to poor outcome. This reflects the challenging state of health care in our developing world and that need to be addressed by the concerned authorities. We are recommending development of standard operating procedures for emergency surgical conditions that will guide health care workers in district hospitals on initial management and when to refer patient with this kind of condition.

List of abbreviations

BMC: Bugando Medical Centre
CTC: Care and Treatment Clinic
EMD: Emergency Department
HDU: High Dependency Unit
ICU: Intensive Care Unit

DECLARATION

Ethical approval and consent to participate: This case report was approved by institutional ethical review board of Catholic university of Health and Allied Sciences.

Consent for publication: The patient's family gave written consent for their personal, clinical details along with images to be published in this case report.

Availability of data and materials: All patient's information are retained at Medical record Department of Bugando Medical Centre.

Competing interests: The authors declared they have no competing interest

Funding: None

Author's contribution: GG, NS, ES, RS and PN participated in managing patient and prepare manuscript; BT, AH, JS and GM participated in manuscript revision and approved final manuscript.

Acknowledgment: Not applicable

Author's information

Affiliations

1. Department of Surgery, Catholic University of Health and Allied Sciences-Bugando (CUHAS-Bugando), Mwanza Tanzania
2. Department of Emergency Medicine, Bugando Medical Centre (BMC), Mwanza, Tanzania
3. Department of Anaesthesiology, Bugando Medical Centre (BMC), Mwanza, Tanzania
4. Department of Radiology, Bugando Medical Centre (BMC), Mwanza, Tanzania
5. Safe Surgery Project, JHPIEGO, Dar-es-Salaam, Tanzania
6. Ghana Family Polyclinic, Gastroenterology Unit, Mwanza, Tanzania

REFERENCES

1. Arvind, N., Gowrisankar, A., & Rajkumar, J. (2006). Primary stercoral perforation of the colon-Rare.. but deadly!. *Indian Journal of Surgery*, 68(1), 56.
2. Heffernan, C., Pachter, H. L., Megibow, A. J., & Macari, M. (2005). Stercoral colitis leading to fatal peritonitis: CT findings. *American Journal of Roentgenology*, 184(4), 1189-1193.
3. Celayir, M. F., Köksal, H. M., & Uludag, M. (2017). Stercoral perforation of the rectosigmoid colon due to chronic constipation: a case report. *International journal of surgery case reports*, 40, 39-42.
4. Serpell, J. W., & Nicholls, R. J. (1990). Stercoral perforation of the colon. *Journal of British Surgery*, 77(12), 1325-1329.
5. Erckenbrecht, J., Kienle, U., Zöllner, L., & Wienbeck, M. (1982). Effects of high dose antacids on bowel motility. *Digestion*, 25(4), 244-247.
6. Tessier, D. J., Harris, E., Collins, J., & Johnson, D. J. (2002). Stercoral perforation of the colon in a heroin addict. *International journal of colorectal disease*, 17(6), 435-437.
7. Patel, V. G., Kalakuntla, V., Fortson, J. K., & Weaver, W. L. (2002). Stercoral perforation of the Sigmoid colon: Report of a rare case and its possible association with nonsteroidal anti-inflammatory drugs/Discussion. *The American surgeon*, 68(1), 62.
8. Huang, W. S., Wang, C. S., Hsieh, C. C., Lin, P. Y., Chin, C. C., & Wang, J. Y. (2006). Management of patients with stercoral perforation of the sigmoid colon: report of five cases. *World journal of gastroenterology: WJG*, 12(3), 500-503.
9. Ross, J. T., Matthay, M. A., & Harris, H. W. (2018). Secondary peritonitis: principles of diagnosis and intervention. *Bmj*, 361.
10. Kanwal, D., Attia, K. M. E., Fam, M. N. A., Khalil, S. M. F., & Alblooshi, A. M. (2017). Stercoral perforation of the rectum with faecal peritonitis and pneumatosis coli: A case Report. *Journal of radiology case reports*, 11(3), 1-6.
11. Kim, S. H., Shin, S. S., Jeong, Y. Y., Heo, S. H., Kim, J. W., & Kang, H. K. (2009). Gastrointestinal tract perforation: MDCT findings according to the perforation sites. *Korean journal of radiology*, 10(1), 63-70.
12. Huang, W. S., Wang, C. S., Hsieh, C. C., Lin, P. Y., Chin, C. C., & Wang, J. Y. (2006). Management of patients with stercoral perforation of the sigmoid colon: report of five cases. *World journal of gastroenterology: WJG*, 12(3), 500-503.
13. Mandell. (2000). Principles and Practice of Infectious Diseases, 5th ed., Churchill Livingstone Inc: 824-837.
14. Maurer, C. A., Renzulli, P., Mazzucchelli, L., Egger, B., Seiler, C. A., & Büchler, M. W. (2000). Use of accurate diagnostic criteria may increase incidence of stercoral perforation of the colon. *Diseases of the colon & rectum*, 43(7), 991-998.
15. Guyton, D. P., Evans, D., & Schreiber, H. (1985). Stercoral perforation of the colon. Concepts of operative management. *The American surgeon*, 51(9), 520-522.
16. Serpell, J. W., & Nicholls, R. J. (1990). Stercoral perforation of the colon. *Journal of British Surgery*, 77(12), 1325-1329.
17. Albaran, R. G., Webber, J., & Steffes, C. P. (1998). CD4 cell counts as a prognostic factor of major abdominal surgery in patients infected with the human immunodeficiency virus. *Archives of Surgery*, 133(6), 626-631.
18. Smit, S. (2010). Guidelines for surgery in the HIV patients continuous medical education (CME), 28(8).
19. Miles, A. J. G., & Wastell, C. (1991). AIDS and the general surgeon. *Recent Adv Surg*, 14:85-98.
20. Serpell, J. W., & Nicholls, R. J. (1990). Stercoral perforation of the colon. *Journal of British Surgery*, 77(12), 1325-1329.

Cite This Article: Geofrey Giiti et al (2021). Neglected Fecal Impaction in HIV- Infected Patient leading to Stercoral Colonic Perforation with Fatal Peritonitis: A Case Report. *East African Scholars J Med Surg*, 3(7), 118-123.