

Case Report

An Iliopsoas Abscess Case with 6 Years Follow-Up and Literature Review

Yangliang Huang^{1*} and Yi Zhong²¹Department of Spine Surgery, the First Affiliated Hospital, Sun Yat-Sen University, Guangzhou, 510700, China²Key Laboratory of Neuroscience, School of Basic Medical Science, Guangzhou Medical University, Guangzhou, 511436, China

Article History

Received: 23.05.2021

Accepted: 29.06.2021

Published: 04.07.2021

Journal homepage:

<https://www.easpublisher.com>

Quick Response Code



Abstract: Iliopsoas abscess (IPA) has been deemed a rare clinical entity. Traditionally, IPA has been classified as primary if no adjacent anatomic structure could be identified as the source of infection. Primary abscesses were thought to arise from hematogenous seeding of a bruised muscle and were more frequent in younger, active, male patients. Abscesses classified as secondary occur by direct spread from adjacent structures. The most frequent cause of secondary IPA listed in medical literature continues to be intra-abdominal disease, while new cases series implicating that most cases are related to skeletal infections. We report a case of a 40-year-old man complaining of recurrent fever and lumbar dermal sinuses. He was diagnosed as primary iliopsoas abscess and received surgical debridement. However, the symptom was not improved. He kept on receiving several debridements in the next 4 years with no recovery. Gradually, severe dynamic pain and local lumbar kyphosis were developed by abscess induced spine spondylodiscitis. He received no more surgical intervention except conservative antibiotic treatment of meropenem for 6 weeks. Then, the symptoms were significantly improved. He had no more sinuses or fever recurrence. 2 years later, the patient complains nothing except some numbness at lower limbs numbness. Orthosis is suggested while walking or sitting.

Keywords: Iliopsoas; abscess; spondylodiscitis; debridement; antibiotic treatment.

Copyright © 2021 The Author(s): This is an open-access article distributed under the terms of the Creative Commons Attribution 4.0 International License (CC BY-NC 4.0) which permits unrestricted use, distribution, and reproduction in any medium for non-commercial use provided the original author and source are credited.

INTRODUCTION

Iliopsoas abscess (IPA), a suppurative collection within the compartment of the psoas and iliacus muscles, was first reported by Mynter et al. in 1881 [1]. It is an infrequent but potentially life-threatening infectious disease. Prior to introduction of effective anti-tuberculosis drugs, IPA was once a common complication of tuberculous spinal infection. With the common application of anti-tuberculosis drugs, non-tuberculous pyogenic IPA has become the predominant form. Clinically, IPA is classified according to its origin [2]. Primary IPA is thought to be secondary to an unrecognized staphylococcal bacteremia, while secondary IPA is caused by underlying conditions such as gastrointestinal or genitourinary tract diseases, spread of infection from postoperative aortic aneurysm, spondylodiscitis, osteomyelitis, septic arthritis, and infection subsequent to renal surgery [1, 3]. Primary IPA is often seen in younger patients and in developing or tropical countries, while secondary IPA occurs more frequently in developed countries with mixed enteric flora [2]. In recent decades, the incidence of primary IPA has gradually increased as numbers of intravenous drug-

abusers and those afflicted with human immunodeficiency virus (HIV) infection increase [1, 4].

Overall the literature now suggests that many small abscesses can be managed with antibiotics alone and that of those abscesses which do require drainage the majority can be aspirated effectively via CT guidance [5]. Antibiotic therapy should be tailored to the organism/organisms isolated. Surgery was suggested when there was original concurrent intra-abdominal or retroperitoneal abnormalities such as ruptured appendicitis or ruptured infected aortic aneurysm [6]. We report a primary iliopsoas abscess who was initially managed by surgical debridements and ended up with failure, however, conservative strong antibiotic treatment was successful.

CASE REPORT

History

A 40-year-old man with history of 12 months of recurrent fever and right lumbar dermal sinuses presented to our department. He had unstable right local lumbar pain accompanied with frequently febrile. The lumbar pain can not be relieved by any spinal movement or posture. Bed rest could not improve the

symptom. Initially, he had consulted medical attention at local hospital, and received MRI exam. The result reviewed a hyperintense changes on T2-weighted images in the psoas muscle with a small fluid tract communicated with lumbar skin. There was no spondylodiscitis signs. Since he had no history or presentation of intra-abdominal or retroperitoneal abnormalities. He was diagnosed as primary iliopsoas abscess. After anti-biotic therapy of 3 weeks with no improvement, he received debridement surgery. The bacterial culture was achromobacter xyloxydans. The symptoms were improved after surgery: wound was healed without sinuses; pain and febrile disappeared. However, 6 months later, the symptoms relapsed. Another round of antibiotic therapy and surgical intervention were performed. He was symptom free for another 6 months. Then, he was refer to our department when he complained increased lumbar pain and frequency of febrile. Except diabetes which controlled by per oral medicines, he denied any other systemic diseases.

Examinations

Physical examination revealed a small sinuses opening with secretions located at the right upper lumbar region. There was obvious tenderness. No complain about bowel movement or dysuria function was recorded. The manual muscle strength demonstrated 5/5 strength on the left and 5/5 on the right. Increase of deep tendon reflex was not noted. Babinski sign was not positive bilaterally. Muscle tonus of lower extremities was not increased. Sensory function was normal.

X-ray images showed no pathological destruction and loss of spinal column support. MRI scans revealed a hyperintense changes on T2-weighted images in the psoas muscle with a small fluid tract communicated with lumbar skin. No spondylodiscitis signs could be discovered by MRI scans. Laboratory examinations consisted of complete blood count, electrolytes, liver, renal function tests, urinalysis. Except increased ESR, CRP, blood sugar, and white blood cells, they were all normal. (Fig.1)

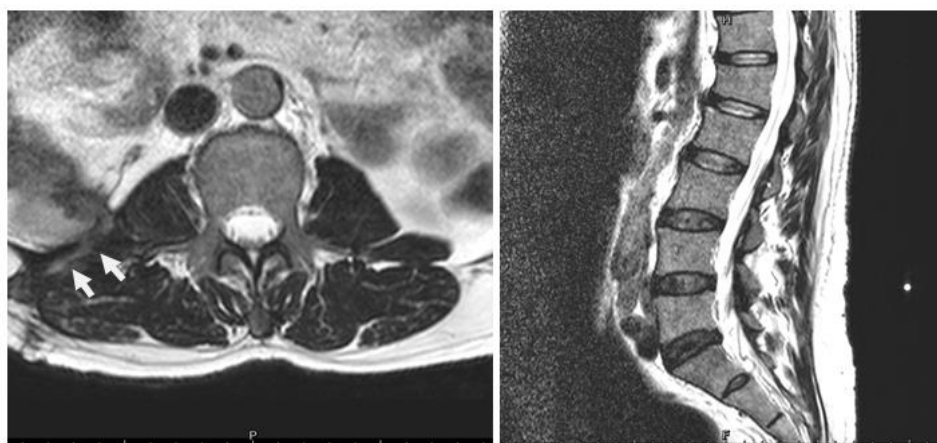


Fig-1: Hyperintense changes on T2-weighted images in the psoas muscle with a small fluid tract (white arrow) communicated with lumbar skin. No spondylodiscitis could be seen.

Surgical treatment

After antibiotic therapy for another 3 weeks with no improvement, we performed another round of debridement surgery. After general anesthesia, the patient was placed lie on left side. The incision was made according to the original. Follow the sinuses tract, suppuration could be found among the psoas muscles. The lower pole of kidney could be touched by finger. However, the pus had no communication with skeleton structures. Inflammatory tissues were eliminated. The cavity was washed with iodophor and saline. The wound was closed with standard multi-layer fashion. The bacterial culture was the same with local hospital: achromobacter xyloxydans, with was sensitive to levofloxacin or ceftriaxone.

Postoperative course

10 days later, his wound was healed without sinuses. Pain and febrile disappeared. He was discharge

home after another 3 weeks of antibiotic therapy. 8 months later, the symptoms relapsed for another time. He came back to our hospital for medical attention. Tuberculosis infection was suspected. A year of anti-tuberculosis medicine was prescribed. During this time, his symptom repeatedly emerged. Once he had fever, he admitted in local hospital for antibiotic therapy. Since the fever was very server for some time, steroid was used. After a year of follow-up, there was no obvious recovery, debridement surgery was performed at the local hospital. His symptoms vanished for another half a year. When the symptom returned, X-ray indicates the local kyphosis of lumbar spine. MRI image findings suggested spondylodiscitis. He was referred to our national infection specialized hospital. He had stay in the hospital for 6 weeks and received meropenem. After strong antibiotic therapy, his symptoms totally disappeared. After follow-up for 2 years, he is symptom free (Fig.2).

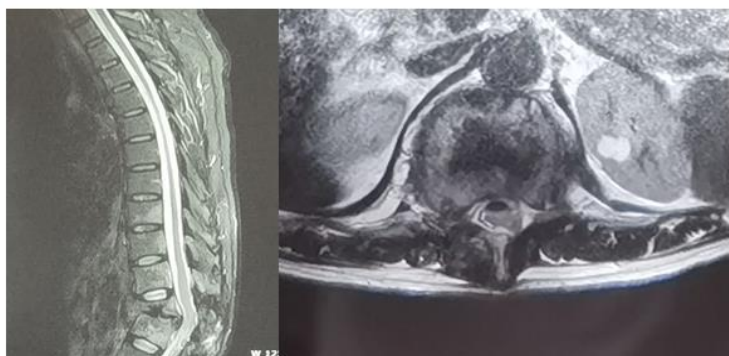

Fig-2: Iliopsoas abscess induced spondylodiskitis and local kyphosis.

The design and performance of this study conformed to ethical standards of Helsinki Declaration and our national legislation. It was approved by Medical Ethical Committee of our institution. The patient was enquired whether or not willing to take part in a scientific report and informed consent forms were signed by himself.

DISCUSSION

Iliopsoas abscess (IPA), a suppurative collection within the compartment of the psoas and iliacus muscles, was first reported by Mynter et al. in 1881 [1]. Iliopsoas muscles are susceptible to infections from distant sites and contiguous structures because of their rich blood supply and overlying retroperitoneal lymphatic systems. IPA is often overlooked because of its insidious onset, and subsequent severe sepsis may be life threatening. Although the exact incidence of IPA is unknown, more and more cases are being identified because of widespread application of CT in suspected IPA patients. Primary IPA is thought to be secondary to an unrecognized staphylococcal bacteremia, while secondary IPA is caused by underlying conditions such as gastrointestinal or genitourinary tract diseases, spread of infection from postoperative aortic aneurysm, spondylodiskitis, osteomyelitis, septic arthritis, and infection subsequent to renal surgery [1, 3]. Mirroring the evolution of vertebral osteomyelitis, *M tuberculosis* as the predominant organism has largely been replaced by *S aureus* [4].

The term iliopsoas abscess is, somewhat of a misnomer. The iliopsoas muscle is comprised of 2 distinct muscles, the psoas and the iliacus muscle. The psoas muscle attaches proximally at the lateral side and transverse processes of the lumbar vertebrae and corresponding intervertebral discs (T12-L5) [7]. The origin of the iliacus muscle is formed by the hollow iliac fossa, the upper sacrum, and the sacroiliac (SI) and iliolumbar ligaments between them. Each muscle is enveloped in its respective fascia that share a tendon attachment site on the lesser trochanter [8-10]. Newer data emphasize that abscesses in the iliopsoas compartment most frequently arise from adjacent skeletal structures. Psoas muscle abscesses (PMAs) are

most frequently secondary to spondylodiskitis of the lumbar spine. Iliacus muscle abscesses (IMAs) are caused by spread of infection from the SI joint or the hip. Patients with lumbar spine spondylodiskitis and secondary PMA can present with back pain and hip pain. They are frequently febrile. A few patients present with the full psoas abscess triad with fever, back pain, and a limp. The presentation of an IMA is more varied but mostly includes hip pain or buttock pain. Conventional surgical terminology does not differentiate between abscesses located in the iliacus or psoas muscle, yet the causes, clinical picture, and outcomes differ significantly [11-13].

Routine laboratory investigations including full blood count, C-reactive protein, and erythrocyte sedimentation rate are useful in confirming the diagnosis of an inflammatory mass. Formal imaging is required however not only to confirm the diagnosis, but to plan further treatment. Plain films that are routinely ordered in the workup of back pain are rather insensitive [14]. A failure to visualize the lateral margin of the psoas muscle on supine abdominal films indicates a retroperitoneal pathologic condition, including PMA, and is labeled as the radiographic psoas sign. On MRI, the psoas sign is known as the look-at-me lesion. The hyperintense changes on T2-weighted images in the psoas muscle correlate highly with lumbar spondylodiskitis and improve diagnostic accuracy on MRI [15-18].

The treatment for IPA is controversial. On one hand, some authors believe that conservative management with antibiotic only is enough for the disease. The agreed first line treatment in the literature is broad spectrum antibiotic that will cover *S. aureus* and also any possible primary source for the IPA [19, 20]. Successful conservative management, with antimicrobial therapy only, of collections ranging from 2.5 to 7.5 cm has been reported [21]. In some authors' experience, IPA secondary to lumbar spondylodiskitis will resolve without drainage over the 6-week course of standard antibiotic therapy given for vertebral osteomyelitis [22]. CT-guided aspiration of PMA is done mainly for diagnostic purposes in spondylodiskitis cases with negative blood cultures at 48 hours. On the

other hand, some authors believe that surgical drainage was the treatment of choice and some authors have described quicker recovery following open drainage. There are still occasions in which open drainage will be preferable such as the IPA which occurs secondary to an intra-abdominal disease process which also requires open surgical intervention. For example complex Chron's disease, infected aortic aneurysm, ruptured appendicitis, or epidural abscess with spinal cord compression. Recently, it has since been established that image guided percutaneous drainage (PCD) is a very safe and effective alternative, but not all of the cases could be cured by PCD, especially when the IPA was gas-forming. Because of the higher failure rate of PCD [23-25].

The failure of surgical treatment of our patient implicated the importance of antibiotic therapy. The antibiotic effectiveness was the foundation of recovery. If the medicine was effective, the symptom improvement should be noticed within one or two weeks. If the therapy was not effective, surgical debridement should not be performed. Our patient had received several times of operations, however, the abscess kept on emerging repeatedly. After 4 year of development, there was obvious spondylodiscitis which induced local kyphosis. 6 weeks of meropenem antibiotic therapy was better than many times of debridement surgery. After follow-up for 2 years, he is almost symptom free.

CONCLUSIONS

Iliopsoas abscess is a kind of infectious disease. The specification of an effective antibiotic medicine is the only way to success. Percutaneous drainage could be used in large abscess to insure a rapid recovery. Surgery is needed only when the abscess occurs secondary to an intra-abdominal disease.

REFERENCES

1. Mallick IH, Thoufeeq MH, Rajendran TP: Iliopsoas abscesses. *Postgrad Med J* 2004, 80(946):459-462.
2. Ruiz de la Hermosa A, Amunategui-Prats I, Hurtado-Caballero E, Cortese S, Munoz-Calero Peregrin A. Psoas abscess due to *Pasteurella multocida*. *Rev Gastroenterol Mex* 2011 Oct;76(4):366e9.
3. Lee SY, Leonard MB, Beart Jr RW, Dozis RR. Psoas abscess: changing patterns of diagnosis and etiology. *Dis Colon Rectum* 1986;29:694e8.
4. Ricci MA, Rose FB, Meyer KK. Pyogenic psoas abscess: worldwide variations in etiology. *World J Surg* 1986;10:834e43.
5. Adelekan MO, Taiwo SS, Onile BA. A review of psoas abscess. *Afr J Clin Exp Microbiol* 2004 Jan;5(1):55e63.
6. van den Berge M, de Marie S, Kuipers T, Jansz AR, Bravenboer B. Psoas abscess: report of a series and review of the literature. *Neth J Med* 2005 Nov;63(10):413e6.
7. Walsh TR, Reilly JR, Hanley E, Webster M, Peitzman A, Steed DL. Changing etiology of iliopsoas abscess. *Am J Surg* 1992;163(4):413e6.
8. Levin MJ, Gardner P, Waldvogel FA. An unusual infection due to *Staphylococcus aureus*. *N Engl J Med* 1971 Jan 28;284(4):196e8.
9. Taiwo B. Psoas abscesses: a primer for the internist: case report. *South Med J* 2001;94:78e80.
10. Van Dongen LM, Lubbers EJC. Psoas abscess in Crohn's disease. *BJS* 2005;589e 90.
11. Hong SH, Choi JY, Lee JW, et al. MR imaging assessment of the spine: infection or an imitation? *Radiographics* 2009;29(2):599-612.
12. Godfrin-Valnet M, Godfrin G, Godard J, et al. Eighteen cases of crowned dens syndrome: presentation and diagnosis. *Neurochirurgie* 2013;59(3):115-20.
13. Bernard L, Dinh A, Ghout I, et al. Antibiotic treatment for 6 weeks versus 12 weeks in patients with pyogenic vertebral osteomyelitis: an open-label, non-inferiority, randomised, controlled trial. *Lancet* 2015;385(9971):875-82.
14. Park KH, Cho OH, Lee JH, et al. Optimal duration of antibiotic therapy in patients with hematogenous vertebral osteomyelitis at low risk and high risk of recurrence. *Clin Infect Dis* 2016;62(10):1262-9.
15. Rankine JJ, Barron DA, Robinson P, et al. Therapeutic impact of percutaneous spinal biopsy in spinal infection. *Postgrad Med J* 2004;80(948):607-9.
16. Zimmerli W. Clinical practice. Vertebral osteomyelitis. *N Engl J Med* 2010; 362(11):1022-9.
17. Dagirmanjian A, Schils J, McHenry M, et al. MR imaging of vertebral osteomyelitis revisited. *AJR Am J Roentgenol* 1996;167(6):1539-43.
18. Ledermann HP, Schweitzer ME, Morrison WB, et al. MR imaging findings in spinal infections: rules or myths? *Radiology* 2003;228(2):506-14.
19. Dunbar JA, Sandoe JA, Rao AS, et al. The MRI appearances of early vertebral osteomyelitis and discitis. *Clin Radiol* 2010;65(12):974-81.
20. Palestro CJ, Torres MA. Radionuclide imaging in orthopedic infections. *Semin Nucl Med* 1997;27(4):334-45.
21. Love C, Patel M, Lonner BS, et al. Diagnosing spinal osteomyelitis: a comparison of bone and Ga-67 scintigraphy and magnetic resonance imaging. *Clin Nucl Med* 2000;25(12):963-77.
22. Ohtori S, Suzuki M, Koshi T, et al. 18F-fluorodeoxyglucose-PET for patients with suspected spondylitis showing Modic change. *Spine (Phila Pa 1976)* 2010; 35(26):E1599-603.
23. Mylona E, Samarkos M, Kakalou E, et al. Pyogenic vertebral osteomyelitis: a systematic review of clinical characteristics. *Semin Arthritis Rheum* 2009;39(1):10-7.
24. De Lucas EM, Gonzalez Mandly A, Gutierrez A, et al. CT-guided fine-needle aspiration in vertebral osteomyelitis: true usefulness of a common practice. *Clin Rheumatol* 2009;28(3):315-20.
25. Kim CJ, Song KH, Park WB, et al. Microbiologically and clinically diagnosed vertebral osteomyelitis: impact of prior antibiotic exposure. *Antimicrob Agents Chemother* 2012;56(4):2122-4.

Cite This Article: Yangliang Huang & Yi Zhong (2021). An Iliopsoas Abscess Case with 6 Years Follow-Up and Literature Review. *East African Scholars J Med Surg*, 3(7), 132-135.