

## Research Article

## Ultrasound, Elastography and MRI Mammography Correlation in Breast Pathologies (A Study of 50 Cases)

Dr Hiral Parekh.<sup>1</sup>, Dr Lata Kumari.<sup>2</sup>, Dr Dharmesh Vasavada.<sup>3</sup>

1Professor, Department of Radiodiagnosis M P Shah Government Medical College Jamnagar, Gujarat, India

2Resident Doctor in Radiodiagnosis Department of Radiodiagnosis M P Shah Government Medical College Jamnagar, Gujarat, India

3Professor, Department of Surgery M P Shah Government Medical College Jamnagar, Gujarat, India

\*Corresponding Author

Dr Dharmesh Vasavada

**Abstract: Introduction:** The purpose of this study is to investigate the value of MRI in comparison to US and mammography in diagnosis of breast lesions. MRI is ideal for breast imaging due to its ability to depict excellent soft tissue contrast. **Methods:** This study of 50 cases was conducted in the department of Radiodiagnosis, Guru Gobinsingh Government Hospital, M P Shah Government Medical College, Jamnagar, Gujarat, India. All 50 cases having or suspected to have breast lesions were chosen at random among the indoor and outdoor patients referred to the Department of Radiodiagnosis for imaging. **Discussion:** In the present study the results of sonoelastography were compared with MRI. The malignant masses were the commonest and the mean age of patients with malignant masses in our study was 45 years, which is in consistent with Park's statement that the mean age of breast cancer occurrence is about 42 years in India<sup>3</sup>. Painless lump in the breast was the common presenting feature in these patients and involvement of upper outer quadrant was the most common site. **Conclusion:** Ultrasonography is noninvasive, low cost, rapid method for detection, localization and for differentiation of breast pathology. Usefulness of breast elastography has been confirmed particularly in small nodules, complex cysts or cysts with a corpuscular content. MRI due to its noninvasive, non- irradiating and multiplanar capability has significantly improved the diagnostic efficacy in early detection of breast lesions. Although MRI is time consuming and costly affair.

**Keywords:** Breast Lump, Mammography, Elastography.

### INTRODUCTION

Breast cancer is the most common female cancer worldwide representing nearly a quarter (25%) of all cancers with an estimated 1.67 million new cancer cases diagnosed in 2012. Women from less developed regions have slightly more number of cases compared to more developed regions. In India, although age adjusted incidence rate of breast cancer is lower (25.8 per 100 000) than United Kingdom (95 per 100 000) but mortality is at par (12.7 vs 17.1 per 100 000) with United Kingdom. There is a significant increase in the incidence and cancer-associated morbidity and mortality in Indian subcontinent as described in global and Indian studies. As per the data from National and regional cancer registries, it is the commonest cancer amongst women in Delhi, Mumbai, Ahmedabad, Kolkata and Trivandrum. In all other Indian registries, it is the 2nd most common cancer in women (Sinha, R. *et al.*, 2003). Breast cancer occurs a decade earlier in India

than in western women. The mean age of occurrence is about 42 years in India, as compared to 53 years in the west (Park, K. 2007).

At present various imaging modalities are available for evaluation of lesions i e, mammography, ultrasonography, color Doppler, breast galactography and MRI.

Ultrasonography (US) is the most widely used adjunctive tool in breast diagnostics. The most important role of US has been to determine whether a lesion is solid or cystic. The diagnostic accuracy in solid lesions has been considerably lower, although some morphologic criteria have been presented for classifying solid lesions as benign or malignant (Stavros, A. T. *et al.*, 1995). The value of US in differentiating between benign and malignant lesions is still controversial because of overlapping sonographic

Quick Response Code



Journal homepage:

<http://www.easpublisher.com/easjrit/>

Article History

Received: 10.03.2019

Accepted: 25.03.2019

Published: 10.04.2019

**Copyright © 2019 The Author(s):** This is an open-access article distributed under the terms of the Creative Commons Attribution 4.0 International License (CC BY-NC 4.0) which permits unrestricted use, distribution, and reproduction in any medium for non-commercial use provided the original author and source are credited.

DOI: 10.36349/easjrit.2019.v01i02.003

characteristics and the high inter observer variability (Chao, T. C. *et al.*, 1999). It appears to be more accurate than mammography for determining actual tumor size. However it is less reliable in differentiating between benign and malignant solid lesions (Rahbar, G. *et al.*, 1999). The detection of invasive lobular carcinoma on mammography and ultrasonography is also difficult because of its growth pattern and low density of the lesion.

Ultrasound elastography (USE) was introduced to increase the accuracy of characterizing breast lesions. When a certain amount of force is applied in a tissue, elastic deformation occurs. Sono-elastography is a technique that applies compression to detect stiffness variation within the scanned tissues. Cancerous lesions are stiffer than non-cancerous ones. Ultrasound elastography uses this principle to differentiate malignant breast lesions from benign lesion on compression. USE holds promise in improving the differentiation of benign from malignant breast lesions (Mumtaz, H. *et al.*, 1997; Fischer, U. *et al.*, 1999).

Recently MRI has been added to the list of imaging modalities for evaluation of breast lesions. MRI is ideal for breast imaging because it is noninvasive, non-irradiating and 3-dimensional modality. MRI has been found to be more accurate in detection of lesions with dense breast tissue and in better differentiation of malignant and benign lesions. MRI better defines the extent and the presence of multifocal and multicentric disease, better than mammography. In dealing with lesions that remain equivocal after mammographic and sonographic evaluation, MR imaging could be the problem solving method (Lee, C. H. *et al.*, 1999). MRI caters to the need of breast conservation surgery by defining the exact margins of tumors thus decreasing the recurrence rate. It is the best method for detecting an otherwise occult primary breast carcinoma in patients with axillary node metastases (Orel, S. G. *et al.*, 1995).

After diagnosis of a malignant lesion, MR imaging is the most sensitive tool for preoperative staging and treatment planning (Mumtaz, H. *et al.*, 1997; Fischer, U. *et al.*, 1999; & Weinstein, S. P. *et al.*, 2001). MR imaging is a diagnostic modality of choice in post treatment surveillance in conservatively treated breasts with suspected recurrence and evaluation of tumor responses to chemotherapy (Müller, R. D. *et al.*, 1998; . Viehweg, P. *et al.*, 1998).

The purpose of this study is to investigate the value of MRI in comparison to US and mammography in diagnosis of breast lesions. MRI is ideal for breast imaging due to its ability to depict excellent soft tissue contrast.

MRI is also used to assess axillary lymph node metastasis. The dynamics of contrast enhancement based on time-signal intensity curves are evaluated, which are compared to histopathology. Contrast enhanced dynamic MRI have been found to be more accurate in detection of malignancy within dense breast tissue, differentiation of malignancy versus scarring. In MRI examination, both lesion morphology and time-signal intensity curves are evaluated.

#### **AIMS AND OBJECTIVES**

The present study was aimed at studying the role of MRI in patients with breast lesions and comparison with Ultrasonography and mammography with emphasis on:

- Early detection of breast lesion.
- Better characterization of a lesion.
- Local invasion, multimodality, multicentricity and intraductal spread of tumor.
- To define the exact tumor margins before breast conserving surgery and adjuvant therapy.

#### **MATERIALS AND METHOD**

- The present study was conducted in the department of Radiodiagnosis of our institute 50 cases having or suspected to have breast lesions were chosen at random among the indoor and outdoor patients referred to the department of Radiodiagnosis for imaging.
- Results will be checked by two radiologists (PI and CO-PI) and final comparative data will be given between Ultrasonography and Magnetic Resonance Imaging.

#### **INCLUSION CRITERIA:**

- Pain/discomfort in breasts.
- Discharge from nipple.
- Palpable breast lesion.
- Non palpable suspicious lesion on mammography.
- Nonspecific axillary lymphadenopathy.
- Family history of breast carcinoma.

#### **EXCLUSION CRITERIA:**

- Patients in which MRI was contraindicated.

**Description of Tools:**

**A. Clinical:** all the patients will be subjected to detailed clinical history and examination as outlined in proforma.

**B. Radiological investigations:**

**SONO- ELASTOGRAPHY**

**Ultrasonography Machine:**

Esaote My Lab 60: Curvilinear probe

- Linear Probe

Phillips Affinity 50: Curvilinear probe

- Linear Probe

- No patient preparation is required. Almost all of patients studied in supine position.

- All patients were subsequently subjected to real time ultrasound scanning with 7.5 MHz linear array transducer on “Phillips Affinity 50” machine. Patient was scanned supine with the hands behind her head. Patient is turned to contra-lateral side to examine the more lateral portion of the breast. A gray scale image of the mass was acquired.

- **Measured variables included:**

Size of the mass on B mode: Size was measured by taking the length and width of the mass.

- **BI-RADS classification: This was classified based on the interpretation of the image :**

Using the same probe, elasticity of a tissue was assessed by gently compressing the mass repetitively with the ultrasound probe. Elastography strain image was then acquired and displayed side by side with the gray scale image.

**Elasticity Score in Breast Cancer Diagnosis:**

The elasticity score is a five-point scale used to classify elastography patterns from benign to malignant as follows:

- score 1 (benign)
- score 2 (probably benign)
- score 3 (benign or malignant are equivocal),
- score 4 (malignancy suspected)
- score 5 (malignancy strongly suggested)

**ELASTOGRAPHY STRAIN RATIO - :**

1. Even strain for entire lesion displayed as green.
2. Strain in most of the lesion with some areas of no strain, Inhomogeneous elasticity - displayed with green and blue
3. Strain in the periphery of the lesion with sparing of the centre-displayed as green - Periphery with blue centre.
4. No strain in entire lesion entire lesion - displayed as blue
5. No strain in entire lesion and surrounding area entire lesion and surrounding area - displayed as blue.

- Strain ratio was then calculated for all lesions by selecting a region of interest (ROI) on the mass and a corresponding ROI of the adjacent adipose tissue.

- Using specific software, the SR value was displayed on a static image. A cut-point of  $\geq 4$  for Malignant lesions was used.

- All cases were subjected to MRI of breast on “Siemens Magnetom essenza 1.5 tesla” machine using a double CP breast array coil.

**ELASTOGRAPHY**

	Score	Pattern	Elastogram	B-mode	
Benign	1				Entire hypoechoic area is soft
	2				Part of hypoechoic area is hard
	3				Only inside of margin of hypoechoic area is soft
Malignant	4				Entire hypoechoic area is hard
	5				Hypoechoic area and surrounding area are hard
BGR					In the case of cysts, a specific blue-green-red pattern (BGR sign) is seen

**MAGNETIC RESONANCE IMAGING SYSTEM CONSISTS OF THE FOLLOWING SEQUENCES:**

**Magnetic Resonance Imaging Machine:**

- 1.5 T Magnetom Essenza Siemens, 16 channels.

**PROTOCOL USED**

Patient position	-	prone.
Slice thickness	-	1.2 mm
Matrix size	-	288 x 384
Field of view	-	340
Gadolinium based contrast agent was given intravenously.		
Volume		20 ml
Flow rate		2-3 ml/sec followed by 20 ml saline solution flush.

1. T2WI, STIR axial, sagittal and coronal images obtained.(TR 9000 and TE 69 ms).

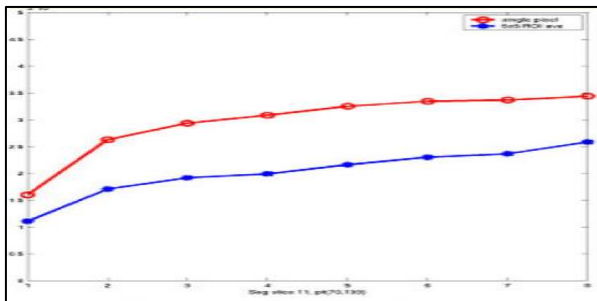
2. T1 flash axial 3D fat saturation 1 pre and 5 post images obtained:

Then T1 -f13d- tra- dyna views 1+5 sequence obtained before and 25 sec, 60sec, 100 sec, 3 min, and 5 min after the start of i.v. injection .

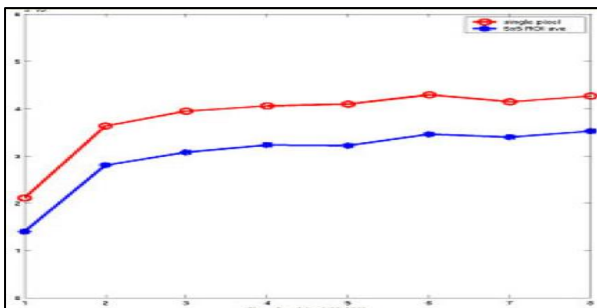
**IMAGING PARAMETERS OF SEQUENCE:**

Parameter	(T1-f13d -tra - dynamic views - 1+5)
Slice orientation	Axial
TR/TE	5.03/1.88
Flip angle	10 degree
Bandwidth (Hz/pixel)	350 Hz/Px
Field of View	330 mm
FOV phase	0.9 mm
Voxel size	[1x0.9x0.9] mm

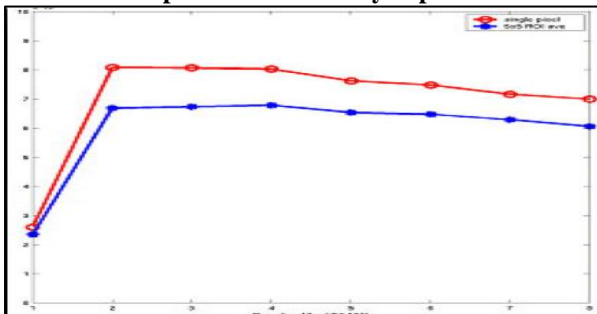
In MRI ROI are graded as below-



**Type 1: Curve with slow rise and a continued rise with time**



**Type 2: A slow or rapid initial rise followed by a plateau in the delayed phase.**



**Type 3: Curve with rapid initial rise, followed by washout in the delayed phase**

**STATISTICAL ANALYSIS:**

- Statistical analysis was done by using proportions. The sensitivity, and specificity and positive

predictive values were determined for all cases using the following formulae.

$$\text{Sensitivity} = \frac{TP}{TP + FN} \times 100$$

$$\text{Specificity} = \frac{TN}{TN + FP} \times 100$$

$$\text{PPV} = \frac{TP}{TP + FP}$$

$$\text{NPV} = \frac{TN}{TN + FN}$$

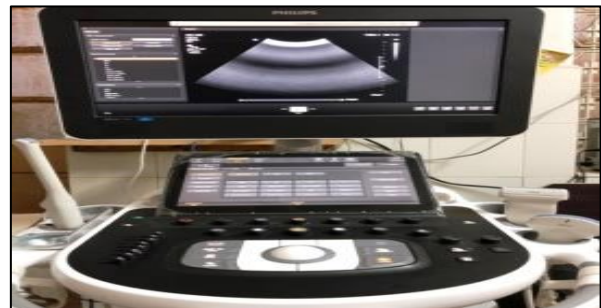**TP = TRUE POSITIVE**

**TN = TRUE NEGATIVE**

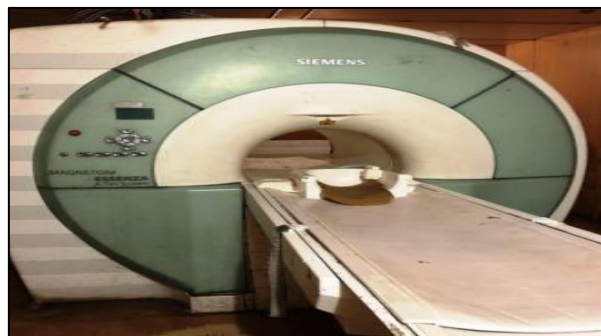**FP = FALSE POSITIVE**

**FN = FALSE NEGATIVE**

**OUR ULTRASOUND MACHINE – PHILLIPS AFFINITI 50**



**OUR MRI MACHINE – 1.5 TESLA SIEMENS MRI**



**ROLE OF IMAGING**

• **ULTRASONOGRAPHY**

It is the most important adjunctive imaging modality for breast lesion diagnosis. Over the years, it has also undergone significant improvements that have extended its utility for breast imaging. Two of the most important clinical advances in breast US have been the development of criteria that allow improved benign/malignant differentiation of solid breast lesions and the use of US to guide interventional procedures such as needle aspirations, core-needle biopsies, and pre-biopsy needle localizations of breast masses or calcifications (Jackson, V. P. 1995). Ease of use and

real-time imaging capability make breast ultrasound a method of choice for guiding breast biopsies and other interventional procedures.

Characteristic ultrasonographic features of a cyst are its round or oval shape, circumscribed margins, anechoic interior, and enhanced distal echoes posterior to the cyst. Continuing improvements in ultrasonography equipment have led to the identification of additional features that may help to differentiate benign from malignant solid masses. These include the shape, margins, and echogenicity of a breast mass (Stavros, A. T. *et al.*, 1995). Ultrasonography can effectively distinguish solid masses from cysts, which account for approximately 25 percent of breast lesions. When strict criteria for cyst diagnosis are met, ultrasonography has a sensitivity of 89 percent and a specificity of 78 percent in detecting abnormalities in symptomatic women (Popli, M. B. 2002).

It is entirely a safe method, and can be used regularly for these purposes. The effectiveness depends on the ability of the radiologist performing the test. Another disadvantage is that it cannot differentiate between certain solid masses and it has poor ability to visualize deep lesions. Breast ultrasound is used in many forms. B-mode is the most common form of imaging for the breast, although compound imaging and harmonic imaging are being increasingly applied to better visualize breast lesions and to reduce image artefacts. These developments, together with the formulation of a standardized lexicon of solid mass features, have improved the diagnostic performance of breast ultrasound (Berg, W. A. *et al.*, 2004).

During a breast ultrasound examination the sonographer or physician performing the test may use Doppler techniques to evaluate blood flow or lack of flow in any breast mass. With the development of ever more sensitive Color Doppler and power Doppler ultrasound machines the ability to detect flow in solid masses and even to differentiate that flow also has added another level of sophistication to ultrasound analysis of breast masses. Therefore Color Doppler is now widely established as a useful addition to breast imaging and dynamic features of ultrasound that are useful in breast diagnosis.

- **ELASTOGRAPHY**

Breast elastography is being increasingly used to better characterize breast lesions. Published studies have shown that it improved specificity of B mode ultrasound. Two elastography modes are available: free-hand elastography and shear wave elastography (Kim, S.-Y. *et al.*, 2015). Free-hand elastography is obtained by a mechanic wave induced by the ultrasound probe, deforming the target; either by small movements induced by breathes. An elastogram is obtained and displayed either as a color map or a size ratio or elasticity ratio measurement.

The second mode is shear wave elastography; two methods are available: Shear Wave Elastography (SWE) and ARFI mode (Acoustic Radiation Force Impulse). Shear wave elastography is less operator-dependent than free-hand elastography mode and provides a quantitative approach. False negatives may occur in soft breast cancers (mucinous carcinoma, carcinoma with an inflammatory stroma, etc.) and false positives may be seen with poorly deformable benign lesions such as old fibrous adenomas.

In practical use, elastography is a useful complementary tool for undetermined breast lesions categorized as BI-RADS 4a or BI-RADS 3, or for cystic lesions but cannot avoid fine needle aspiration or core biopsy if ultrasound features are clearly suspicious (Navarro, B. *et al.*, 2011).

- **MAGNETIC RESONANCE IMAGING**

MRI of the breast offers valuable information about breast conditions that cannot be obtained by other imaging modalities, such as mammography or ultrasound. MRI of the breast is not a replacement for mammography or ultrasound imaging but rather a supplemental tool for detecting and staging breast cancer and other breast abnormalities. New pulse sequences in MRI combined with contrast enhancement kinetic perfusion curves have greatly enhanced detection of mammographically occult cancers. Magnetic resonance imaging (MRI) is very useful in diagnosing breast masses. Gadolinium contrast is used to enhance the vascularity of malignant lesions (Tozaki, M. *et al.*, 2005).

Research suggests two potential roles for MRI in breast mass diagnosis: evaluating patients with silicone breast implants and assessing patients in whom evaluation by ultrasonography and mammography is problematic (Lee, C. H. *et al.*, 1999). The latter group includes patients who have had breast-conserving surgery; patients with known carcinoma in whom multifocal, ipsilateral, or contralateral disease must be ruled out, patients with axillary metastasis and an unknown primary, patients with extensive postoperative scarring, and patients with extremely dense parenchyma. It also has limited sensitivity in detecting ductal carcinoma in situ. MRI of the breast cannot always distinguish between cancer and benign breast disease (such as fibroadenoma), leading to a false positive result.

A benefit of MRI is that it can easily acquire direct views of the breast in any orientation while mammography requires re-orientation of the breast and mammography system for each view desired. An MRI exam of the breast typically takes between 30 and 60 minutes. The injection of a contrast agent can further the ability of MRI to detect a specific feature or in case of dynamic contrast enhancement MRI study, the functionality of tissue. The contrast agents used are

paramagnetic agents with gadolinium (Gd-DTPA) being the most common. The effect of this agent is to shorten the relaxation time of local spins causing a decrease in signal in T2 weighted images and an increase in T1 weighted images. The increased vascularity of tumors produces a preferential uptake of contrast agent and the technique can be used to improve their contrast from surrounding normal tissue (Kuhl, C. 2007). Furthermore if MRI scans are repeatedly acquired following the contrast injection, the dynamic nature of contrast uptake can be examined, which may improve the differentiation of benign and malignant disease. This is called dynamic contrast-enhancement MRI.

A few advantages of MRI of the breast are that it can be used in women with denser breasts, it is non-ionizing, it can take images in any orientation, it can determine multi-focal cancers and it is useful in determining if the cancer has spread to the chest wall (Morris, E. A. *et al.*, 2000). It can also be used to check for recurrence of cancer in women who have undergone lumpectomy. MRI can assess if a newly inverted nipple is a sign of retro-areolar cancer, it can see breast implants and look for ruptures.

The disadvantages are that it is expensive, requires injection of a contrast agent for functional imaging. Specificity can be limited, it is highly sensitive to small abnormalities, and cannot image calcifications and can induce feelings of claustrophobia. It has long scan times in comparison to ultrasonography.

### SONOGRAPHIC ANATOMY

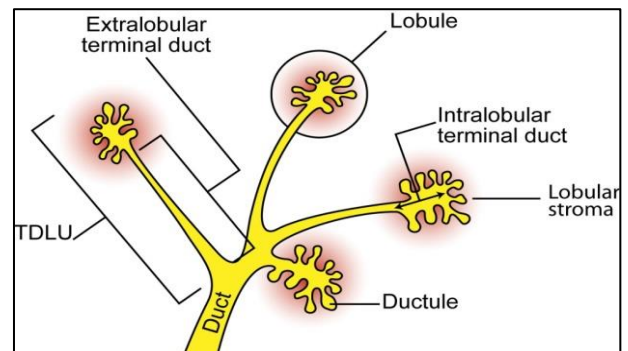
The anatomic components of breast and surrounding structures have characteristic sonographic features. The skin complex is seen as two thin echogenic lines demarcating a narrow hypo echoic band – the dermis. The normal skin measures 0.2 cm in thickness but maybe thicker than the infra-mammary fold.

The nipple is of medium level echogenicity and attenuates sound resulting in a posterior acoustic shadow. Fat lobules are oval in one phase of view and elongated in orthogonal plane. They are hypo echoic relative to glandular tissues. Glandular parenchyma usually appears homogeneously echogenic but may have hypo echoic zones due to fatty tissue. Frequently the glandular tissue is interlaced with small hypo echoic mammary ducts. Cooper's ligaments provide the connective tissue support to the breast. They appear as thin, echogenic arcs.

#### Terminal Duct Lobar Units (TDLU):

A small normal TDLU may not be identified as a discrete anatomic structure. Hyperplastic TDLU appears as hypo echoic areas on ultrasound. The mammary ducts which are readily arranged in 7-20 segments around the nipple demonstrate progressive

luminal enlargements. They converge on the nipple. The ducts appear as tubular structures of size 0.1-0.8 cm in diameter. The mammary tissue is enclosed within a fascia envelope composed of a superficial or deep layer. These may be identified as thin line. The ribs and pectoralis muscle are visible deep to retro mammary layer. The ribs are hypo echoic and periodic structure behind the pectoralis muscle. They attenuate sound causing posterior acoustic shadow. The axillary vessels present as tubular structures which are often seen pulsating. Color flow Doppler can provide information about them. Lymph nodes may be seen in axilla as well as the breast parenchyma. Normal lymph nodes are often uniform and may have an echogenic fatty hilus.



### CLASSIFICATION OF BREAST LUMPS

#### ➤ BENIGN MAMMARY DYSPLASIA :

- Cysts (simple or papillary )
- Adenosis
- Epithelial proliferation
- Ductal ectasia
- Fibro sclerosis
- Gynaecomastia and other

#### ➤ BENIGN OR APPARANTLY BENIGN :

- Adenoma of breast
- Ductal papilloma
- Fibroadenoma
- Benign soft tissue

#### ➤ CARCINOMA OF BRAEST:

- Intraductal and intra-lobular non infiltrating carcinoma
- Infiltrating carcinoma

#### ➤ SPECIAL HISTOPATOLOGICAL VARIANTS:

- 1) Medullary ca.
- 2) Papillary ca.
- 3) Cribriform ca.
- 4) Colloid ca.
- 5) Lobular ca.

- 6) Squamous ca.
- 7) Paget disease of breast.

➤ **BIRADS Assessment categories [92]: Breast imaging reporting and data system**

Category	Management	Likelihood of cancer	
0	Need additional imaging or prior examinations	Recall for additional imaging and/or await prior examinations	n/a
1	Negative	Routine screening	Essentially 0%
2	Benign	Routine screening	Essentially 0%
3	Probably Benign	Short interval-follow-up (6 month) or continued	>0% but ≤ 2%
4	Suspicious	Tissue diagnosis	4a. low suspicion for malignancy (>2% to ≤ 10%)
			4b. moderate suspicion for malignancy (>10% to ≤ 50%)
			4c. high suspicion for malignancy (>50% to <95%)
5	Highly suggestive of malignancy	Tissue diagnosis	≥95%
6	Known biopsy-proven	Surgical excision when clinical appropriate	n/a

**PATHOLOGY AND IMAGING**  
**Benign Versus Malignancy Breast Lesions on USg**

	Benign	Malignant
Shape	Oval/ellipsoid	Variable
Alignment	Wider than tall; aligned parallel to tissue planes	Taller than wide
Margins	Smooth/thin Echogenic capsule with 2-3 gentle lobulations	Irregular or spiculated border; echogenic 'halo'
Echotexture	Variable to intense hyperechogenicity	Low-level, marked hypoechogenicity.
Homogeneity of internal echoes	Uniform	Non-uniform
Lateral shadowing	Present	Absent
Posterior effect	Minimum attenuation/posterior enhancement	Attenuation with obscured posterior margin
Other signs	---	Calcification, microlobulation, intraductal extension, infiltration across tissue planes.

Criteria used to assess breast lesions on contrast-enhanced MR images include the shape and demarcation of enhancing lesions, the pattern of enhancement and the time course of enhancement.

**MALIGNANCY CRITERIA OF BREAST LESIONS ON MRI**

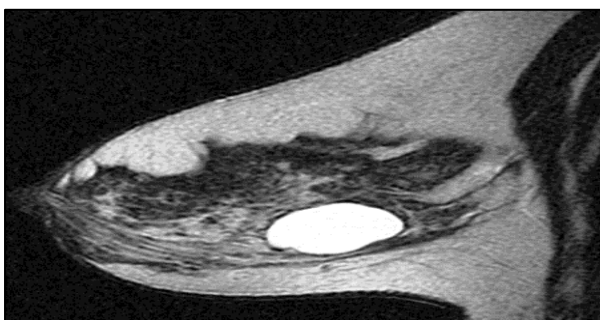
CRITERION	FEATURES SUGGESTING MALIGNANCY	NONSPECIFIC FEATURES
Lesion shape	Dendritic, star shaped	Round, oval
Lesion margin	Irregular margin, speculated	Smooth margin
Enhancement pattern	Ring enhancement	Inhomogeneous
Enhancement kinetics	Strong initial signal increase; post initial washout	Moderate initial signal increase; continuous post initial signal increase, plateau phase
Water content on T2-weighted images	Low water content	High water content, septa

**BREAST PATHOLOGY**

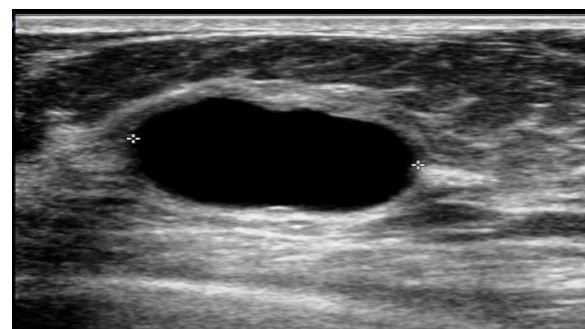**I. BENIGN LESIONS-**

**A. Cysts**

- Breast cysts are round or oval fluid-filled structures that are highly variable in size (from microscopic to 5–6 cm). A larger cyst can often be palpated as a firm, elastic mass.



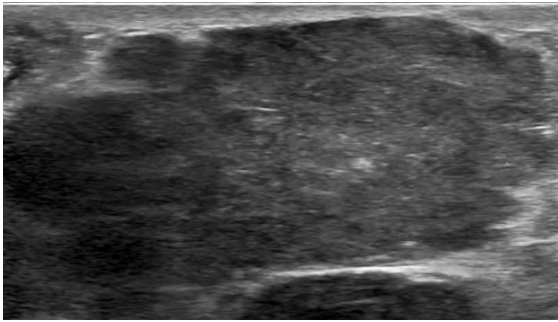
**Fig 1: Transverse ultrasonographic images of a 47-year-old woman with incidental cyst which appears anechoic with posterior acoustic enhancement.**



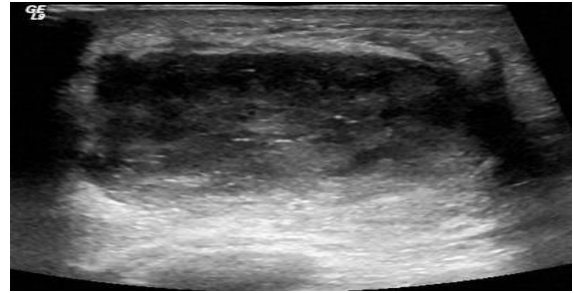
**Fig 2: MR images show cyst follows fluid signal and appears slightly hypointense to breast parenchyma on T1-weighted image and hyperintense on T2-weighted image.**

**B. Fibroadenoma**

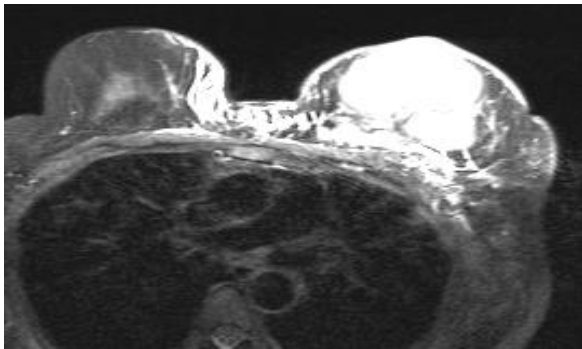
- Breast fibroadenoma is a mixed fibro epithelial tumor. The juvenile type of this benign tumor, occurring in younger women, has a large epithelial component. Women with adult fibroadenoma have an increased risk of breast cancer.



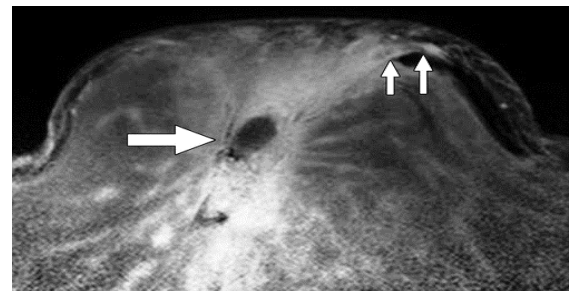
**Fig 3:** 22 year old female presented with a well-circumscribed, ovoid mass with uniform hypoechogenicity on USG.



**Fig 6:** In 27 year old breast-feeding patient, USG shows ill-defined complex cyst with solid and hypoechoic elements with low-level internal echoes, consistent with abscess.

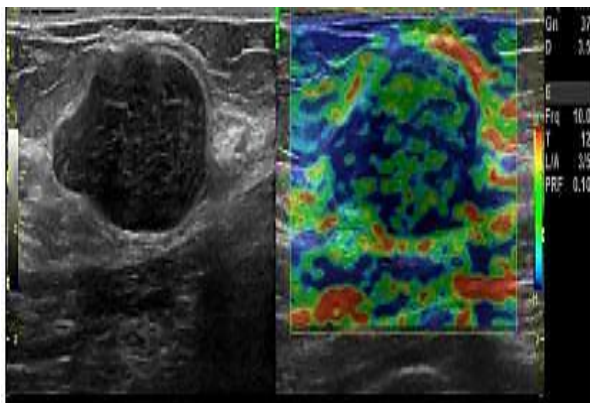


**Fig 4:** On MRI imaging, on T1: typically hypointense, T2: hyperintense, Post



**Fig 7:** 32-year-old woman with subareolar abscess. Contrast-enhanced T1-weighted image shows abscess cavity (*thick arrow*) and fistula that is hypointense linear structure with thin marginal enhancement (*thin arrows*)

**Contrast:** shows slow initial contrast enhancement followed by a persistent delayed phase (type I enhancement curve)



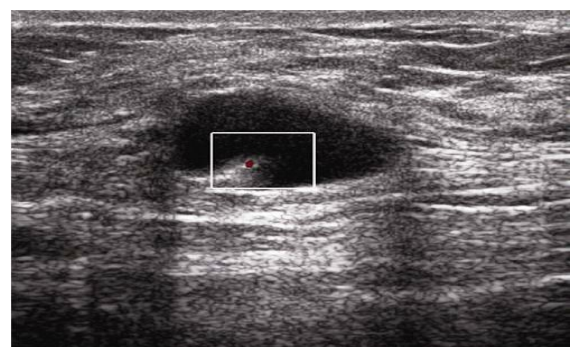
**Fig 5:** B-mode US image (A) and image (B) showing 2 hypo echoic circumscribed lesions that are predominantly elastic, assigned elasticity scores of 2 and 3 respectively. These were fibro adenomas with SR of 2.1 and 1.8

**C. Breast Abscess:**

- A **breast abscess** is a relatively rare but significant complication of mastitis that may occur during breastfeeding, particularly in primiparous women. The breast usually appears hot, red, and indurated.

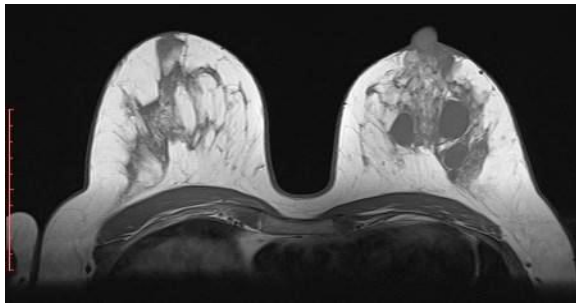
**D. Intraductal Papilloma:**

- Papilloma results from proliferation of the ductal epithelium. They project into the lumen of the duct and connected by a fibro-vascular stalk to the epithelial lining.
- The duct around them can dilate forming a cystic structure giving the appearance of an intra-cystic papilloma.



**Fig 8:** In 24 year old woman with palpable lump in right breast, USG shows small vascular based mural- nodule within fluid filled cyst.

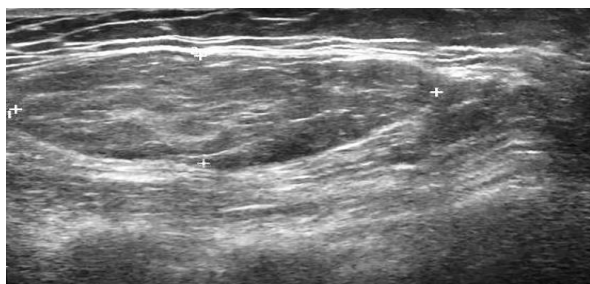




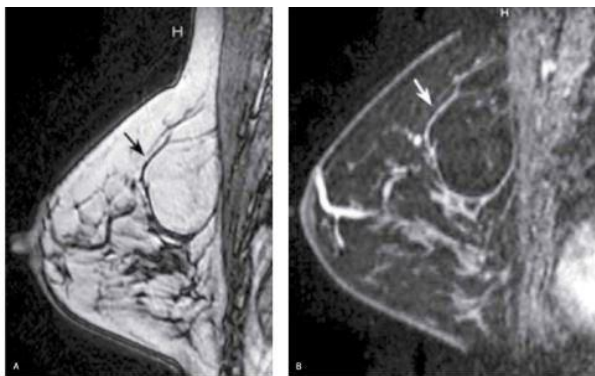
**Fig 9: In left nipple there is isointense nodule in both T1 and T2WI.**

#### E. Lipoma

- Most lipomas are superficial and form a palpable mass. These are freely movable and generally soft.



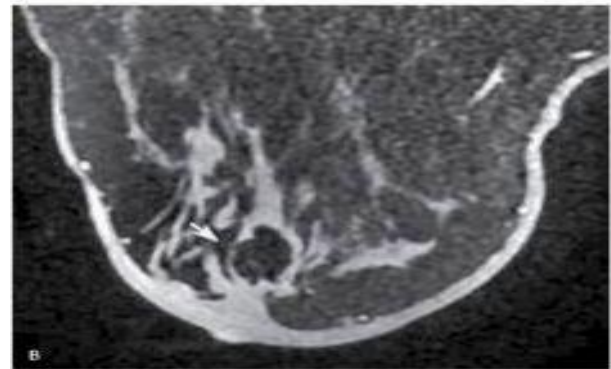
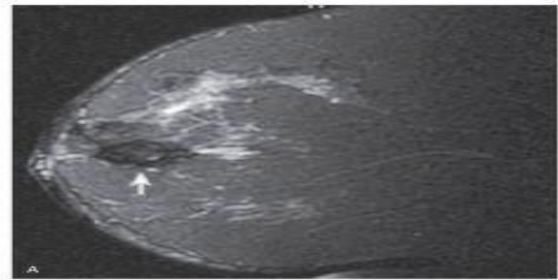
**Fig 10: USG of 26 year old woman shows a rounded lesion that is iso-echoic surrounding fat.**



**Fig 11: MRI shows that the lesion is isointense to fat on both T1 and T2.**

#### F. Fat Necrosis

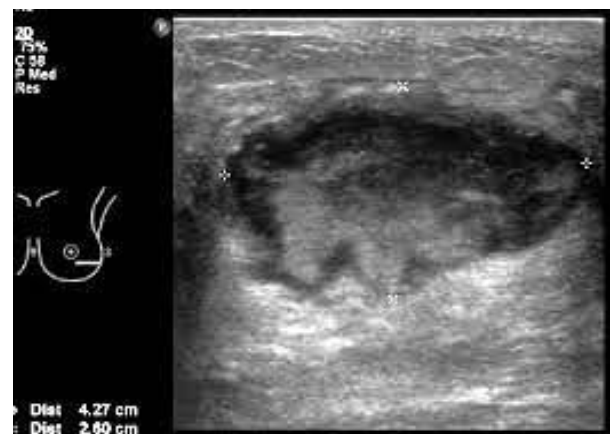
- Fat necrosis is an inflammatory process of breast related to prior trauma or surgery.



**Fig 12: MRI, sagittal and axial T2WI (fat-suppressed) show an oval mass with fatty tissue in subareolar region.**

#### G. Galactocele

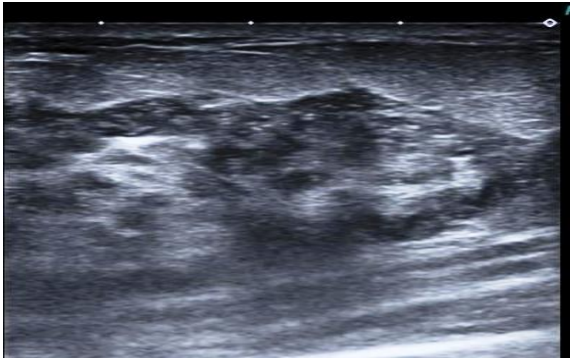
- Galactocele is a cyst filled with inspissated milk. It occurs during pregnancy or lactation and may persist long after cessation of lactation.



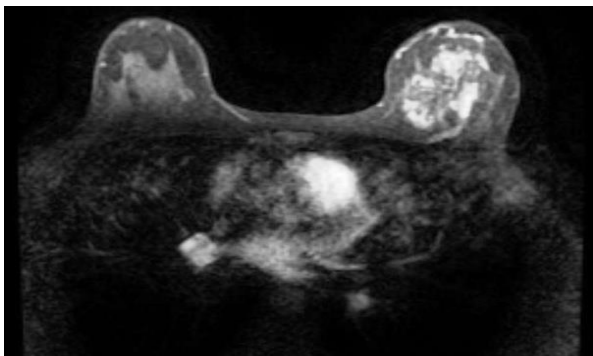
**Fig 13: Galactocele appear on a USG as small, round hypo echoic nodules with well-defined margins and thin, echogenic walls.**

#### H. Granulomatous mastitis

- It is an idiopathic chronic inflammatory condition. Patients usually present with vague lumps. Clinical evaluation may mimic cancer.



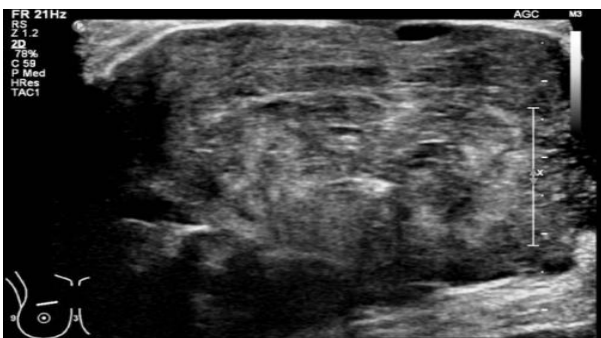
**Fig14:** USG image of a 44 year old female shows nodular hypoechoic lesion with focal decreased parenchymal echogenicity and acoustic shadowing



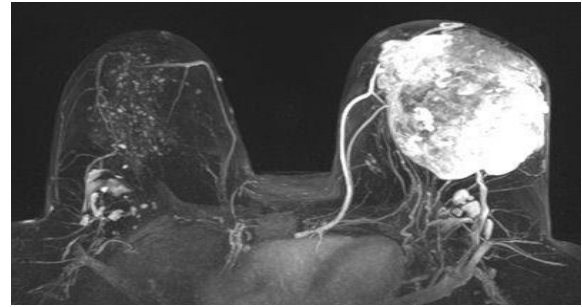
**Fig15:** On MRI, it shows diffuse asymmetrical signal intensity changes without significant mass effect. T1: hypointense; T2: hyperintense

### I. Phylloides Tumor

- Also known as **cystosarcoma phylloides** is a rare fibro-epithelial tumor of the breast which has some resemblance to a fibroadenoma. It is typically a large, fast growing mass that forms from the periductal stroma of the breast.



**Fig 16:** On ultrasound, an inhomogeneous, solid-appearing mass containing multiple, cleft like cystic spaces and demonstrating posterior acoustic enhancement.

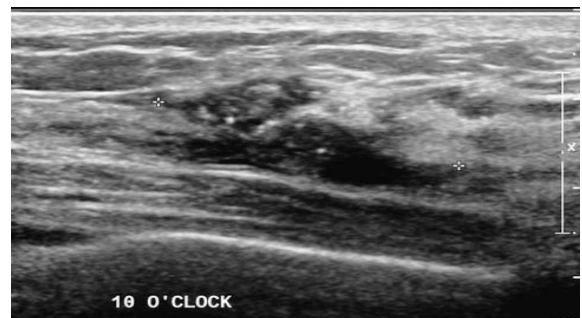

**Fig 17:** MRI shows a lobulated mass with circumscribed margins. T1: usually of low signal, T2: can be variable signal and T1 C+ (Gd): the solid components enhances.

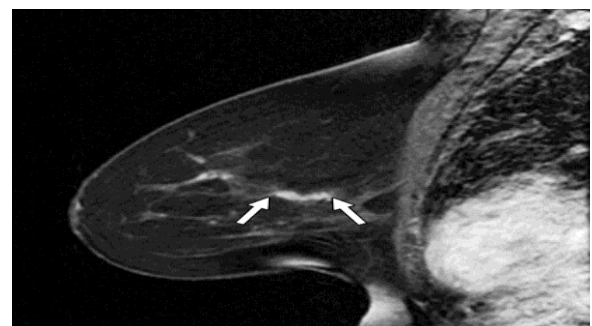## II. MALIGNANT LESIONS-

### A. Ductal Carcinoma In Situ

- Ductal carcinoma *in situ* lies along a spectrum of pre-invasive lesions of the breast tissue. Presentations of DCIS include mammographically detected mass or calcification, palpable mass, Paget's disease, or an incidental finding on breast biopsy.



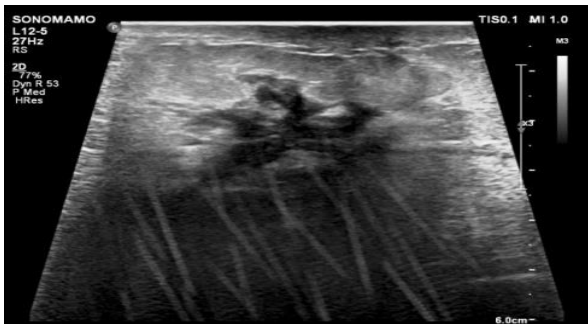
**Fig 18:** USG shows a micro-lobulated mild hypoechoic mass with ductal extension and normal acoustic transmission.



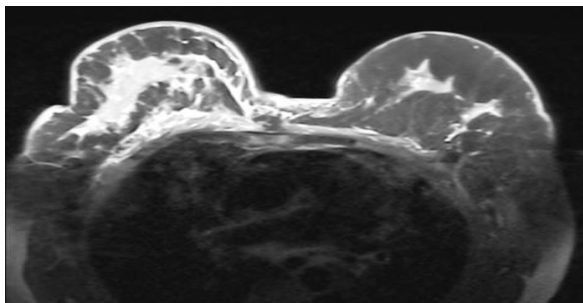
**Fig 19:** On MRI post-contrast, branching and linear enhancement with an irregular shape is seen.

### J. Invasive Ductal Carcinoma

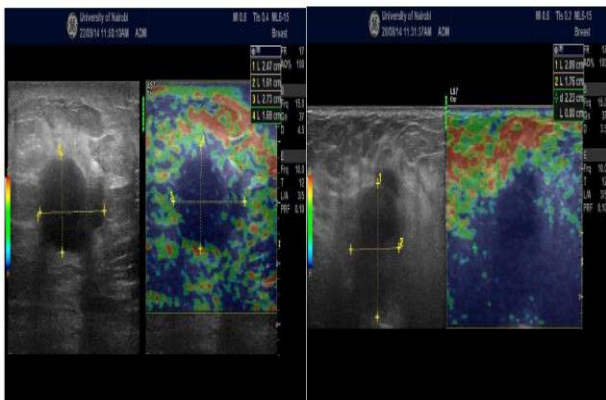
- Invasive ductal carcinoma (NOS) is undifferentiated and has no specific histologic pattern. Desmoplastic reaction is common in IDC which accounts for its most common presentation of hard mass on palpation and speculated mass on mammography.



**Fig 20:** USG of a 57 year old female presenting with breast lump showed a heterogeneously hypoechoic lesion with foci of internal calcification and internal vascularity.



**Fig 21:** On MRI, the lesion was hyperintense on T2WI, hypointense on T1WI and showed heterogeneous enhancement on post contrast.



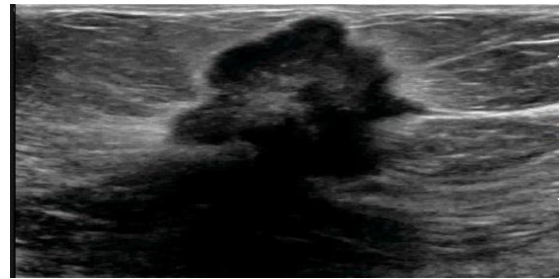
**Figure 2:** Malignant Masses on USE

B-mode US image (A) and SE image (B) showing 2 hypoechoic ill defined lesions that are predominantly blue assigned elasticity scores of 4 and 5 respectively. These were cases of invasive ductal carcinoma with SR of 5.8 and 9.8.

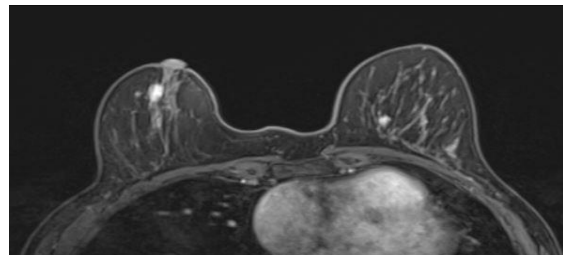
**Fig.21**

**K. Invasive Lobular Carcinoma**

- Invasive lobular carcinoma histologically, these show diffuse tumor foci invading the stroma. They spread in the form of a single file (line) of non-cohesive malignant cells through intervening normal parenchyma, instead of a well formed mass.



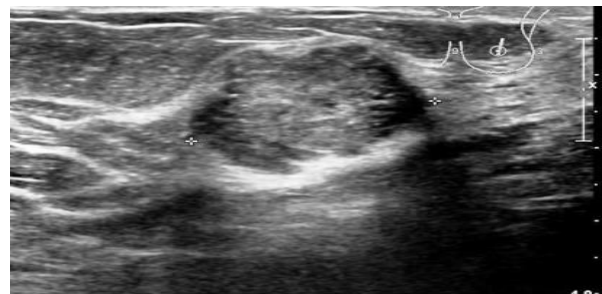
**Fig 23:** USG shows a heterogeneous, hypoechoic mass with angular or ill-defined margins and posterior acoustic shadowing.



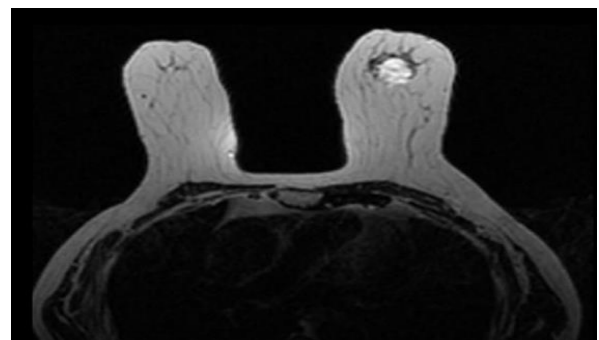
**Fig 24:** On MRI, the lesion was hyperintense on T2WI, hypointense on T1WI and showed heterogeneous enhancement on post contrast.

**J. Mucinous Carcinoma**

- Mucinous (or colloid) carcinoma is a well differentiated, slow growing tumor. It is generally seen in older women and has a better prognosis.



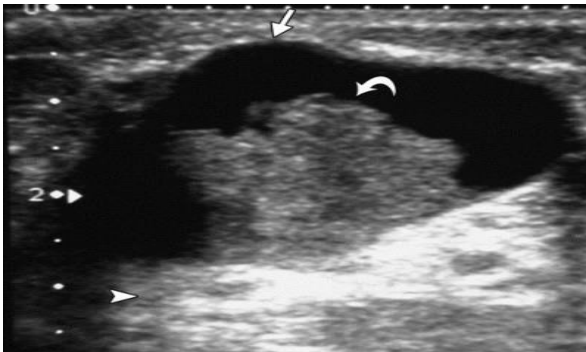
**Fig 25:** On ultrasound, they are hypoechoic, well-circumscribed lesion. Distal acoustic enhancement is seen.



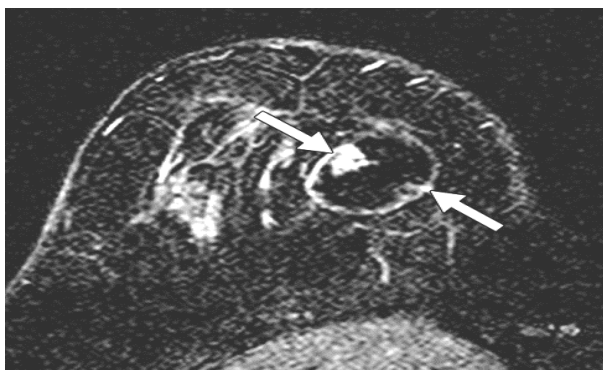
**Fig 26:** On MRI, the lesion was hyperintense on T2WI, hypointense on T1WI and showed Heterogenous enhancement on post contrast.

**M. Papillary Carcinoma**

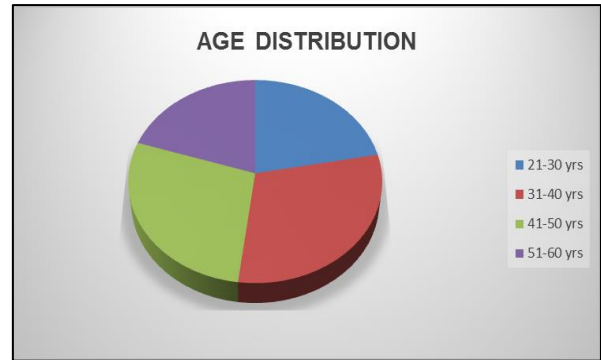
- Papillary carcinoma is seen with advanced age. There is villous epithelial proliferation that eventually fills the ductal lumen. Papillary carcinoma can develop as an intra-cystic lesion, although it is likely that the cyst represents a secondarily dilated duct.



**Fig 27: Solid papillary carcinoma in 48-year-old woman, who presented with palpable breast lump. Ultrasound image shows hypoechoic solid nodule (arrow).**



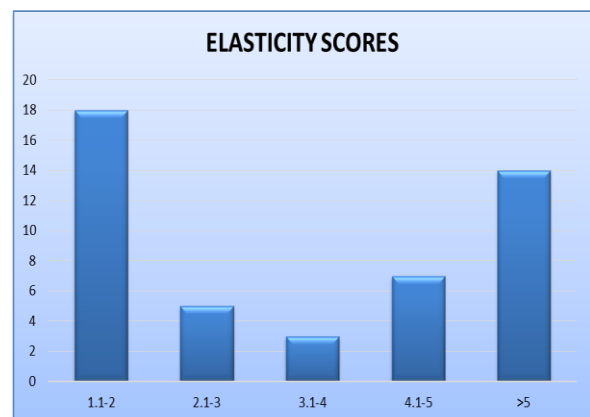
**Fig 28: Axial T1-weighted gadolinium-enhanced subtraction MR image shows heterogeneous enhancement of nodule with irregular margins (arrow).**



- The age ranged from 20 to 60 years. Maximum number of patients were in 31 -40 years age group 15(30%).
- The youngest patient of malignant lesion was 25 years old and oldest was 65 years of age.
- The mean age of patient with carcinoma breast was 45 years and in those suffering from benign lesions was 35 years.
- Out of these 50 patients, 10 (20%) were postmenopausal and 40(80%) were premenopausal. Family history of breast cancer was not present in any patient.

**TABLE 2: ELASTICITY SCORES OF BENIGN AND MALIGNANT BREAST MASSES**

Final diagnosis/elasticity score	1.1-2	2.1-3	3.1-4	4.1-5	>5
Benign lesion	18	5	-	-	-
Malignant lesion	-	-	3	7	14



- Fibroadenoma was the commonest benign lesion and demonstrated strain on compression.
- Malignant lesions showed no strain on compression and appeared larger on the elastography due to better visualization of the surrounding desmoplastic reaction.

**OBSERVATIONS**

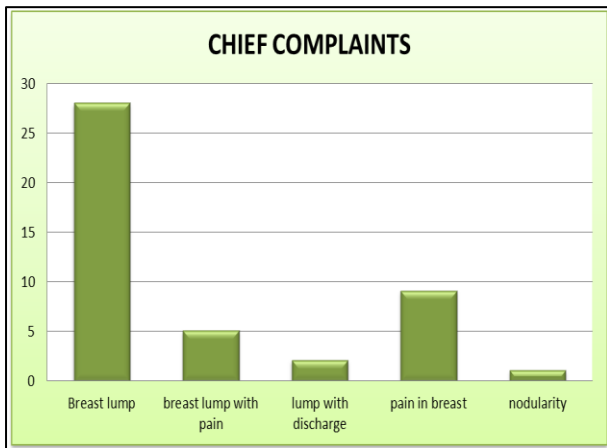
The present study comprised of 50 female patients with breast lesions, randomly selected from surgical indoor and outpatient department of our hospital.

**TABLE NO. 1: AGE DISTRIBUTION**

S.No.	Age Range (YRS)	No. of Patients	Percentage (%)
1	21-30	11	22
2	31-40	15	30
3	41-50	14	28
4	>50	10	20
	<b>TOTAL</b>	<b>50</b>	<b>100</b>

**TABLE NO. 3: CHIEF COMPLAINTS**

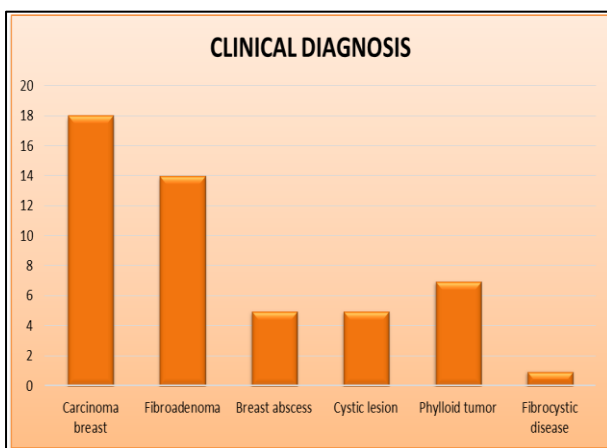
S.No.	Symptoms	No. of patients	%
1	Breast lump	28	56
2	Breast lump with pain	5	1
3	Lump with discharge	2	0.4
4	Pain in breasts	9	18
5	Nodularity	1	0.2
	TOTAL	50	100



- Maximum number of patients presented with breast lump followed by pain in breast.

**TABLE NO. 4: DISTRIBUTION OF CASES BASED ON FINAL DIAGNOSIS**

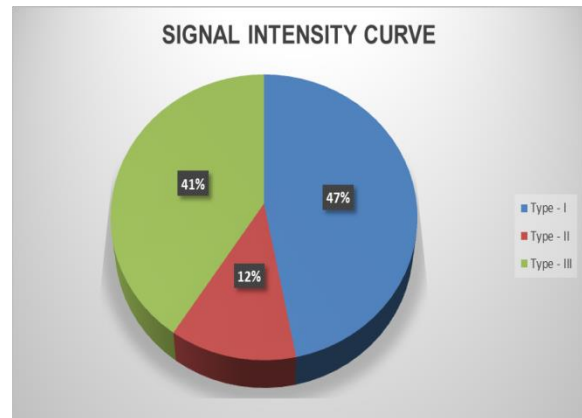
S. No.	Clinical diagnosis	No. of Patients	%
1	Carcinoma breast	18	35
2	Fibroadenoma	14	27
3	Breast abscess	5	10
4	Cystic lesion of breast	5	10
5	Phylloid tumor	7	14
6	Fibrocystic disease of the breast	1	2
	TOTAL	50	100



- Carcinoma breast was the most common disease (35%) followed by fibroadenoma (27%) and phylloid tumor (16%) respectively.

**TABLE NO. 5: SIGNAL INTENSITY CURVE PATTERN**

S. No.	Pattern	No. of patients	%
1	Type – I	23	47
2	Type – II	6	12
3	Type - III	20	41
	TOTAL	49	100

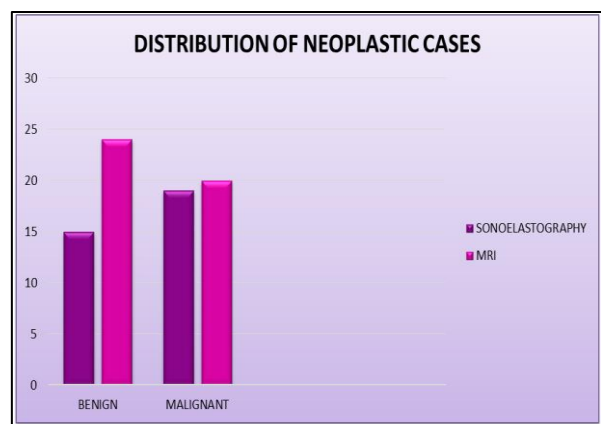


**TABLE NO. 6: PECTORALIS MUSCLE INVOLVEMENT**

S. No.	Pectoralis muscle involvement	No. of patients	%
1	<b>Present</b>	<b>9</b>	<b>18</b>
2	<b>Absent</b>	<b>41</b>	<b>82</b>
	<b>TOTAL</b>	<b>50</b>	<b>100</b>

**TABLE NO. 7: DISTRIBUTION OF NEOPLASTIC CASES**

	No. of patients (Sonoelastography)	No. of patients (MRI)
Benign lesion	<b>15</b>	<b>17</b>
Malignant lesion	<b>19</b>	<b>20</b>
TOTAL	<b>34</b>	<b>37</b>



- 34 of the patients were found to have neoplastic lesion in USG out of which 15(46%) had benign lesion and 19(53%) had malignant lesion.
- 37 of the patients were found to have neoplastic lesion in MRI out of which 17(45%) had benign lesion and 20(55%) had malignant lesion.

**TABLE 8: COMPARATIVE ANALYSIS OF BREAST LESIONS ON ELASTOGRAPHY, MRI WITH FINAL DIAGNOSIS (FNAC/HPE) IN 50 PATIENTS**

		Sonoelastography		MRI		Final (FNAC/HPE)	
S. No.	Diagnosis	Number	%	Number	%	Number	%
1	Malignant	19	53	20	55	22	56
2	Benign	15	46	17	45	17	44
	Total	34	100	37	100	39	100

**DISCUSSION**

Early detection of breast cancer is the primary goal of breast imaging. The diagnosis of breast lesions according to present clinical practice is based on the triple assessment i.e. clinical examination/self-examination, imaging and FNAC / biopsy.

However, sonography still remains the initial screening investigation of choice in women who present with breast lump. The most important role of US has been to determine whether a lesion is solid or cystic. Ultrasound elastography (USE) was introduced to increase the accuracy of characterizing breast lesions. Sonoelastography is a technique that applies compression to detect stiffness variation within the scanned tissues. Cancerous lesions are stiffer than non-cancerous ones. Ultrasound elastography uses this principle to differentiate malignant breast lesions from benign lesion on compression.

Breast MRI has gained immense clinical acceptance in early detection and assessing lesions which are indeterminate on physical examination or sonography. Breast MRI is also beneficial for women who are found to have a positive lymph node without any lesion detection by mammogram or ultrasonography.

In the present study the results of sonoelastography were compared with MRI. The malignant masses were the commonest and the mean age of patients with malignant masses in our study was 45 years, which is in consistent with Park’s statement that the mean age of breast cancer occurrence is about 42 years in India<sup>3</sup>. Painless lump in the breast was the common presenting feature in these patients and involvement of upper outer quadrant was the most common site.

**SONO-ELASTOGRAPHIC PATTERNS OF BREAST LESIONS:**

**Carcinoma Breast:**

Malignant lesions are commonly hypoechoic with ill-defined borders. Typically, a malignant lesion presents as a hypoechoic nodular lesion, which is ‘taller

than broader’ and has speculated margins, posterior acoustic shadowing and micro calcifications.

Out of 22(56%) patients confirmed to have malignant lesions histopathological examination, only 19(53%) patients were diagnosed on sonography. Out of 19 patients with malignant lesions 14(73.6%) had hypoechoic and 5(26.4%) patients showed mixed echogenicity lesions Hilton *et al.*, (1986) found that carcinomas present as hypoechoic masses and Skaane *et al.*, (1998) found that carcinomas were hypoechoic in 92% cases, they observed that hypoechoic is a prominent feature of malignancy was similar to our study.

**TABLE NO. 9**

WORKER	Hypoechoic carcinoma on sonoelastography examination
Hilton <i>et al.</i> , (1986)	92 %
Present study	100%

In our study calcification was seen in 12(63%) cases. Soo *et al.*, (2003) found calcification in 23% cases which differed from our study.

Axillary lymphadenopathy was seen 10(58%) cases in our study, which were hypoechoic and not having central echogenicity.

**Fibro Adenoma:**

Fibroadenoma usually presents as a firm, smooth, oval-shaped, freely movable mass. Fibroadenomas are multiple in 10–20% and bilateral in 4% of cases. On USG, it appears as a well-defined lesion. A capsule can usually be identified. The echotexture is usually homogenous and hypoechoic as compared to the breast parenchyma, and there may be low-level internal echoes.

**TABLE.10 In our study 14(27%) out of 50 patients were found to have fibroadenoma.**

WORKER	PERCENTAGE OF FIBROADENOMA
Singh, K. <i>et al.</i> , (2008)	38%
Present study	27%

**Phylloides Tumor:**

At USG, a phylloides tumor appears as a mildly hypoechoic mass, often pseudo-capsulated, without posterior acoustic shadowing. Inside the mass, pseudo-cystic spaces are sometimes so compressed that they look like characteristic hyperechoic striations. In the malignant variants, these pseudo-cystic spaces are coarser, and the echotexture may be rather heterogeneous.

In our study 7(14%) out of 50 patients were found to have phylloides tumor. They are lobulated heterogeneously hypoechoic lesion with internal cystic areas. Further HPE correlation showed that 3(42%) were benign and 4(58%) were malignant. In study conducted by T C Chao *et al.*, (2002), out of 110 phylloides tumors, 76 (69.1%) were benign, 11 (10.0%) were borderline and 23 (20.0%) were malignant.

**TABLE.11**

WORKER	PERCENTAGE OF PHYLLOIDES TUMOR	HPE CONFIRMATION BENIGN	HPE CONFIRMATION MALIGNANT
T C Chao <i>et al.</i> , (2002)	5.6%	76%	20%
Present study	14%	42%	58%

**Breast Abscess:**

Abscesses are most commonly located in the central or subareolar area. An abscess may show an ill-defined or a well-defined outline. It may be anechoic or may reveal low-level internal echoes and posterior enhancement.

In our study, 5(10%) out of 50 patients were found to have breast abscess. According to study by Tiu CM<sup>35</sup>, most lesions were hypoechoic which was similar to our study. The contour of the abscess was usually smooth (42, 31%). A hypoechoic rim was noticed in 18 lesions (13%). Diffuse skin thickening was exclusively evident in the breasts coexisting with mastitis. In our study we found that most lesions also showed low level internal echoes.

**TABLE.12**

WORKER	PERCENTAGE OF BREAST ABSECESS
Singh, K. <i>et al.</i> , (2008)	3%
Present study	10%

**Breast Cyst:**

A cyst is seen on USG as a well-defined, round or oval, anechoic structure with a thin wall. When internal echoes or debris are seen, the cyst is called a complex cyst. These internal echoes may be caused by floating cholesterol crystals, pus, blood or milk of calcium crystals.

Berg, W. A. (2005) studied 150 cystic lesions out of which 16(10%) was classified as simple cysts, 38(25.3%) as complicated cysts. In our study out of 5 cystic lesions, 3 were complex and 2 were benign in consistent with findings in above mentioned study.

Gheonea *et al.*, (2011) stated that out of 58 patients studied, 8(13%) of the patients were diagnosed to have cystic lesion in the breast. This finding was similar to our study where 5(10%) of the patients were diagnosed with cystic lesion of breast.

**TABLE.13**

WORKER	PERCENTAGE OF BREAST CYST
Gheonea <i>et al.</i> , (2011)	13%
Present study	10%

**MRI PATTERN IN BREAST LESIONS\_**

MRI was performed on “Siemens Magnetom Essenza 1.5 T” using a double CP breast array coil in all the 50 cases in whom the mammography and ultrasonography was done. On MRI malignant lesions were diagnosed in 20(55%) patients, out of time 19(92%), patients were confirmed on histopathological examination, in 1(8%) case the lesion was benign on histopathology.

The margins of masses were irregular in all 20(100%) patients. The shape of lesions was irregular (geographical) in 14(58%) patients, round in 3(5%) and oval in 3(17%) patients. These features were almost same as seen on mammography and ultrasonography. Orel *et al.*, (1994) and Nunes *et al.*, (1997) stated that the morphologic criteria on MRI are comparable to mammography, such as well-defined margins indicate benignity, while ill~ defined or speculated lesions are suggestive of malignancy. Mitsuhiro Tozaki *et al.*, (2005) stated that the most frequent types of lesion shape and margin among the malignant lesions were irregular (87%) and smooth (13%).

**TABLE.14**

WORKER	IRREGULAR MARGINS	SMOOTH MARGINS
Mitsuhiro Tozaki <i>et al.</i> , (2005)	87%	13%
Present study	85%	15%

On T1WI fat saturation sequence in 16(67%) patients masses were of low signal intensity (less than fibro glandular tissue), 2(7%) cases showed high signal intensity, in 1(8%) patient isointense signal and in 1(8%) patient it was hypointense with hyperintense rim. Orel *et al.*, (1994) found that all cancers were of low signal intensity (less than or equal to that of fibro glandular tissue) on T1-weighted images findings are similar to our finding.

On T2WI (TIRM) sequence 92(92%) patients had masses with immediate to hyperintense signal and in 1(8%) patient it was hypointense. Orel *et al.*, (1994) stated that the signal intensity of carcinoma on T2-weighted images was intermediate to high intensity in

86%, 7% showed low intensity and 7% had mixed intermediate the findings are almost similar in present study.

**TABLE.15**

WORKER	HIGH INTENSITY ON T2	LOW INTENSITY ON T2	INTERMEDIATE INTENSITY ON T2
Orel <i>et al.</i> , (1994)	86%	7%	7%
Present study	85%	5%	10%

The contrast enhancement characteristics was variable, 17(88%) patients showed heterogeneous enhancement and in 3(22%) it was homogeneously early enhancement, though most of our cases shows heterogeneous centripetal enhancement. Liu *et al.*, (1998) and Liberman *et al.*, (1997) stated that in malignant lesions enhancement is often inhomogeneous or rim-like and tends to proceed centripetally the similar findings were seen in present study.

**TABLE.16**

WORKER	HETEROGENOUS ENHANCEMENT	HOMOGENOUS ENHANCEMENT
Liberman L <i>et al.</i> , (1997)	68%	18%
Present study	88%	22%

Signal intensity curve type-II pattern was observed in 6(12%) patients, and type-III in rest of 20(41%) patients. Kuhl, C. K., & Schild, H. H. (2000) stated that the distribution of curve types for breast cancers was type I, 8.9%; type II, 33.6%; and type III, 57.4% author concluded that a type III time curve was a strong indicator of malignancy and was independent of other criteria. Macura *et al.*, (2006) stated that both type II and type III curves should be considered suggestive of malignancy. The similar pattern was seen our series.

**TABLE.17**

TYPE OF CURVE	Kuhl, C. K., & Schild, H. H. (2000)	PRESENT STUDY
TYPE I	9%	47%
TYPE II	33%	12%
TYPE III	57%	41%

Pectoralis muscle involvement was detected as abnormal enhancement area in the muscle in 9(18%) patients, out these 3 were showing features of invasive carcinoma. Morris *et al.*, (2000) stated that involvement of musculature deep to the tumor was reliably indicated

by abnormal enhancement in the muscle, the present study also had similar finding.

**TABLE.18**

WORKER	PECTORALIS MUSCLE INVOLVED	PECTORALIS MUSCLE NOT INVOLVED
Morris <i>et al.</i> , (2000)	26%	74%
Present study	18%	82%

**SENSITIVITY AND SPECIFICITY**

**TABLE.19**

	ELASTOSONOGRAPHY	MRI
Sensitivity	87.5%	95.6%
Specificity	84.4%	91.3%

Out of 19 cases diagnosed to be malignant on sonoelastography, only 16 were malignant on HPE. One case turned out to be fibroadenoma (case no 9) and two phyllodes tumor (case no 15 and 40).

Out of 20 cases diagnosed to be malignant on MRI, 19 were found to be malignant on HPE. It turned out to be benign variety of phyllodes tumor (case no 40).

Out of 15 cases diagnosed to be benign on sonoelastography, 13 were benign on HPE. Both cases turned out to be DCIS (case no 13 and 17).

Out of 17 cases diagnosed to be benign on MRI, all 17 were found to be benign on HPE.

**COMPARISON WITH OTHER STUDIES:**

**TABLE 20: COMPARATIVE STUDY FOR SONOELASTOGRAPHY (SENSITIVITY)**

Diagnosis	Ito A <i>et al.</i> , (2006)	Current Study
Benign	86%	88.2%
Malignant	88%	86.3%

**TABLE 21: COMPARATIVE STUDY FOR MR MAMMOGRAPHY (SPECIFICITY)**

Diagnosis	Balasubramanian P <i>et al.</i> , (2016)	Current Study
Benign	96.6%	97.9%
Malignant	95%	91.9%

- We found that the sensitivity and specificity of MRI is higher than USG for detection of breast mass lesions. Hence, MRI with contrast is a very valuable tool for the identification, characterization and differentiation of breast mass lesions.
- However, USG still remains the screening investigation of choice for breast mass lesions due to cost benefit and less time consumed.



## SUMMARY AND CONCLUSION

**Both elastosonography and MRI are useful for evaluating breast pathologies however in certain condition one of them gives better results than other.**

- Ultrasonography is noninvasive, low cost, rapid method for detection, localization and for differentiation of breast pathology.
- Usefulness of breast elastography has been confirmed particularly in small nodules, complex cysts or cysts with a corpuscular content. Elastography may reduce the need for biopsy in lesions classified as BIRADS 3 on US image and postpone follow-up.
- Elastography has a significant role in the management of nodules <5 mm which are visible on the US image, but not on mammography, in which reduced deformability may lead to biopsy rather than monitoring as required by the current guidelines.
- Strain imaging elastography is useful in the assessment of elastic tissue properties thanks to the short examination time required, real-time display, immediate interpretation and limited cost, and the criteria adopted in the image interpretation have proven to be adequate in clinical practice.
- Sensitivity and specificity of sono-elastography is 87.5% and 84.4 % respectively.
- The method has certain limitations, as it is an exclusively qualitative method which may be influenced by histotype and lesion size. It is an operator dependent technique which requires special training, and the use of semi-quantitative indices does not improve the performance of the method and does not reduce inter-operator variability.
- MRI due to its noninvasive, non-irradiating and multiplanar capability has significantly improved the diagnostic efficacy in early detection of breast lesions.
- Sensitivity and specificity of dynamic MRI is 95.6% and 91.3 % respectively
- The combined interpretation of morphological features and signal intensity curve pattern is of immense value in order to characterize a breast lesion as malignant or benign.
- MRI is indispensable to determine the exact extent, multicentricity, multimodality, intraductal spread of carcinoma and pectoralis muscle involvement. MRI is useful modality in palpable mass negative on

mammography/sonography. MRI is time consuming and costly approach.

- Screening in high risk young female with positive family history.
- Therefore we conclude that MRI evaluation of breast lesions give higher sensitivity and specificity than to mammography and ultrasonography.

## REFERENCE

1. Raina, V., Bhutani, M., Bedi, R., Sharma, A., Deo, S. V., Shukla, N. K., ... & Rath, G. K. (2005). Clinical features and prognostic factors of early breast cancer at a major cancer center in North India. *Indian journal of cancer*, 42(1), 40.
2. Sinha, R., Anderson, D.E., McDonald, S.S., & Greenwald, P. (2003). Cancer Risk and Diet in India, *Journal of postgraduate medicine*, 49 (3), 222-228.
3. Park, K. (2007). Epidemiology of chronic non-communicable diseases and conditions. *Park's textbook of preventive and social medicine*.
4. Boetes, C., Mus, R. D., Holland, R., Barentsz, J. O., Strijk, S. P., Wobbes, T., ... & Ruys, S. H. (1995). Breast tumors: comparative accuracy of MR imaging relative to mammography and US for demonstrating extent. *Radiology*, 197(3), 743-747.
5. Stavros, A. T., Thickman, D., Rapp, C. L., Dennis, M. A., Parker, S. H., & Sisney, G. A. (1995). Solid breast nodules: use of sonography to distinguish between benign and malignant lesions. *Radiology*, 196(1), 123-134.
6. Chao, T. C., Lo, Y. F., Chen, S. C., & Chen, M. F. (1999). Prospective sonographic study of 3093 breast tumors. *Journal of ultrasound in medicine*, 18(5), 363-370.
7. Rahbar, G., Sie, A. C., Hansen, G. C., Prince, J. S., Melany, M. L., Reynolds, H. E., ... & Bassett, L. W. (1999). Benign versus malignant solid breast masses: US differentiation. *Radiology*, 213(3), 889-894.
8. Lee, C. H., Smith, R., Levine, J. A., Troiano, R. N., & Tocino, I. (1999). Clinical usefulness of MR imaging of the breast in the evaluation of the problematic mammogram. *AJR. American journal of roentgenology*, 173(5), 1323-1329.
9. Orel, S. G., Schnall, M. D., Powell, C. M., Hochman, M. G., Solin, L. J., Fowble, B. L., ... & Rosato, E. F. (1995). Staging of suspected breast cancer: effect of MR imaging and MR-guided biopsy. *Radiology*, 196(1), 115-122.
10. Morris, E. A., Schwartz, L. H., Dershaw, D. D., Van Zee, K. J., Abramson, A. F., & Liberman, L. (1997). MR imaging of the breast in patients with occult primary breast carcinoma. *Radiology*, 205(2), 437-440.
11. Mumtaz, H., Hall-Craggs, M. A., Davidson, T., Walmsley, K., Thurell, W., Kissin, M. W., & Taylor, I. (1997). Staging of symptomatic primary breast cancer with MR imaging. *AJR. American journal of roentgenology*, 169(2), 417-424.
12. Fischer, U., Kopka, L., & Grabbe, E. (1999). Breast carcinoma: effect of preoperative contrast-enhanced

- MR imaging on the therapeutic approach. *Radiology*, 213(3), 881-888.
13. Weinstein, S. P., Orel, S. G., Heller, R., Reynolds, C., Czerniecki, B., Solin, L. J., & Schnall, M. (2001). MR imaging of the breast in patients with invasive lobular carcinoma. *American Journal of Roentgenology*, 176(2), 399-406.
  14. Müller, R. D., Barkhausen, J., Sauerwein, W., & Langer, R. (1998). Assessment of local recurrence after breast-conserving therapy with MRI. *Journal of computer assisted tomography*, 22(3), 408-412.
  15. Viehweg, P., Heinig, A., Lampe, D., Buchmann, J., & Heywang-Köbrunner, S. H. (1998). Retrospective analysis for evaluation of the value of contrast-enhanced MRI in patients treated with breast conservative therapy. *Magnetic Resonance Materials in Physics, Biology and Medicine*, 7(3), 141-152.
  16. Gordon, P. B., Goldenberg, S. L., & Chan, N. H. (1993). Solid breast lesions: diagnosis with US-guided fine-needle aspiration biopsy. *Radiology*, 189(2), 573-580.
  17. Kolb, T. M., Lichy, J., & Newhouse, J. H. (1998). Occult cancer in women with dense breasts: detection with screening US--diagnostic yield and tumor characteristics. *Radiology*, 207(1), 191-199.
  18. Venta, L. A., Dudiak, C. M., Salomon, C. G., & Flisak, M. E. (1994). Sonographic evaluation of the breast. *Radiographics*, 14(1), 29-50.
  19. Mendelson, E. B., & Tobin, C. E. (1995). Critical pathways in using breast US. *Radiographics*, 15(4), 935-945.
  20. Kim, S.-Y., Park, J. S., & Koo, H. R. (2015). Combined Use of Ultrasound Elastography and B-Mode Sonography for Differentiation of Benign and Malignant Circumscribed Breast Masses. *Journal of Ultrasound in Medicine*, 34(11), 1951-1959.
  21. Liu, P. F., Debatin, J. F., Caduff, R. F., Kacel, G., Garzoli, E., & Krestin, G. P. (1998). Improved diagnostic accuracy in dynamic contrast enhanced MRI of the breast by combined quantitative and qualitative analysis. *The British journal of radiology*, 71(845), 501-509.
  22. Sadowsky, N., & Kopans, D.B. (1983). Breast cancer. *RCNA*, 21(1), 51-65.
  23. Jackson, V. P. (1995). Management of solid breast nodules: what is the role of sonography?. *Radiology*, 196(1), 14-15.
  24. Jackson, V. P. (1995). The current role of ultrasonography in breast imaging. *Radiologic clinics of North America*, 33(6), 1161-1170.
  25. Navarro, B., Úbeda, B., Vallespi, M., Wolf, C., Casas, L., & Browne, J. L. (2011). Role of Elastography in the Assessment of Breast Lesions. *Journal of Ultrasound in Medicine*, 30(3), 313-321
  26. Kuhl, C. K., & Schild, H. H. (2000). Dynamic image interpretation of MRI of the breast. *Journal of Magnetic Resonance Imaging*, 12(6), 965-974.
  27. Cardenosa, G., Doudna, C., & Eklund, G. W. (1994). Mucinous (colloid) breast cancer: clinical and mammographic findings in 10 patients. *AJR. American journal of roentgenology*, 162(5), 1077-1079.
  28. Gheonea, I. A., Stoica, Z., & Bondari, S. (2011). Differential diagnosis of breast lesions using ultrasound elastography. *The Indian journal of radiology & imaging*, 21(4), 301.
  29. Berg, W. A. (2005). Sonographically depicted breast clustered microcysts: is follow-up appropriate?. *American Journal of Roentgenology*, 185(4), 952-959.
  30. Popli, M. (2002). Pictorial essay: Breast calcification. *Ind. J. Radiol Imag*, 12(1), 33-36.
  31. Swann, C. A., Kopans, D. B., Koerner, F. C., McCarthy, K. A., White, G., & Hall, D. A. (1987). The halo sign and malignant breast lesions. *American Journal of Roentgenology*, 149(6), 1145-1147.
  32. Chui-Mei, T., & Hong-Jen, C., Yi-Hong, C., & Chong-Chuan, H. (2018). Sonographic Features of Breast Ab scesses with Em pha sis on "Hypoechoic Rim" Sign.
  33. Bassett, L. W., Kimme-Smith, C., Sutherland, L. K., Gold, R. H., Sarti, D., & King 3rd, W. (1987). Automated and hand-held breast US: effect on patient management. *Radiology*, 165(1), 103-108.
  34. Skaane, P., & Engedal, K. (1998). Analysis of sonographic features in the differentiation of fibroadenoma and invasive ductal carcinoma. *AJR. American journal of roentgenology*, 170(1), 109-114.
  35. Maturo, V. G., Zusmer, N. R., Gilson, A. J., & Bear, B. (1982). Ultrasonic appearance of mammary carcinoma with a dedicated whole-breast scanner. *Radiology*, 142(3), 713-718.
  36. Cole-Beuglet, C., Soriano, R. Z., Kurtz, A. B., & Goldberg, B. B. (1983). Ultrasound analysis of 104 primary breast carcinomas classified according to histopathologic type. *Radiology*, 147(1), 191-196.
  37. Egan, R.L., & Egan, K.L. (1984). Automated water path full. Breast sonography; correlation with histology of 176 solid lesions. *AJR*; 143, 499-507.
  38. Singh, K., Azad, T., & Gupta, G. D. (2008). The accuracy of ultrasound in diagnosis of palpable breast lumps. *Breast*, 6(6), 100.
  39. Basset, L.W., & Kimme-Smith, C. (1991). Breast sonography. *AJR*, 156, 449-455.
  40. Chao, T. C., Lo, Y. F., Chen, S. C., & Chen, M. F. (2002). Sonographic features of phyllodes tumors of the breast. *Ultrasound in Obstetrics and Gynecology*, 20(1), 64-71.
  41. Soo, M. S., Baker, J. A., & Rosen, E. L. (2003). Sonographic detection and sonographically guided biopsy of breast microcalcifications. *American Journal of Roentgenology*, 180(4), 941-948.
  42. Hilton, S. V., Leopold, G. R., Olson, L. K., & Willson, S. A. (1986). Real-time breast sonography: application in 300 consecutive patients. *American journal of roentgenology*, 147(3), 479-486.
  43. Jokich, P. M., Monticciolo, D. L., & Adler, Y. T. (1992). Breast ultrasonography. *Radiologic Clinics of North America*, 30(5), 993-1009.
  44. Berg, W. A., Campassi, C. I., & Ioffe, O. B. (2003). Cystic lesions of the breast: sonographic-pathologic correlation. *Radiology*, 227(1), 183-191.
  45. Popli, M. B. (2002). Pictorial essay: Sonographic differentiation of solid breast lesions. *Indian Journal of Radiology and Imaging*, 12(2), 275.

46. Kopans, D. B., Meyer, J. E., & Lindfors, K. K. (1985). Whole-breast US imaging: four-year follow-up. *Radiology*, 157(2), 505-507.
47. Sickles, E. A., Filly, R. A., & Callen, P. W. (1983). Breast cancer detection with sonography and mammography: comparison using state-of-the-art equipment. *American Journal of Roentgenology*, 140(5), 843-845.
48. Balasubramanian, P., Murugesan, V. K., & Boopathy, V. (2016). The Role of MR mammography in differentiating benign from malignant in suspicious breast masses. *Journal of clinical and diagnostic research: JCDR*, 10(9), TC05.
49. Itoh, A., Ueno, E., Tohno, E., Kamma, H., Takahashi, H., Shiina, T., ... & Matsumura, T. (2006). Breast disease: clinical application of US elastography for diagnosis. *Radiology*, 239(2), 341-350.
50. Madhusudhan Ks, G. (2008). Primary breast tuberculosis masquerading as carcinoma. *Singapore Med J*, 49(1).
51. Esserman, L., Hylton, N., Yassa, L., Barclay, J., Frankel, S., & Sickles, E. (1999). Utility of magnetic resonance imaging in the management of breast cancer: evidence for improved preoperative staging. *Journal of clinical oncology*, 17(1), 110-110.
52. Berg, W. A., Gutierrez, L., NessAiver, M. S., Carter, W. B., Bhargavan, M., Lewis, R. S., & Ioffe, O. B. (2004). Diagnostic accuracy of mammography, clinical examination, US, and MR imaging in preoperative assessment of breast cancer. *Radiology*, 233(3), 830-849.
53. Orel, S. G., Schnall, M. D., LiVolsi, V. A., & Troupin, R. H. (1994). Suspicious breast lesions: MR imaging with radiologic-pathologic correlation. *Radiology*, 190(2), 485-493.
54. Nunes, L. W., Schnall, M. D., Siegelman, E. S., Langlotz, C. P., Orel, S. G., Sullivan, D., ... & Torosian, M. H. (1997). Diagnostic performance characteristics of architectural features revealed by high spatial-resolution MR imaging of the breast. *AJR. American journal of roentgenology*, 169(2), 409-415.
55. Nunes, L. W., Schnall, M. D., Orel, S. G., Hochman, M. G., Langlotz, C. P., Reynolds, C. A., & Torosian, M. H. (1997). Breast MR imaging: interpretation model. *Radiology*, 202(3), 833-841.
56. Rieber, A., Tomczak, R. J., Mergo, P. J., Wenzel, V., Zeitler, H., & Brambs, H. J. (1997). MRI of the breast in the differential diagnosis of mastitis versus inflammatory carcinoma and follow-up. *Journal of computer assisted tomography*, 21(1), 128-132.
57. Liu, P. F., Debatin, J. F., Caduff, R. F., Kacel, G., Garzoli, E., & Krestin, G. P. (1998). Improved diagnostic accuracy in dynamic contrast enhanced MRI of the breast by combined quantitative and qualitative analysis. *The British journal of radiology*, 71(845), 501-509.
58. Kuhl, C. K., Mielcareck, P., Klaschik, S., Leutner, C., Wardelmann, E., Gieseke, J., & Schild, H. H. (1999). Dynamic breast MR imaging: are signal intensity time course data useful for differential diagnosis of enhancing lesions?. *Radiology*, 211(1), 101-110.
59. Rovno, H. D., Siegelman, E. S., Reynolds, C., Orel, S. G., & Schnall, M. D. (1999). Solitary intraductal papilloma: findings at MR imaging and MR galactography. *AJR. American journal of roentgenology*, 172(1), 151-155.
60. Morris, E. A., Schwartz, L. H., Drotman, M. B., Kim, S. J., Tan, L. K., Liberman, L., ... & Dershaw, D. D. (2000). Evaluation of pectoralis major muscle in patients with posterior breast tumors on breast MR images: early experience. *Radiology*, 214(1), 67-72.
61. Matsubayashi, R., Matsuo, Y., Edakuni, G., Satoh, T., Tokunaga, O., & Kudo, S. (2000). Breast masses with peripheral rim enhancement on dynamic contrast-enhanced MR images: correlation of MR findings with histologic features and expression of growth factors. *Radiology*, 217(3), 841-848.
62. Kinkel, K., Helbich, T. H., Esserman, L. J., Barclay, J., Schwerin, E. H., Sickles, E. A., & Hylton, N. M. (2000). Dynamic high-spatial-resolution MR imaging of suspicious breast lesions: diagnostic criteria and interobserver variability. *American journal of Roentgenology*, 175(1), 35-43.
63. Liberman, L., Morris, E. A., Kim, C. M., Kaplan, J. B., Abramson, A. F., Menell, J. H., ... & Dershaw, D. D. (2003). MR imaging findings in the contralateral breast of women with recently diagnosed breast cancer. *American Journal of Roentgenology*, 180(2), 333-341.
64. Lee, S. G., Orel, S. G., Woo, I. J., Cruz-Jove, E., Putt, M. E., Solin, L. J., ... & Schnall, M. D. (2003). MR imaging screening of the contralateral breast in patients with newly diagnosed breast cancer: preliminary results. *Radiology*, 226(3), 773-778.
65. Lehman, C. D., Gatsonis, C., Kuhl, C. K., Hendrick, R. E., Pisano, E. D., Hanna, L., ... & DePeri, E. R. (2007). MRI evaluation of the contralateral breast in women with recently diagnosed breast cancer. *New England Journal of Medicine*, 356(13), 1295-1303.
66. Liberman, L., Morris, E. A., Dershaw, D. D., Abramson, A. F., & Tan, L. K. (2003). Ductal enhancement on MR imaging of the breast. *American Journal of Roentgenology*, 181(2), 519-525.
67. Kriege, M., Brekelmans, C. T., Boetes, C., Besnard, P. E., Zonderland, H. M., Obdeijn, I. M., ... & Muller, S. H. (2004). Efficacy of MRI and mammography for breast-cancer screening in women with a familial or genetic predisposition. *New England Journal of Medicine*, 351(5), 427-437.
68. Hata, T., Takahashi, H., Watanabe, K., Takahashi, M., Taguchi, K., Itoh, T., & Todo, S. (2004). Magnetic resonance imaging for preoperative evaluation of breast cancer: a comparative study with mammography and ultrasonography. *Journal of the American College of Surgeons*, 198(2), 190-197.
69. Kuhl, C. K., Schrading, S., Leutner, C. C., Morakkabati-Spitz, N., Wardelmann, E., Fimmers, R., ... & Schild, H. H. (2005). Mammography, breast ultrasound, and magnetic resonance imaging for surveillance of women at high familial risk for breast cancer. *Journal of clinical oncology*, 23(33), 8469-8476.
70. Shah, S. K., Shah, S. K., & Greatrex, K. V. (2005). Current role of magnetic resonance imaging in breast

- imaging: a primer for the primary care physician. *J Am Board Fam Pract*, 18(6), 478-490.
71. Tozaki, M., Igarashi, T., Matsushima, S., & Fukuda, K. (2005). High-spatial-resolution MR imaging of focal breast masses: interpretation model based on kinetic and morphological parameters. *Radiation medicine*, 23(1), 43-50.
  72. Chakraborti, K. L., Bahl, P., Sahoo, M., Ganguly, S. K., & Oberoi, C. (2005). Magnetic resonance imaging of breast masses: Comparison with mammography. *Indian Journal of Radiology and Imaging*, 15(3), 381.
  73. Wurdinger, S., Herzog, A. B., Fischer, D. R., Marx, C., Raabe, G., Schneider, A., & Kaiser, W. A. (2005). Differentiation of phyllodes breast tumors from fibroadenomas on MRI. *American Journal of Roentgenology*, 185(5), 1317-1321.
  74. Kocaoglu, M., Somuncu, I., Ors, F., Bulakbasi, N., Tayfun, C., & Ilkbahar, S. (2004). Imaging findings in idiopathic granulomatous mastitis: a review with emphasis on magnetic resonance imaging. *Journal of computer assisted tomography*, 28(5), 635-641.
  75. Tuncbilek, N., Karakas, H. M., & Okten, O. O. (2005). Dynamic magnetic resonance imaging in determining histopathological prognostic factors of invasive breast cancers. *European journal of radiology*, 53(2), 199-205.
  76. Yabuuchi, H., Soeda, H., Matsuo, Y., Okafuji, T., Eguchi, T., Sakai, S., ... & Hatakenaka, M. (2006). Phyllodes tumor of the breast: correlation between MR findings and histologic grade. *Radiology*, 241(3), 702-709.
  77. Macura, K. J., Ouwerkerk, R., Jacobs, M. A., & Bluemke, D. A. (2006). Patterns of enhancement on breast MR images: interpretation and imaging pitfalls. *Radiographics*, 26(6), 1719-1734.
  78. Liberman, L., Mason, G., Morris, E. A., & Dershaw, D. D. (2006). Does size matter? Positive predictive value of MRI-detected breast lesions as a function of lesion size. *American Journal of Roentgenology*, 186(2), 426-430.
  79. Fu, P., Kurihara, Y., Kanemaki, Y., Okamoto, K., Nakajima, Y., Fukuda, M., & Maeda, I. (2007). High-resolution MRI in detecting subareolar breast abscess. *American Journal of Roentgenology*, 188(6), 1568-1572.
  80. Morris, E. A. (2007). Diagnostic breast MR imaging: current status and future directions. *Radiologic clinics of North America*, 45(5), 863-880.
  81. Kuhl, C. (2007). The current status of breast MR imaging part I. Choice of technique, image interpretation, diagnostic accuracy, and transfer to clinical practice. *Radiology*, 244(2), 356-378.
  82. Bilimoria, K. Y., Cambic, A., Hansen, N. M., & Bethke, K. P. (2007). Evaluating the impact of preoperative breast magnetic resonance imaging on the surgical management of newly diagnosed breast cancers. *Archives of Surgery*, 142(5), 441-447.
  83. Vassiou, K., Kanavou, T., Vlychou, M., Poultsidi, A., Athanasiou, E., Arvanitis, D. L., & Fezoulidis, I. V. (2009). Characterization of breast lesions with CE-MR multimodal morphological and kinetic analysis: comparison with conventional mammography and high-resolution ultrasound. *European journal of radiology*, 70(1), 69-76.
  84. Seltzer, V. (1994). The breast: embryology, development, and anatomy. *Clinical obstetrics and gynecology*, 37(4), 879-880.
  85. Michael, P. O. (1991). Breast development and anatomy. In: Harris, J., Hellman, S., Henderson, I., Kinne, D., eds, *Breast diseases*. 2nd ed. Philadelphia, Pa: Lippincott, 1-13.
  86. Kopans, D. (2007). Breast anatomy and basic histology, physiology, and pathology. In Kopans D, ed. *Breast imaging*. 3rd. Philadelphia, Pa: Lippincott Williams & Wilkins, 7-43.
  87. Love, S. M., & Barsky, S.H. (2004). Anatomy of the nipple and breast ducts revisited. *Cross RefMedline Cancer*, 101, 1947-1957.
  88. American College of Radiology (ACR). (2003). *Breast Imaging Reporting and Data System Atlas (BI-RADS Atlas)*. Reston, Va: © American College of Radiology.