

## Original Research Article

## Computed Tomography, MRI and Ultrasound Correlation in Pancreatic Pathologies (A Study of 90 Cases)

Dr Hiral Parekh.<sup>1</sup>, Dr Dharmesh Vasavada.<sup>2</sup>, Dr Gaurav Parmar.<sup>3</sup><sup>1</sup>Professor, Department of Radiodiagnosis M P Shah Government Medical College Jamnagar, Gujarat, India<sup>2</sup>Professor, Department of Surgery M P Shah Government Medical College Jamnagar, Gujarat, India<sup>3</sup>Resident Doctor in Radiodiagnosis Department of Radiodiagnosis M P Shah Government Medical College Jamnagar, Gujarat, India\*Corresponding Author  
Dr Hiral Parekh

**Abstract: Introduction:-** with evaluation in imaging technique detection of pancreatic disorder become very easy now a days. Every imaging technique has its own role on detection of pancreatic pathology. With the modern multislice scanners, the techniques for scanning are remarkably simplified. **Methods:** Total 90 Patients of various age groups presenting to medicine or surgery OPD at our institute with complaints of acute abdominal pain or chronic abdominal pain for long time associated with nausea/vomiting, pain radiates to back, typical after meal pain were included. Patients with history of gall stones and chronic alcoholism were given attention. **Discussion:** As USG has got many advantages like easy availability, cost effectiveness, non-invasive, no radiation hazards and can be repeated as when required, it was done in every case before a CT and/or MRI. On CT and/or MRI examination of patients with acute pancreatitis, most common finding was peripancreatic fat stranding 21 case(100%). increase in size 15 cases (71.42%) followed by ascites 12 case(57.14%), pleural effusion in 8 cases (38.09 %), heterogeneous enhancement in 11 cases (52.38%) , necrosis in 7 cases(26.92%). **Conclusion:** USG can be done as baseline study, for follow up assessment and quick assessment for status of patient. We conclude that MDCT scan is most important single modality to evaluate the patients with pancreatic diseases and MRI can be used as supplement to CT to add on more information. USG is important as first line of investigation and for follow up, as it is cheap and can be done whenever needed.

**Keywords:** Acute Pancreatitis, Pancreatic Tumour, Obstructive Jaundice.

### INTRODUCTION

The pancreas is an important organ of the body but still a difficult organ to evaluate by both clinical and routine radiological methods. Pancreatic disorders have propensity for producing high morbidity and mortality in both neoplastic and inflammatory disorders. They are also insidious in their presentation on most occasion.

Detection of pancreatic abnormality by routine noninvasive radiological methods namely plain radiography and gastrointestinal barium studies is possible but these tests are insensitive and nonspecific. In earlier era more invasive tests like retroperitoneal air insufflations with tomography used never achieved wide spread clinical application and isotope scan proved disappointing owing to their false positive rates.

Evaluating pancreas by USG is advantageous as it is economical, easily available and noninvasive with no radiation hazards, provide real time imaging and can be repeated as and when required. However the major limiting factor for ultrasound evaluation in patient with acute pancreatitis is failure to visualize pancreas due to distended bowel loops because of paralytic ileus, epigastric tenderness. With introduction of CT at present Dynamic incremental bolus CT scan is the gold standard in the imaging of pancreatic pathologies.

CT is the preferred technique in the diagnosis of pathology, assessment of severity, staging and detection of the complication. It serves as a useful prognostic indicator of morbidity and mortality and can identify high risk patients. CT can detect complication early and image guided aspiration and drainage

Quick Response Code



Journal homepage:

<http://www.easpublisher.com/easjrit/>

Article History

Received: 01.03.2019

Accepted: 15.03.2019

Published: 28.03.2019

**Copyright © 2019 The Author(s):** This is an open-access article distributed under the terms of the Creative Commons Attribution 4.0 International License (CC BY-NC 4.0) which permits unrestricted use, distribution, and reproduction in any medium for non-commercial use provided the original author and source are credited.

DOI: 10.36349/easjrit.2019.v01i02.002

procedure can then be carried out. CT also provides anatomic details to optimize surgical interventions.

Newer imaging techniques like helical CT scanning by obtaining volumetric data reduces the misregistration artifacts and respiratory artifacts, relationship with adjacent contrast enhanced vessels can be better appreciated.

CT Provide rapid acquisition, near isotropic resolution, thinner slice collimation and multiphasing imaging. Using MDCT scanner, it is now possible to carry out split arterial and venous phase and images can be post processed and reconstructed to obtain useful information.

Among the different post processing technique, Maximum intensity projection (MIP) is particularly useful to display vascular structure; volume rendered images is apt to depict both vessels and soft tissue. Multiplanar volume rendering and curved reconstruction (MPR & CMR), which can be constructed along the course of pancreatic duct, provide MDCT pancreatograms, allow to follow the course of the dilated pancreatic duct, find the site of obstruction, analyze the characteristic of stenosis and visualize the surrounding parenchyma.

With the modern multislice scanners, the techniques for scanning are remarkably simplified because of the exquisite Imaging detail With the very small isotropic pixels and the ability to evaluate the anatomy in three dimensions, visualizing very thin fat planes, small vessels, overlapping intestinal loops or unusual congenital variations is very easy. Isotropic three dimensional reformatted images are useful for accurate staging of tumor and pre-operative vascular mapping.

As MDCT technology facilitates early detection of small pancreatic lesions, it is likely to impact the treatment of pancreatic tumors. Angiographic reconstruction helps to detect complication like splenic artery aneurysm or venous thrombosis, in acute pancreatitis.

Currently, magnetic resonance imaging (MRI) plays a secondary role in the diagnosis and imaging workup of patient. With pancreatic diseases, when compared with multidetector-row computed tomography (MDCT).

However, technical innovations in MRI, such as the development of phased-array multi-coils, enhanced gradients, and methods to reduce motion-related artefacts, allow us to obtain images of the pancreas with excellent contrast resolution in a reasonable examination time.

Furthermore, the evaluation of the pancreas can be optimized by the use of MR Pancreatography

(MRP), which depicts the pancreatic ductal system, and with MR angiography (MRA), which visualizes the peripancreatic vessels. At present, this "all-in-one" approach, combining pancreatic parenchymal MRI, MRP, and MRA, is presumably the most cost-effective imaging technique in the evaluation of pancreatic diseases.

This study aims to establish the role of USG, MRI AND MDCT in evaluation of pancreatic pathologies.

#### **AIMS & OBJECTIVES:**

- To detect pancreatic abnormalities.
- To categorize pancreatic pathologies in inflammatory or neoplastic condition and evaluate extent of disease process.
- To ascertain various radiological features in diagnostic pancreatic diseases.
- To determine the accuracy of the USG, MRI and MDCT in diagnosis of pancreatic lesions.

#### **INTRODUCTION:**

- Imaging studies are major component in evaluation of Pancreatic diseases.
- Ultrasonography of pancreas is initial investigation in evaluating abnormalities.
- In modern era, by using cross sectional imaging like CT and MRI, we get better visualization of anatomical landmarks and its alterations aiding in diagnosis of different pancreatic pathologies.
- In my study, I am comparing Ultrasonography, CT and MRI for evaluation of pancreatic disease with advantages and disadvantages of each of them.

#### **MATERIALS AND METHODS:**

- This was a cross-sectional study being done in Department of Radio-diagnosis, at our institute which was carried out after clearance and approval of institutional ethics committee.
- A written and informed consent was obtained from all the subjects.
- Subjects will be examined by ultrasonography, CT and MRI imaging modalities.
- Results will be checked by two radiologist (PI and CO-PI) and final comparative data will be given between ultrasonography, CT and MRI imaging with counting of various risk factors.

#### **STUDY POPULATION:**

- Patients of various age groups presenting to medicine or surgery OPD with complaints of acute abdominal pain or chronic abdominal pain for long time associated with nausea/vomiting, pain radiates to back, typical after meal pain were included. Patients with history of gall stones and chronic alcoholism were given attention.

**SAMPLE SIZE:**

- A total of 90 patients having complaints of abdominal pain which may be associated with worsening after meal or pain radiating to back associated with fever and nausea/vomiting.

**INCLUSION CRITERIA:**

- Acute or Long lasting abdominal pain.
- Chronic patient of Gall stones.
- Cases of all age groups irrespective of sex.
- Personal or family history of MEN syndrome.

**EXCLUSION CRITERIA:**

- Cardiac pacemaker.
- Claustrophobia.
- Non co-operative patient.
- Hemo-dynamically unstable patient.

**PROTOCOL:**

- After enrolment of the case in the study a detailed history was taken and clinical examination was done along with recording of demographic information. Investigations like ultrasonography, Computed Tomography (CT) and Magnetic Resonance Imaging (MRI) were done to confirm the diagnosis. Final diagnosis was made after correlation with results of all tests.

**1. Ultrasonography**

- Equipment – Philips and E-Saote my lab 20 and 40.
- Position - supine.
- Thoroughly abdominal scan is done for all patients.

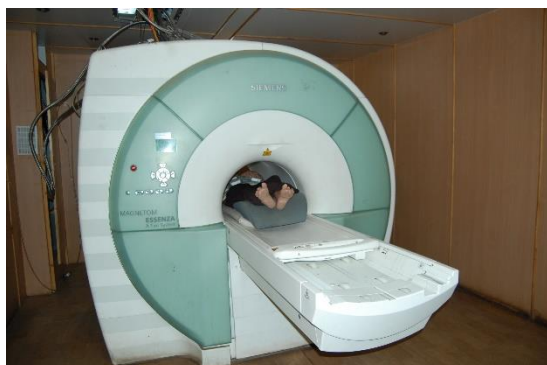**2. Computed Tomography (CT)**

- Equipment - Dual source 16 slice Computed tomography scanner (Bright speed, GE health care, UK)
- Position - supine.
- Coverage area -
  - Whole abdomen.
- Scanning parameters -
  - Helical, thin, overlapping slices.
  - Triple phase abdominal scan.
  - Along with contrast study to be done.

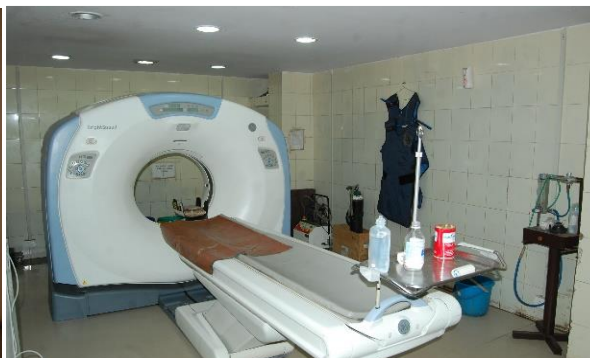**3. Magnetic Resonance Imaging (MRI)**

- Equipment – 1.5 Tesla Magnetic Resonance Imaging system (Magnetom Essenza, Siemens health care, Germany)
- Positioning – Supine.
- Sequences –
  - Axial T1WI, T2WI, PD fat sat.
  - Coronal PD fat sat and STIR.
  - Sagittal PD fat sat.
  - Axial, coronal and sagittal - Contrast T1 Fat sat

	<b>T1WI</b>	<b>T1 Fat sat</b>	<b>T2WI</b>	<b>PD Fat sat</b>	<b>STIR</b>
<b>TR</b>	630	435	4000	3050	3500
<b>TE</b>	12	10	69	37	34
<b>Matrix</b>	256 x 256	256 x 256	256 x 256	256 x 256	256 x 256
<b>Slice thickness</b>	3	3	3	3	3
<b>Section spacing</b>	0.6	0.6	0.6	0.6	0.6
<b>FOV</b>	180	160	160	180	160
<b>Imaging time</b>	2min 35sec	5 min	2min 15sec	4min 20sec	4min 20sec



1.5 Tesla MRI SIEMENS



1.6 Slice CT Scan GE healthcare

**TABLE-1 AGE INCIDENCE**

AGE GROUP	NO OF MALE	NO OF FEMALE	TOTAL
<1-10	1	1	2
11-20	4	3	7
21-30	12	2	14
31-40	23	2	25
41-50	14	1	15
51-60	11	3	14
61-70	5	5	10
>=71	2	1	3
<b>TOTAL</b>	<b>72</b>	<b>18</b>	<b>90</b>

Pancreatic Lesions Were Most Common In 4<sup>th</sup> And 5<sup>th</sup> Decade of Life and Consisted Of 40 Cases (44.44%) And Least Common In 1<sup>st</sup> Decade of Life And Consisted Of Two Cases (2.22%).

**Table-2 SEX INCIDENCE**

Sr NO	TYPE OF LESION	NO OF CASES	MALE	FEMALE
1	ACUTE PANCREATITIS	21	18	3
2	CHRONIC PANCREATITIS	22	15	7
3	ACUTE ON CHRONIC PANCREATITIS	7	7	0
4	PSEUDOCYST	8	8	0
5	PANCREATIC MASS	20	15	5
6	TRAUMA	3	2	1
7	OTHER	7	5	2
8	CONGENITAL ANOMALIES	2	2	0
	<b>TOTAL</b>	<b>90</b>	<b>72</b>	<b>18</b>

Out of 90 cases, 72patients were male (80%) and 18 were females (20%) with male: female ratio is approximately 4:1,

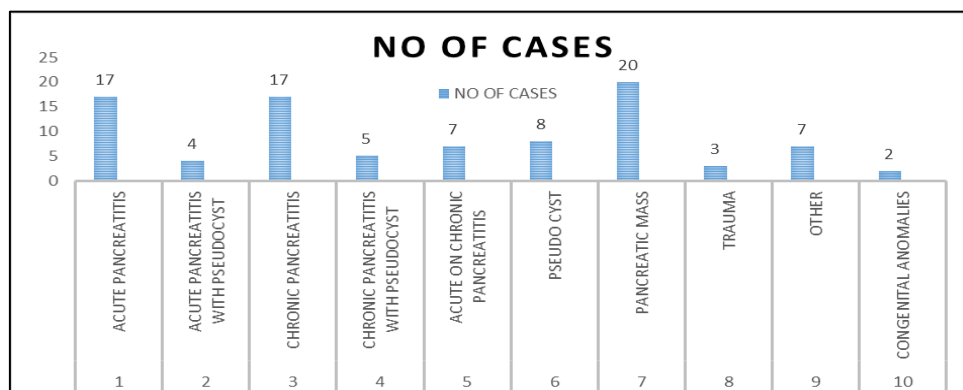
Both Inflammatory And Malignant Disease Of Pancreas Were More Common In Male.

**TABLE-3 TYPE OF PANCREATIC PATHOLOGY**

SR NO	TYPE OF LESION	NO OF CASES	PERCENTAGE
1	ACUTE PANCREATITIS	17	18.8 %
2	ACUTE PANCREATITIS WITH PSEUDOCYST	4	4.44%
3	CHRONIC PANCREATITIS	17	18.8%
4	CHRONIC PANCREATITIS WITH PSEUDOCYST	5	5.55%
5	ACUTE ON CHRONIC PANCREATITIS	7	7.77%
6	PSEUDO CYST	8	8.88%
7	PANCREATIC MASS	20	22.22%
8	TRAUMA	3	3.33%
9	OTHER	7	7.77%
10	CONGENITAL ANOMALIES	2	2.22%
	<b>TOTAL</b>	<b>90</b>	

In this study of 90 cases, chronic pancreatitis was most common pathology consist of 22 cases (24.4%)

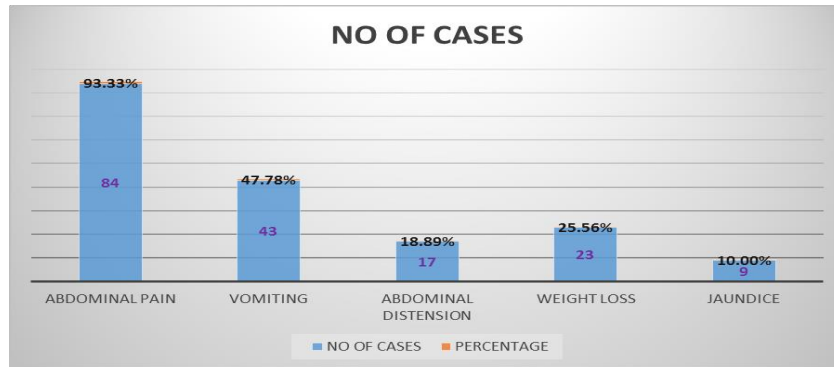
Second most common pathology of pancreas was acute pancreatitis, consisted of 21cases (23.33%) followed by pancreatic malignancy with 20 cases (22.22%).



**TABLE-4 CLINICAL PRESENTATION.**

SYMPTOMS	NO OF CASES	PERCENTAGE
ABDOMINAL PAIN	84	93.3%
VOMITING	43	47.7%
ABDOMINAL DISTENSION	17	18.8%
WEIGHT LOSS	23	25.5%
JAUNDICE	9	10%

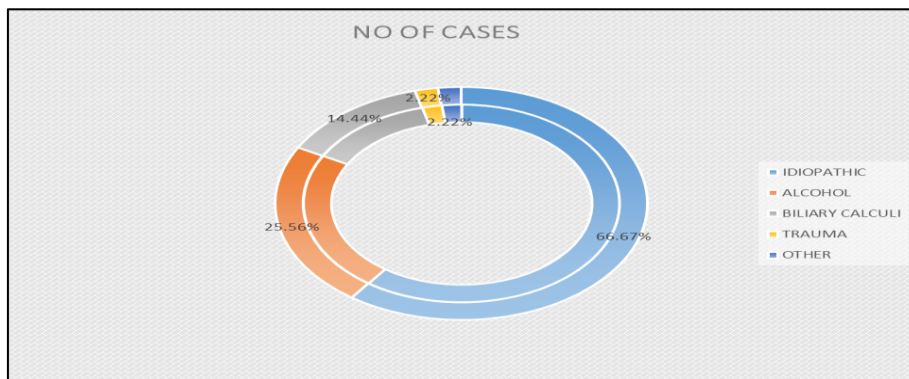
Most common clinical presentation in patient with pancreatic pathology was abdominal pain found in 84 cases (93.3%) followed by vomiting found in 43 cases (47.7%) and weight loss found in 23 cases (25.5%)



**TABLE-5 ETIOLOGICAL ANALYSIS**

ETIOLOGY	NO OF CASES	PERCENTAGE
IDIOPATHIC	60	66.6%
ALCOHOL	23	25.5%
BILIARY CALCULI	13	14.4%
TRAUMA	2	2.22%
OTHER	2	2.22%

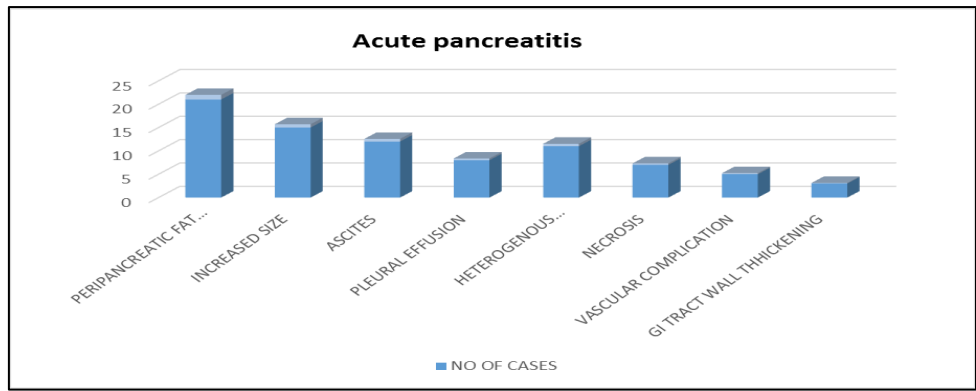
Alcohol (23 cases and 25.5 %) and gall stones (13 cases and 14.4%) are most frequent causative factors where etiology was known, however in a large proportion (66.6%) of patients, no known cause could be attributed (idiopathic).



**TABLE-6 FINDINGS OF ACUTE PANCREATITIS**

FEATURES	NO OF CASES	PERCENTAGE	
PERIPANCREATIC FAT STRANDING	21	100%	
INCREASED SIZE	15	71.42%	
ASCITES	12	57.14%	
PLEURAL EFFUSION	RIGHT	2	38.09%
	LEFT	0	
	BILATERAL	6	
HETEROGENOUS ENHANCEMENT	11	52.38	
NECROSIS	7	26.92	
VASCULAR COMPLICATION	5	19.23	
GI TRACT WALL THICKENING	3	11.53	

Most common findings among all causes of acute pancreatitis were peripancreatic fat stranding comprising all 21 cases (100%) followed by increase in size found in 15 cases (71.42%).



**TABLE-7 DETECTION OF COMPLICATION ON PANCREATITIS**

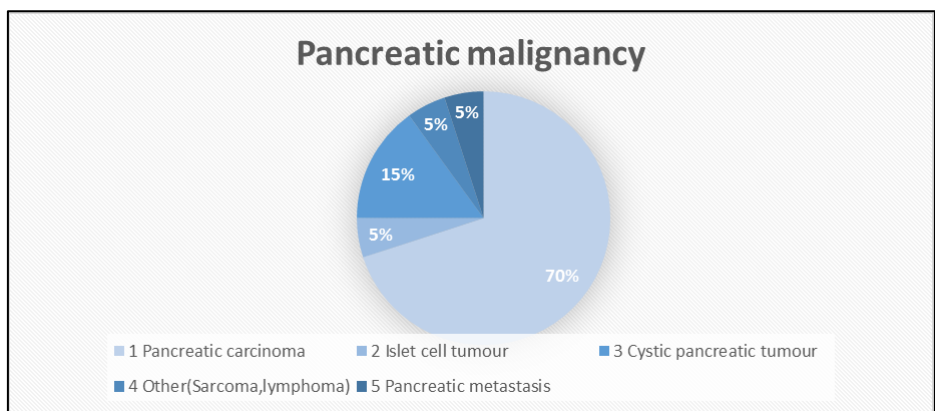
COMPLICATION		NO OF CASES	PERCENTAGE
VASCULAR COMPLICATION	THROMBOSIS	SVT	4
		PVT	2
		SMVT	1
		PSEUDO ANEURYSM	0
PANCREATIC NECROSIS		4	9.30%
PSEUDO CYST		5	11.62%
GI TRACT WALL THICKENING		3	6.97%

Most common complication of pancreatitis was vascular complication consist of 7 cases (16.27%) followed by pseudocyst in 5 cases. (11.62%)

**TABLE-8 TYPE OF PANCREATIC MALIGNANCY**

Sr NO	TYPE OF MALIGNANCY	NO OF CASES	PERCENTAGE
1	PANCREATIC CARCINOMA	14	70%
2	ISLET CELL TUMOUR	1	5%
3	CYSTIC PANCREATIC TUMOUR	3	15%
4	OTHER(SARCOMA,LYMPHOMA)	1	5%
5	PANCREATIC METASTASIS	1	5%
<b>TOTAL</b>		<b>20</b>	

Pancreatic carcinoma were seen in 14 (70%) cases of pancreatic mass and cystic pancreatic tumour in 3 (15%) of cases.



**TABLE-9 SITE OF CARCINOMA IN PANCREAS**

SITE	NO OF CASES	PERCENTAGE
HEAD	10	72%
BODY	4	28%
TAIL	0	0
<b>TOTAL</b>	<b>14</b>	

Out of 14 cases 10 cases had malignancy in head region (72 %) and 4 cases had in body region (28%).



**TABLE-10 CT FEATURES IN PANCREATIC HEAD CARCINOMA (10 CASES)**

FEATURES		NO OF CASES	PERCENTAGE
DENSITY	HYPERDENSE	0	0
	HYPODENSE	6	60%
	ISODENSE	4	40%
DILATED MPD		8	80%
DILATED CBD		4	40%
POST CONTRAST ENHANCEMENT		6	60%
INVASION OF OTHER ORGANS.		3	30%

6 cases (60%) of the pancreatic carcinoma appeared hypodense on nect and showed mild post contrast enhancement in 6 cases (60%), dilated mpd in 8 cases (80%), dilated cbd in 4 cases (40 %) and invasion of other organs were found in 3 cases (30)

**TABLE-11 MRI FEATURES IN PANCREATIC HEAD CARCINOMA (9 CASES)**

FEATURES		NO OF CASES	PERCENTAGE
T2W IMAGES	HYPERINTENSE	8	88.8%
	HYPOINTENSE	1	11.1%
DILATED MPD		9	83.3%
DILATED CBD		2	33.3%
INVASION OF OTHER ORGANS.		1	11.1%

1 case (11.1%) of the pancreatic carcinoma appeared hypointense on t2w images, 8 cases (88.8%) appeared hyperintense on t2w images and dilated mpd and dilated cbd in all cases and invasion of other organs found in one case (11.1%).

**TABLE-12 SONOGRAPHICAL FINDINGS IN PANCREATIC HEAD CARCINOMA (8 CASES)**

FEATURES		NO OF CASES	PERCENTAGE
IMAGES	HYPERECHOIC	0	0
	HYPOECHOIC	8	100%
DILATED MPD		5	50%
DILATED CBD		1	12.5%
INVASION OF OTHER ORGANS.		0	0

8 cases (100%) of the pancreatic carcinoma appeared hypoechoic on sonography, dilated mpd was noted in 6 cases (75%) and dilated cbd in 1 case (12.5%).

**TABLE-13 CT FINDINGS IN PANCREATIC BODY & TAIL CARCINOMA**

FEATURES		NO OF CASES	PERCENTAGE
DENSITY	HYPERDENSE	0	0
	HYPODENSE	4	100%
	ISODENCE	0	0
DILATED MPD		3	75%
DILATED CBD		1	25%
POST CONTRAST ENHANCEMENT		2	50%
INVASION OF OTHER ORGANS.		1	25%

4 Cases (100%) Of The Pancreatic Body & Tail Carcinoma Appeared Hypodense On Nect And Showed Mild Post Contrast Enhancement, Dilated Mpd In 3 Cases (75%) And Dilated Cbd In 1 Cases (25%) Were Noted and Invasion Of Other Oragans Found In 1 Cases.

**TABLE-14 PANCREATIC TRAUMA**

Feature		No of cases	Percentage
Site	Head	1	33.33%
	Body	2	66.66%
	Tail	0	0%
Type of Injury	Deep laceration	1	33.33%
	Superficial laceration	1	33.33%
Peripancreatic fluid		1	33.33%
Duct injury		1	33.33%

Out Of 3 Cases Of Pancreatic Trauma, 1 Case (33.33%) Had Site Of Injury In Head Region And 2 Cases (66.66%) Had Site Of Injury In Body.Peripancreatic Fluid Was Found In All 1 Cases (33.33%). 1 Case (33.33%) Had Superficial Laceration, While 1 Case Had Deep Laceration and 1 Case (33.33%) Had Mpd Injury At Corresponding Site. According To Ragozzino Et Study Site Of Injury Was Most Common In Head Region & Body Region (Each Consist Of 40%) Followed By Tail Region In 20% Cases.According To This 60% Cases Had Superficial Laceration While 40 % Cases Had Deep Laceration.Mpd Injury Was Found In20% Of Cases And Peripancreatic Fluid Was Seen In 100 %.

**TABLE- 15 CT FEATURE OF CHRONIC PANCREATITIS. (22 CASES)**

FEATURE		NO OF CASES	PERCENTAGE
SIZE	NORMAL	0	0%
	ENLARGE	2	9.09%
	ATROPHY	20	90.90%
DENSITY	ISODENSE	0	0
	HYPODENSE	1	4.54%
	HYPERDENSE	21	95.45%
DILATED MPD		15	68.18%
DILATED CBD		6	27.27%
PARENCHYMAL CALCIFICATION		11	50%
MPD CALCULI		3	13.64%

Parenchymal atrophy were found in 20 cases (90.90%) of chronic pancreatitis followed by dilated mpd & parenchymal calcification in 15 cases (68.18%).mpd calculi were seen in 3 cases (13.64%).dilated cbd were seen 6 cases (27.27%)

**TABLE-16 MRI FEATURE OF CHRONIC PANCREATITIS. (18 CASES)**

FEATURE		NO OF CASES	PERCENTAGE
SITE	NORMAL	4	22.22%
	ENLARGE	0	0
	ATROPHY	14	77.77%
T2W IMAGES	ISOINTENSE	12	66.66%
	HYPOINTENSE	6	33.33%
	HYPERINTENSE	0	0
DILATED MPD		15	83.3%
DILATED CBD		5	27.77%
PARENCHYMAL CALCIFICATION		4	22.22%
MPD CALCULI		9	50%

Dilated mpd were found in 15 cases (83.3%) of pancreatitis followed by parenchymal atrophy in 14 cases (77.77%).mpd calculi were seen in 9 cases (50%) & dilated cbd were seen in 5 cases (27.77%).parenchymal calcification was seen in 4 cases (22.22%).

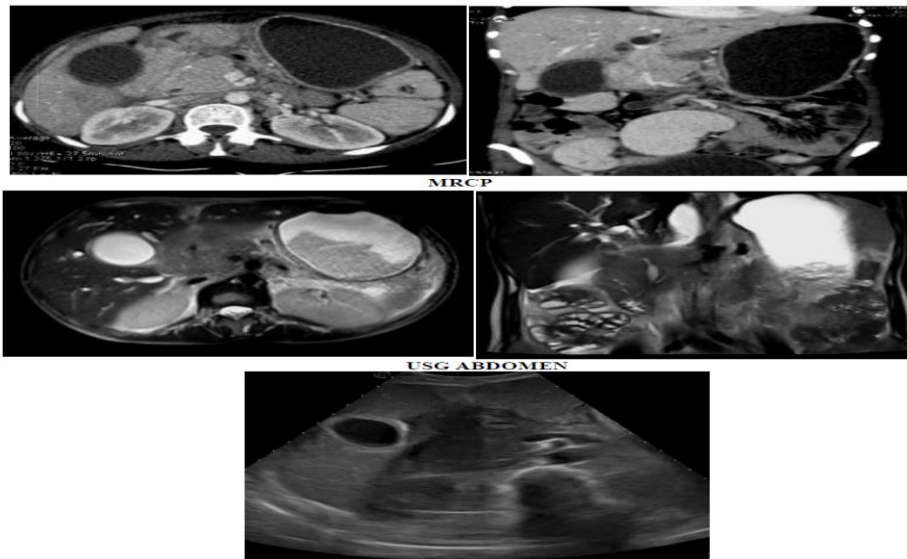
**TABLE-17 SONOGRAPHICAL FEATURE OF CHRONIC PANCREATITIS. (17 CASES)**

FEATURE		NO OF CASES	PERCENTAGE
SITE	NORMAL	4	23.52%
	ENLARGE	0	0
	ATROPHY	13	76.48%
IMAGES	ISOECHOIC	4	23.52%
	HYPOECHOIC	0	0
	HYPERECHOIC	13	76.48%
DILATED MPD		11	64.47%
DILATED CBD		6	35.29%
PARENCHYMAL CALCIFICATION		2	11.76%
MPD CALCULI		8	47%

Hyper echogenicity with atrophic changes were found in 13 cases (76.48%) followed by dilated mpd were found in 11 cases (64.47%) of pancreatitis. Mpd calculi were seen in 8 cases (47%) & dilated cbd were seen in 6 cases (35.29%).parenchymal calcification was seen in only 2 case (11.76%)

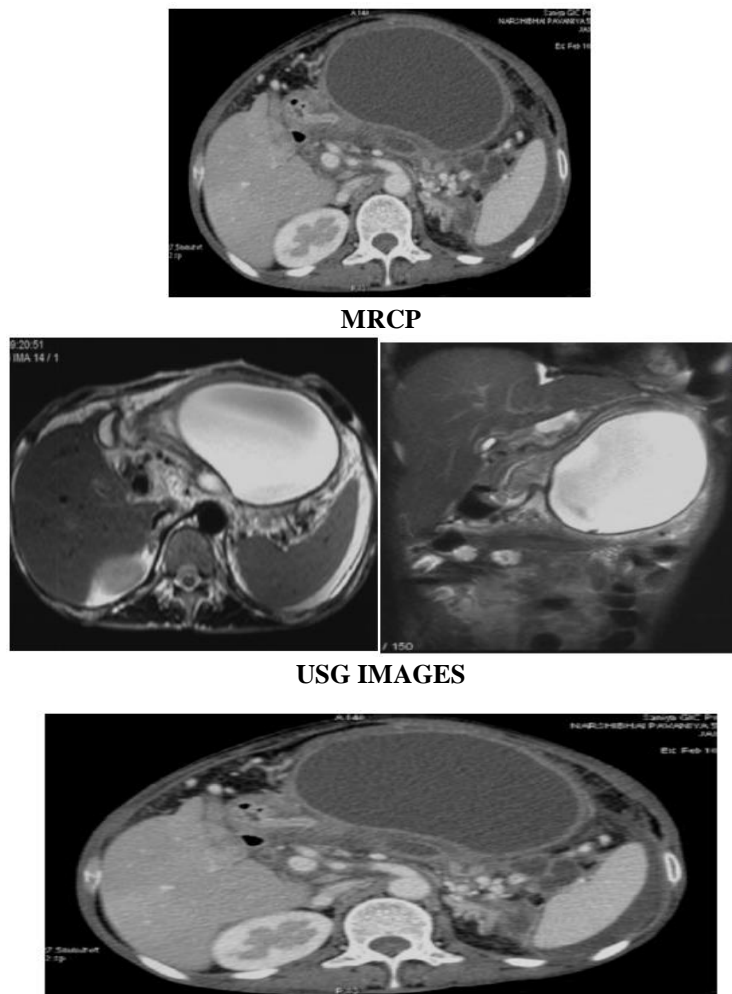


**CASES**  
**ANNULAR PANCREAS- CASE 78**  
**CECT ABDOMEN**



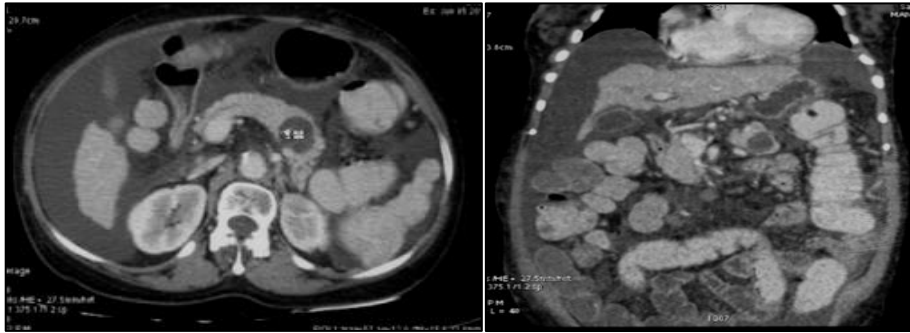
- Pancreatic tissue is seen surrounding second part of duodenum with narrowing of duodenal lumen.

**CHRONIC PANCREATITIS WITH PSEUDOCYST FORMATION CASE- 59**  
**CECT ABDOMEN**

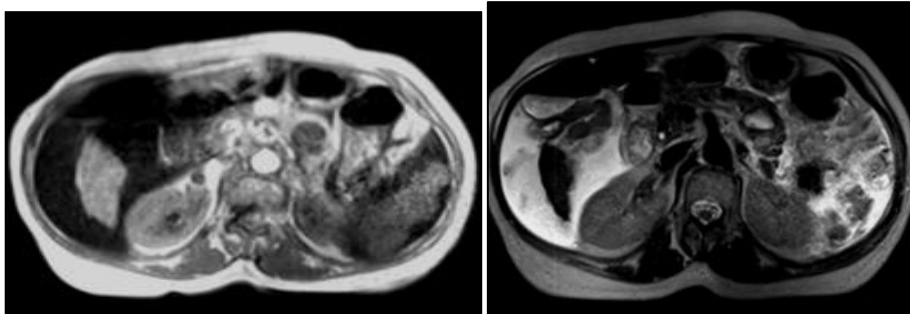


- Diffusely atrophied tail of pancreas with hypodense cystic lesion with internal non-enhancing part with in relation to tail of pancreas.

**SEROUS CYSTADENOMA CASE-53  
CECT ABDOMEN**



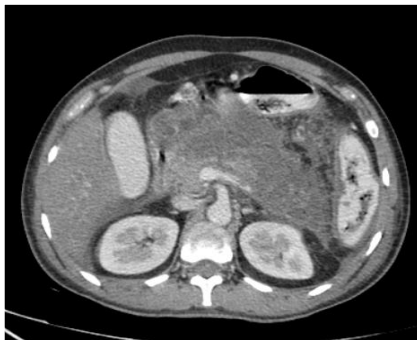**MRCP**



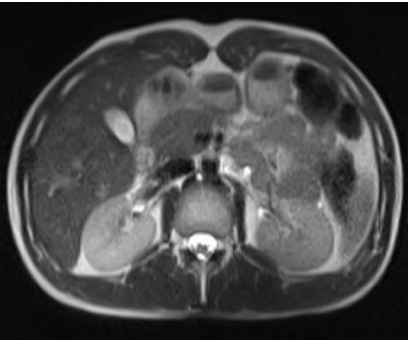
- Lobulated cystic mass lesion is noted involving body and tail of pancreas with central scar.
- 

**NECROTIC PANCREATITIS-CASE 36**

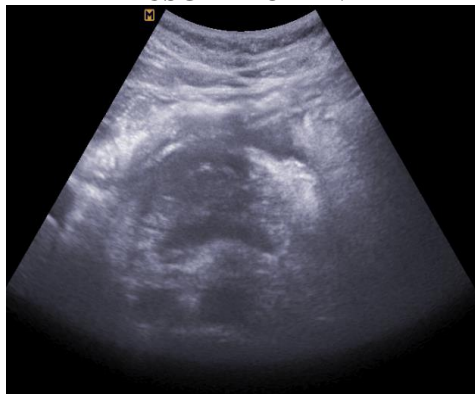
**CECT ABDOMEN**



**MRCP**



**USG ABDOMEN**

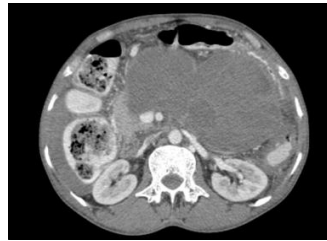


- Multiple internal non enhancing necrotic areas in its neck, body and tail region of pancreas.

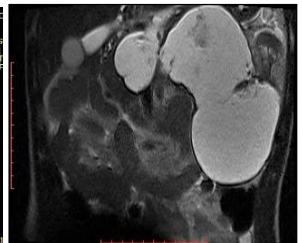
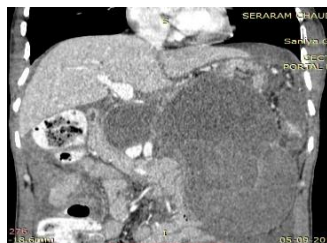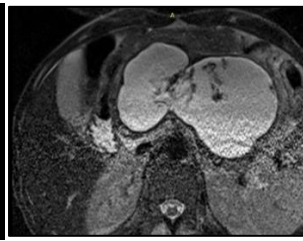


**PSEUDOCYST-CASE-84**

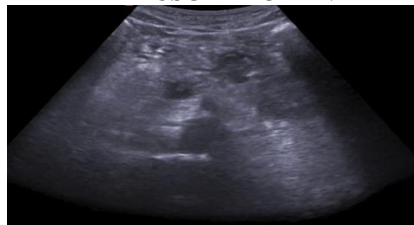**CECT ABDOMEN**



**MRCP**



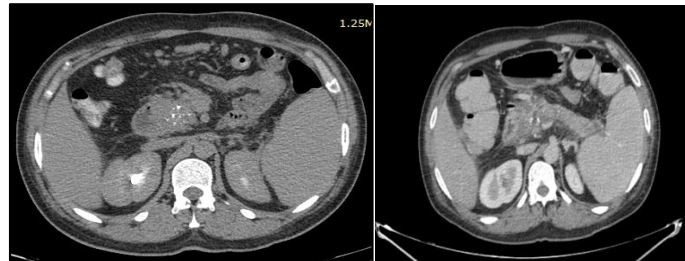
**USG ABDOMEN**



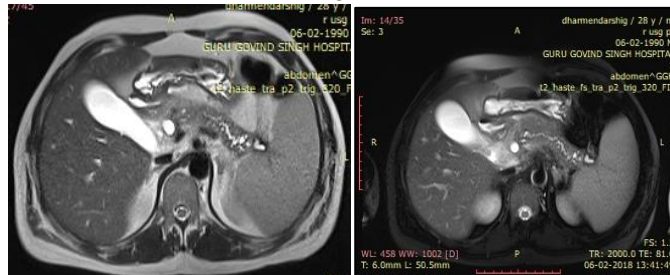
- Pseudocyst involving neck, body and tail region, it lies in close relation with liver and stomach, transverse colon and few small bowel loops, moderate ascites is noted with internal hyper-dense content.

**CHRONIC PANCREATITIS-CASE-20.**

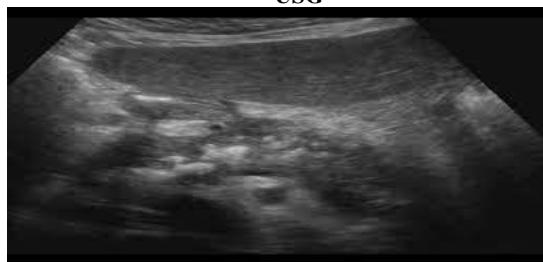**CECT ABDOMEN**



**MRCP**



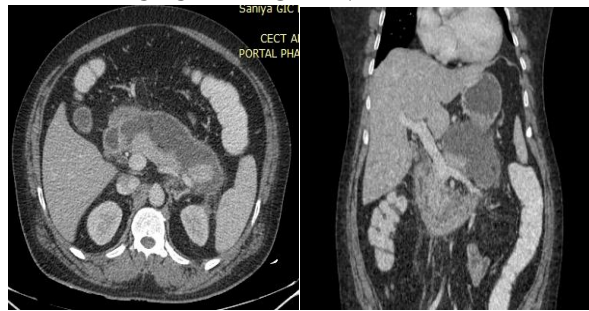
**USG**



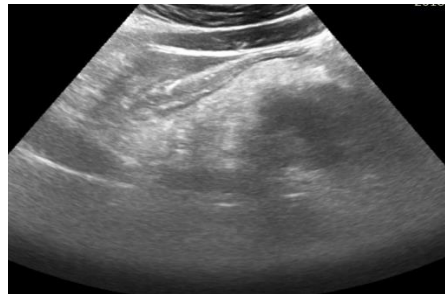
- Multiple tiny foci of calcification are noted in pancreatic head, uncinata process and proximal body.



**PANCREATIC COLLECTION-CASE-2  
CECT ABDOMEN**

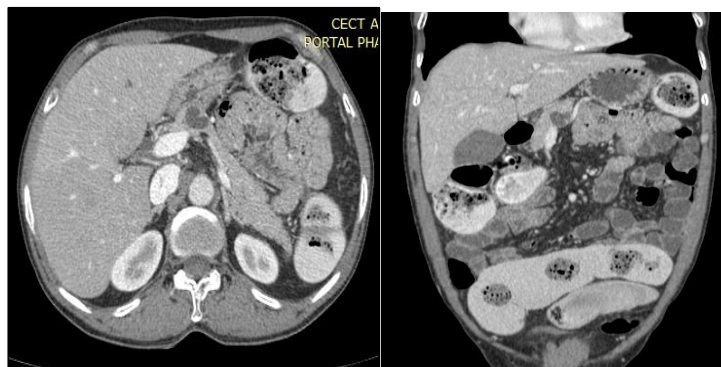


**USG ABDOMEN**

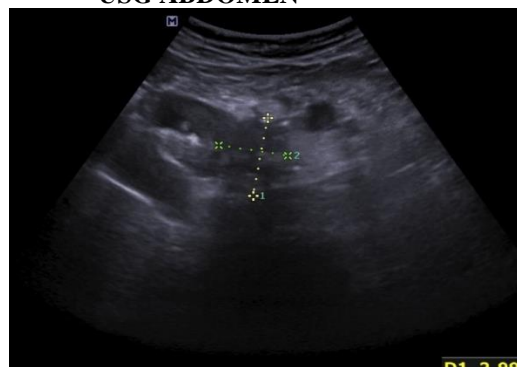

- Well defined thin walled peripherally enhancing collection in the region of head, neck, body and tail of pancreas.

**CYCTIC LESION-CASE-27  
CECT ABDOMEN**

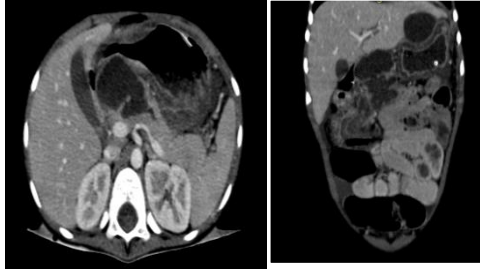


**USG ABDOMEN**



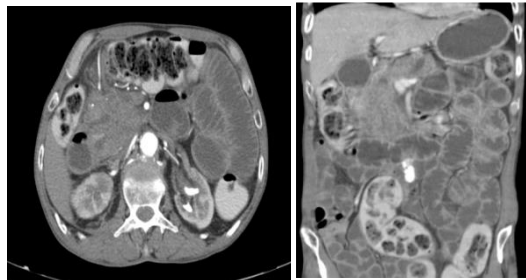
- A well-defined thin walled non-enhancing cystic lesion in neck of pancreas.

**PANCREATIC TRAUMA- CASE -79.**



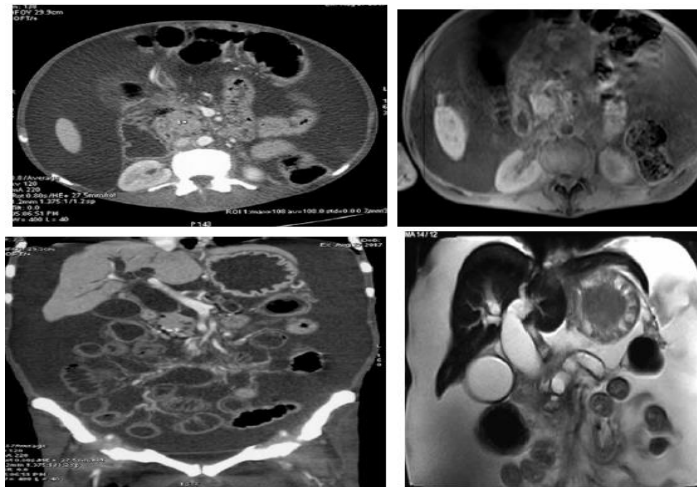
- Well defined collection is noted communicating with MPD in a case of RTA.

**PANCREATIC DIVISUM-CASE 61.  
CECT ABDOMEN**



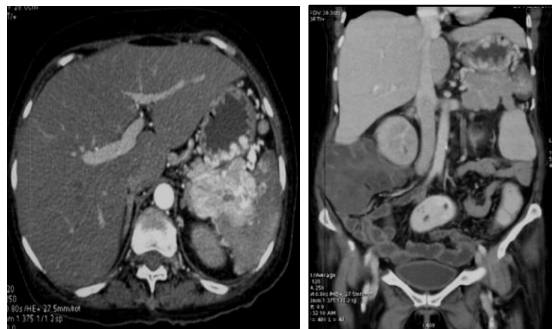- The dorsal pancreatic duct drains into the minor ampulla. The ventral duct joins the dorsal duct to drain into minor papilla

**CARCINOMA HEAD OF PANCREAS- CASE-24  
CECT ABDOMEN MRI ABDOMEN**



- Neoplastic mass lesion is noted involving pancreatic head with resultant proximal biliopathy.

**ENDOCRINE NEOPLASM-CASE-76.**



- Heterogeneously enhancing lesion is noted involving pancreatic tail.



**DISCUSSION**

- In this study 90 cases of suspected pancreatic lesions were studied by CT scan and/or MRI and/or USG as a prime modality. Correlation of diagnosis was done with USG features, laboratory investigations and histopathological examination reports whenever possible, a follow up done about the outcome of patients after treatment.
- Pancreatic Etiology was found in wide range of age groups. I.e. from 1 to 70 years with maximum incidence in 4rd & 5th decade [44.44% cases]. Pancreatic lesions were more common in males [80%] than females [20%].
- Commonest presenting symptoms were abdominal pain [93.30%] and vomiting [47.7%].
- Alcoholism [25.5%] and gall stones [14.4%] were commonest etiology. DC. Whitecomb suggest that alcohol and gall stone are the most common cause of acute pancreatitis.
- Among pancreatic pathology in descending order, chronic pancreatitis was most common pathology comprising 22 cases [24.4%]. Acute pancreatitis consist of 21 cases [23.33%]. Pancreatic malignancy consist of 20 cases [22.2%]. Acute on chronic pancreatitis had 7 cases [7.77%]. Pseudocyst has 8 & trauma had 3 cases. One case

of annular pancreas & one case of pancreatic divisum were present.

- Clinically suspected patients were underwent prior laboratory investigations and USG examination.
- Pancreatic enzymes [S. amylase, S. lipase] rise during acute pancreatitis. S.lipase was found to be increased in all cases in which it was done, because of its cost effectiveness limiting its widespread use. S.amylase was raised in 19 cases out of total 21 cases of acute pancreatitis. According to PA. Banks study, the clinical diagnosis of acute pancreatitis is supported by an elevation of the serum amylase and lipase often in excess of three times the upper limit of normal.
- As USG has got many advantages like easy availability, cost effectiveness, non-invasive, no radiation hazards and can be repeated as when required, it was done in every case before a CT and/or MRI.
- On CT and/or MRI examination of patients with acute pancreatitis, most common finding was peripancreatic fat stranding 21 case(100%). increase in size 15 cases (71.42%) followed by ascites 12 case(57.14%), pleural effusion in 8 cases (38.09 %), heterogeneous enhancement in 11 cases (52.38%) , necrosis in 7 cases(26.92%) .

**Out of 21 cases with positive findings of acute pancreatitis, 20 cases were diagnosed as acute pancreatitis on CT. One case which did not responded to treatment, turned out to be malignancy on further biopsy. (Case no 39).**

FEATURES	NO OF CASES	PERCENTAGE	BOLLEN ET AL
PERIPANCREATIC FAT STRANDING	21	100%	-
INCREASED SIZE	15	71.42%	-
ASCITES	12	57.14%	41%
PLEURAL EFFUSION	RIGHT	38.09%	35%
	LEFT		
	BILATERAL		
HETEROGENOUS ENHANCEMENT	11	52.38	-
NECROSIS	7	26.92	17.85%
VASCULAR COMPLICATION	5	19.23	8%
GI TRACT WALL THICKENING	3	11.53	5%

- Among the complications of acute pancreatitis, vascular complication was the most common followed by pseudo cyst and necrosis.
- Vascular complication consist of 7 cases (16.27 %) followed by pseudo cyst in 5 cases (11.62%) and pancreatic necrosis in 4 cases (9.30%), and GI wall thickening in 3 cases (6.97%).
- Among vascular complication venous thrombosis was most common consisted of 7 cases [16.27%] with splenic vein involvement was most common. Pseudo aneurysm of gastro duodenal artery was seen in 2 cases and of splenic artery in one case.

- Out of 20 cases of pancreatic masses, pancreatic adenocarcinoma consist of highest 14(70%) cases, islet cell tumor consist of 1(5%) cases, cystic pancreatic tumor had 3 cases and each metastasis & sarcoma had 1 case.
- Out of 14 cases of pancreatic carcinoma, 10cases (72%) were found in head region, 4 cases (28%) in body. Among pancreatic malignancy, adenocarcinoma was most common and it was most commonly found in head region. In Clark study majority (60%) of pancreatic carcinoma occur in the head, whereas 20% and 10% occur in the body and tail, respectively.

SITE	NO OF CASES	PERCENTAGE	CLARK ET AL
Head	10	72%	60%
Body	4	28%	20%
Tail	0	0	10%
<b>TOTAL</b>	<b>14</b>		

- Pancreatic carcinoma is a hypo vascular mass so it does not enhance at all or show a mild enhancement on post contrast study. In this study out of 10 cases, 6 cases showed mild post contrast enhancement.
- On CECT examination, out of 10 cases of head mass, all 6 cases were hypo dense(60%) and showed dilated MPD in 8 cases(80.00%) which were most common finding.
- On MRI examination, out of 9 cases of head carcinoma, 8 appeared hyper intense & 1 appeared hypo intense and showed dilatation of MPD & CBD in 9 cases and invasion of organ in one case.
- Out of 10 cases of head carcinoma, 1 (16.6%) case showed distal metastasis in liver.
- Out of 4 cases of body-tail mass, all 4 appeared hypo dense on NCCT. Distant metastasis and dilated MPD were found in 3 cases and CBD was dilated in one case of body mass.
- Study by McNulty et al shows sensitivity of MDCT for detection of pancreatic carcinoma is 96 %.
- Out of 3 cases of trauma, common site of injury was body (66.66%), laceration was found in 1 cases (33.33% ) Peripancreatic fluid and duct injury were seen in 1 case (33.33%).

Feature	No of cases	Percentage	Ragozzino et
Site	Head	1	33.33%
	Body	2	66.66%
	Tail	0	0%
Type of Injury	Deep laceration	1	33.33%
	Superficial laceration	1	33.33%
Peripancreatic fluid	1	33.33%	100%
Duct injury	1	33.33%	20%

Specific CT findings of pancreatic injury include fracture of the pancreas, pancreatic laceration, focal or diffuse pancreatic enlargement or edema, pancreatic hematoma, and active bleeding or extravasations of intravenous contrast material. Fluid separating the splenic vein and the pancreas is highly suggestive of pancreatic injury.

- Teh SH and his colleague suggest that, MDCT is 91% sensitive and 91% Specific for pancreatic ductal injury.
- On CECT examination out of 22 cases, parenchymal atrophy were found in 20 cases (90.90%) of chronic pancreatitis followed by calcification and dilated MPD calculus (68.18%). MPD calculi were seen in 13.64% cases. Dilated CBD were seen in 6 (27.27%).
- Leutmer et al in their study on patient of chronic pancreatitis found dilatation of MPD in 68%, parenchymal atrophy in 54%, parenchymal calcification in 50%, focal pancreatic enlargement in 30% and biliary duct dilatation in 29% patient (23).

Feature	No of cases	Percentage	Leutmer et al
Size	Normal	0	-
	Enlarge	2	9.09%
	Atrophy	20	90.90%
Density	Isodense	0	-
	Hypodense	1	4.54%
	Hyper dense	21	95.45%
Dilated MPD	15	68.18%	68%
Dilated CBD	6	27.27%	29%
Parenchymal calcification	11	50%	50%
MPD calculi	3	13.64%	-

- On MRI examination out of 18 cases of chronic pancreatitis dilated MPD in 15 cases (83.3%), followed by parenchymal atrophy were found in 14 cases (77.77%). MPD calculi were seen in 50 %

cases. Dilated CBD were seen in 27.77% cases. Parenchymal calcification was seen in 4 cases (22.22%).

- On comparing the findings of CT and MRI examination, MRI had higher sensitivity in detecting dilatation of C80 & MPD as well as MPD calculi while CT scan had higher sensitivity in detecting in parenchymal calcifications.
- Chronic pancreatitis and pancreatic carcinoma share many features on CT, which makes differentiation difficult. Further, it can be challenging and sometimes impossible to differentiate between the two conditions on USG. Gerstenmaier and Malone proposed a diagnostic algorithm based on Bayesian analysis and

recommended EUS and fine needle aspiration as next steps when a mass is detected on USG or CT.

- Both CT scan & MRI was done in case of pancreatic divisum and annular pancreas. On CT scan possibility of annular pancreas was kept which on latter confirmed by MRI. MRI more definitely show winding of pancreatic tissue around 2nd part of duodenum.
- Diagnosis of pancreatic divisum was missed on CT scan and showed only presence of focal head pancreatitis while MRI (MRCP) definitely showed the diagnosis of pancreatic divisum by Opening of dorsal duct system through duct of Santorini in to minor papilla.

**Comparision with Other Standard Studies.**

**1. Comparative study for pancreatic mass lesion.**

**COMPARISION WITH OTHER STUDY FOR PANCREATIC MASS LESION IN CT.**

	Sensitivity	Specificity
Fortschr Röntgenstr	100%	77%
Current study	80%	60%

**COMPARISION WITH OTHER STUDY FOR PANCREATIC MASS LESION IN MRI.**

	Sensitivity	Specificity
Fortschr Röntgenstr	75%	77%
Current study	83%	88.8%

**COMPARISION WITH OTHER STUDY FOR PANCREATIC MASS LESION IN USG.**

	Sensitivity	Specificity
Joseph et al	70%	60%
Current study	60%	62.5%

MDCT and MRI are equally able to categorize all pancreatic lesions in neoplastic condition but MRI because of its higher soft tissue resolution capacity able to differentiate from malignancy.

**2. Comparative study for chronic pancreatitis.**

**COMPARISION WITH OTHER STUDY FOR CHRONIC PANCREATITIS IN CT.**

	Sensitivity	Specificity
Y.ISSA	77%	82%
Current study	86.36%	90.90%

**COMPARISION WITH OTHER STUDY FOR CHRONIC PANCREATITIS IN MRI.**

	Sensitivity	Specificity
Y.ISSA	62%	94%
Current study	64%	83.3%

**COMPARISION WITH OTHER STUDY FOR CHRONIC PANCREATITIS IN USG.**

	Sensitivity	Specificity
Trond Engjom	69%	97%
Current study	64.47%	76.48%

- MDCT scan is most important and single modality to evaluate the patients with chronic pancreatitis though MRI (MRCP) is more sensitive in detecting the dilatation of MPD, biliary tract dilatation and for detection of MPD calculi.

### 3. COMPARATIVE STUDY FOR ACUTE PANCREATITIS.

#### COMPARISON WITH OTHER STUDY FOR ACUTE PANCREATITIS IN CT.

	Sensitivity	Specificity
Bollen et al	100%	100%
Current study	100%	95%

#### COMPARISON WITH OTHER STUDY FOR ACUTE PANCREATITIS IN MRI.

	Sensitivity	Specificity
Bollen et al	76%	81%
Current study	70%	85%

#### COMPARISON WITH OTHER STUDY FOR ACUTE PANCREATITIS IN USG.

	Sensitivity	Specificity
Awdhut Tiparse	58%	34%
Current study	62%	37%

Study shows that MDCT scan is most important single modality to evaluate the patients with acute pancreatitis.

#### CONCLUSION:

- In this study 90 cases of pancreatic lesions were studied by MDCT scan and/or MRI scan.
- Pancreatic lesions were more common in males [80%] than females [20%]. They were most common in age group of 4th to 5th decade [44.44%] and least common in 1<sup>st</sup> decade of life [2.22%].
- Chronic pancreatitis was the commonest pancreatic pathology [24.4%].
- Commonest presenting symptoms were abdominal pain [93.3%] and vomiting [47.7%].
- Alcoholism [25.5%] and gall stones [14.4%] were commonest etiology.
- MDCT and/or MRI findings were confirmed on histopathological examination reports whenever possible, a follow up done about the outcome of patients after treatment.
- In this study, MDCT and MRI were 100% sensitive in detecting all pancreatic abnormality [pancreatitis and its complication, pancreatic trauma and pancreatic neoplasm.
- MDCT and MRI were able to categorize all pancreatic lesions in inflammatory and neoplastic condition and evaluate extent of disease process except, focal mass in chronic pancreatitis where MDCT was not able to differentiate between inflammation and carcinoma. MRI because of its higher soft tissue resolution capacity able to differentiate from malignancy in some cases. Ultimately FNAC is required to differentiate it from malignancy.
- Diffusion weighted MRI have also role in section of acute pancreatitis because it gives restriction on diffusion weighted images
- Thus we conclude that MDCT scan is most important single modality to evaluate the patients with pancreatic diseases and MRI can be used as supplement to CT to add on more information. USG is important as first line of investigation and for follow up, as it is cheap and can be done whenever needed.
- For detection of congenital anomalies like annular pancreas and pancreatic divisum MRI (MRCP) is the imaging modality of choice.
- MRI (MRCP) is more sensitive in detecting the dilatation of MPD, biliary tract dilatation and for detection of MPD calculi.
- MDCT is more sensitive than MRI for detection of pancreatic parenchymal calcification.
- USG can be done as baseline study, for follow up assessment and quick assessment for status of patient.

#### REFERENCE

1. Schulte, S. J. (1994). Embryology, normal variation, and congenital anomalies of the pancreas. *Margulis and Burhenne's alimentary tract radiology. 5th ed. St Louis: Mo Mosby*, 1039-51.
2. Mortel , K. J., Rocha, T. C., Streeter, J. L., & Taylor, A. J. (2006). Multimodality imaging of pancreatic and biliary congenital anomalies. *Radiographics*, 26(3), 715-731.
3. Agur, A.M.R., Lee, M.J., & Grant, J.C.B. (1999). *Grant's Atlas of Anatomy. 10<sup>th</sup> ed.* London, UK: Lippincott Williams and Wilkins.

4. Romanes, G.J. (1986). Cunningham's manual of practical anatomy vol II. 15<sup>th</sup> ed. New York. NY: Oxford Medical Publications. Oxford University Press.
5. Grant, J.C.B., Basmajian, J.V., & Slonecker, C.E. (1989). Grant's method of anatomy: a clinical problem-solving approach. 11th ed. London, UK: Williams and Wilkins.
6. Gray, H., Lewis, W.H., (2000). ed. Gray's anatomy of the human body. 20<sup>th</sup> Ed. New York, NY: Bartleby.
7. Sinnatamby, C.S. (1999). Last's anatomy: regional and applied. 10<sup>th</sup> ed. Edinburgh.
8. UK' Churchill Livingstone.
9. Kasper, D., Braunwald, E., Fauci, A., Hausar, S., Longo, D., Jameson, L. (2008). Harrison's principles of internal medicine. 17<sup>th</sup> ed. New York: McGraw- Hill,1895-1905.
10. Tumen, H. J. (1961). Pathogenesis and classification of pancreatic disease. *Digestive Diseases and Sciences*, 6(5), 435-440.
11. John, R. Hagga, Vikram, S., Dogra, M. F., Robert, C., Gilkeson, Hyun, K. H.I. Murali, S. CT and MR imaging of whole body.
12. Yu, J., Turner, M. A., Fulcher, A. S., & Halvorsen, R. A. (2006). Congenital anomalies and normal variants of the pancreaticobiliary tract and the pancreas in adults: part 2, Pancreatic duct and pancreas. *American Journal of Roentgenology*, 187(6), 1544-1553.
13. Balthazar, E. J., Ranson, J. H., Naidich, D. P., Megibow, A. J., Caccavale, R., & Cooper, M. M. (1985). Acute pancreatitis: prognostic value of CT. *Radiology*, 156(3), 767-772.
14. Balthazar, E. J., Robinson, D. L., Megibow, A. J., & Ranson, J. H. (1990). Acute pancreatitis: value of CT in establishing prognosis. *Radiology*, 174(2), 331-336.
15. Bodurtha, A. J., Dajee, H., & You, C. K. (1980). Analysis of 29 cases of pancreatic pseudocyst treated surgically. *Canadian journal of surgery. Journal canadien de chirurgie*, 23(5), 432-434.
16. Jeffrey, R.B., Federle, N.I.P., Cello, J.P., Crass, R.A. (1982). Early computed tomographic a. scanning in acute severe pancreatitis. *Surg Gynecol Obstet*, 154, 170.
17. Ferrucci Jr, J. T., Wittenberg, J., Black, E. B., Kirkpatrick, R. H., & Hall, D. A. (1979). Computed body tomography in chronic pancreatitis. *Radiology*, 130(1), 175-182.
18. Gerstenmaier, J. F., & Malone, D. E. (2011). Mass lesions in chronic pancreatitis: benign or malignant? An "evidence-based practice" approach. *Abdominal imaging*, 36(5), 569-577.
19. McNulty, N. J., Francis, I. R., Platt, J. F., Cohan, R. H., Korobkin, M., & Gebremariam, A. (2001). Multi-detector row helical CT of the pancreas: effect of contrast-enhanced multiphase imaging on enhancement of the pancreas, peripancreatic vasculature, and pancreatic adenocarcinoma. *Radiology*, 220(1), 97-102.
20. Vellet, A. D., Romano, W., Bach, D. B., Passi, R. B., Taves, D. H., & Munk, P. L. (1992). Adenocarcinoma of the pancreatic ducts: comparative evaluation with CT and MR imaging at 1.5 T. *Radiology*, 183(1), 87-95.
21. Semelka, R. C., Kelekis, N. L., Molina, P. L., Sharp, T. J., & Calvo, B. (1996). Pancreatic masses with inconclusive findings on spiral CT: is there a role for MRI?. *Journal of Magnetic Resonance Imaging*, 6(4), 585-588.
22. Sahani, D. V., Kadavigere, R., Saokar, A., Fernandez-del Castillo, C., Brugge, W. R., & Hahn, P. F. (2005). Cystic pancreatic lesions: a simple imaging-based classification system for guiding management. *Radiographics*, 25(6), 1471-1484.
23. Balthazar, E. J., Subramanyam, B. R., Lefleur, R. S., & Barone, C. M. (1984). Solid and papillary epithelial neoplasm of the pancreas. Radiographic, CT, sonographic, and angiographic features. *Radiology*, 150(1), 39-40.
24. Van Hoe, L., Gryspeerdt, S., Marchal, G., Baert, A. L., & Mertens, L. (1995). Helical CT for the preoperative localization of islet cell tumors of the pancreas: value of arterial and parenchymal phase images. *AJR. American journal of roentgenology*, 165(6), 1437-1439.
25. <https://www.ncbi.nlm.nih.gov/pmc/articles/PMC2441321/pdf/tacca00108-0268.pdf> (Results for pancreatic pathology).