

## Case Report

## Clear Cell Sarcoma of Kidney in a Pediatric Patient- A Case Report

Tooba Kareem<sup>1</sup>, Touqeer Ahmed Sulehria<sup>1</sup>, Waqas Ahmad<sup>1</sup> and Palwasha Gul<sup>1\*</sup><sup>1</sup>Shaukat Khanum Memorial Cancer Hospital and Research Center Lahore, Pakistan\*Corresponding Author  
Dr Palwasha Gul

**Abstract:** Clear cell sarcoma of kidney is a rare pediatric renal tumor. Its diagnosis is challenging for a clinician and radiologist due to its overlapping clinical and radiological presentation with much common Wilm's tumor. We present case report of 2-year-old boy presented with abdominal discomfort and lumbar region mass for 2 months. The patient underwent routine work up including CT abdomen which demonstrated a mass arising from renal medulla crossing midline. Image guided biopsy followed by histopathology confirmed it as clear cell sarcoma rather than Wilm's tumor. Metastatic work up remained negative. He underwent neoadjuvant chemotherapy regimen followed by surgical resection with no immediate or long-term complications.

**Keywords:** Clear cell sarcoma, wilms tumor, CT.

## INTRODUCTION

Clear cell sarcoma is one of extremely rare pediatric renal tumor making up to only 3% of all renal tumors in children. Clinical features include abdominal mass with or without hematuria and occasionally bone pain usually in age group up to 1 to 4 years with male to female ratio of 2:1. Wilm's tumor remains the most common pediatric renal tumor comprising over 85% of the cases presenting with renal mass. Since clinical features overlap, this makes diagnosis difficult.

## CASE REPORT

2 years old boy presented to OPD clinic with complaints of progressively increasing swelling in left lumbar region from past two months followed by abdominal distension, off and on constipation as per history given by the mother of patient. No complaint of gross hematuria. Ultrasound abdomen was performed

which showed a large mass arising from left kidney. First impression of wilm's tumor was made by the physician. Further workup with CT abdomen revealed 13 x 10 x 8.5 cm heterogeneously enhancing mass arising from medulla of the left kidney. No internal calcification or pathological lymph nodes were seen. Rest of the scan was unremarkable. Again an impression of stage II wilm's tumor with the differentials of rhabdomyosarcoma, clear cell sarcoma and neuroblastoma was made. Histopathology of this mass turned out to be clear cell sarcoma. Renogram was performed to see the functional status of both kidneys in which left kidney was not visualized. Flow study in right kidney showed prompt perfusion and good cortical uptake followed by prompt corticopelvic transit. Metastatic workup was negative. After multidisciplinary clinical meeting multi agent chemotherapy was planned as initial treatment.

Quick Response Code



Journal homepage:

<http://www.easpublisher.com/easjrit/>

Article History

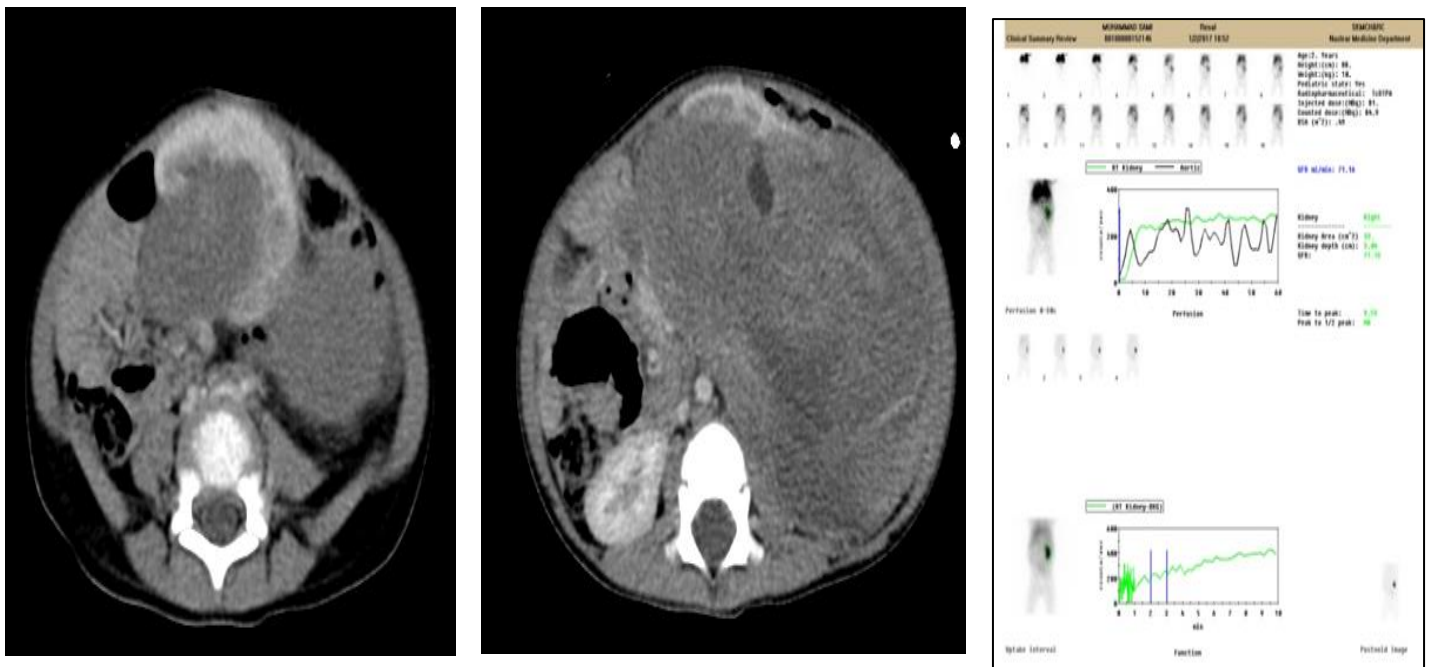
Received: 15.09.2019

Accepted: 26.09.2019

Published: 08.10.2019

**Copyright © 2019 The Author(s):** This is an open-access article distributed under the terms of the Creative Commons Attribution 4.0 International License (CC BY-NC 4.0) which permits unrestricted use, distribution, and reproduction in any medium for non-commercial use provided the original author and source are credited.

DOI: 10.36349/easjrit.2019.v01i05.002



**Fig.(a,b) Axial contrast enhanced CT images showing heterogeneously enhancing mass with internal cystic change arising from left renal medulla, right kidney is normal (c) Renogram image with no visualization of left kidney.**

**DISCUSSION**

Clear cell sarcoma of the kidney is one of the rarest pediatric renal tumors comprising of only 3 % primary renal neoplasms in pediatric age group. It typically presents with complaint of palpable gradually increasing abdominal mass or swelling in less than 4 years of age children. Radiological assessment of clear cell sarcoma of the kidney shows heterogeneously enhancing mass on contrast enhanced CT abdomen which is seen arising from the medulla of the kidney with internal non-enhancing foci representing necrosis and hemorrhagic components. They usually cross midline. Lack of calcifications is typical feature seen on CT. MRI shows low to intermediate signal on T1 weighted images and high signal on T2W1 with cystic areas.

Wilm’s accounting for over 85% of the cases remains most common renal tumor with similar clinical features. On imaging Wilm’s also appear as a heterogeneous solid mass crossing the midline and displaces adjacent structures. Occasionally it can be cystic. Wilm’s tumor most commonly metastasizes to lungs followed by liver and local lymph nodes. Similar to renal cell carcinoma in adults it can send tumor thrombus into the renal vein, IVC and right atrium. Pulmonary metastasis can be seen at initial presentation as well.

Treatment options for clear cell sarcoma remain chemotherapy and radiotherapy.

**CONCLUSION**

Wilm’s tumor and clear cell sarcoma overlap in presentations. Imaging usually CT though can well differentiate on basis of features but remain challenging for radiologists. Wilm’s commonly metastasizes to lungs whereas clear cell sarcoma most commonly metastasizes to bones.

**REFERENCES**

1. Sandstedt, B. E., Delemarre, J. F. M., Harms, D., & Tournade, M. F. (1987). Sarcomatous Wilms’ tumour with clear cells and hyalinization. A study of 38 tumours in children from the SIOP nephroblastoma file. *Histopathology*, 11(3), 273-285.
2. Murphy, W.M., Beckwith, J.B., & Farrow, G.M. (1993). Tumors of the kidney. In: Murphy WM, editor. *Tumors of the Kidney, Bladder and Related Urinary Structures*. Washington D.C.: The Armed Forces Institute of Pathology, p. 67-81.
3. Marsden, H. B., Lawler, W., & Kumar, P. M. (1978). Bone metastasizing renal tumor of childhood. Morphological and clinical features, and differences from Wilms' tumor. *Cancer*, 42(4), 1922-1928.
4. Ogawa, K., Nakashima, Y., Yamabe, H., & Hamashima, Y. (1986). Clear cell sarcoma of the kidney An immunohistochemical study. *Pathology International*, 36(5), 681-689.
5. Haas, J. E., Bonadio, J. F., & Beckwith, J. B. (1984). Clear cell sarcoma of the kidney with emphasis on ultrastructural studies. *Cancer*, 54(12), 2978-2987.