

## Review Article

# A Brief Study on Abscess: A Review

Jyoti Nayak<sup>1\*</sup>, Jai Narayan Mishra<sup>2</sup>, Navneet Kumar Verma<sup>3</sup>

<sup>1</sup>Assistant Professor, Kailash Institute of Pharmacy and Management, GIDA, Gorakhpur, UP, India-273209

<sup>2</sup>Director, Kailash Institute of Pharmacy and Management, GIDA, Gorakhpur, UP, India-273209

<sup>3</sup>Assistant Professor, Buddha Institute of Pharmacy, GIDA, Gorakhpur, UP, India-273209

### Article History

Received: 16.07.2021

Accepted: 19.08.2021

Published: 16.09.2021

### Journal homepage:

<https://www.easpublisher.com>

### Quick Response Code



**Abstract:** Abscess is a localised collection of pus contained with a cavity and it is widely affected skin, anal area, tooth pulp etc. It cause swallowing, pain ,fever, the main cause of abscess is incision ,bacterial infection ,wounds and it can be diagnosed by CT scan, MRI, X-ray and radioisotopes scanning. It can be treated by using some antibiotic ,surgery but most promising treatment is homeopathic treatment because this treatment is fully cure the disease and it decreased chance of reoccurrence but it has contain a longer time.

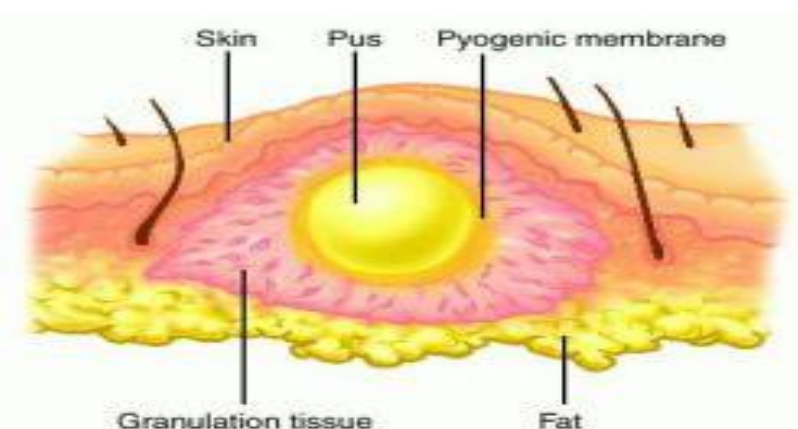
**Keywords:** Abscess, CT scan, MRI, X-ray and radioisotopes scanning.

**Copyright © 2021 The Author(s):** This is an open-access article distributed under the terms of the Creative Commons Attribution **4.0 International License (CC BY-NC 4.0)** which permits unrestricted use, distribution, and reproduction in any medium for non-commercial use provided the original author and source are credited.

## INTRODUCTION

An abscess is a collection of pus in any part of the body that, in most cases, causes swelling and inflammation around it. Abscesses are often easy to feel by touching [2]. The middle of an abscess is full of pus and debris. Painful and warm to touch, abscesses can

show up any place on your body [28, 29]. The most common sites are in your armpits (axillae), areas around your anus and vagina (Bartholin gland abscess), the base of your spine (pilonidal abscess), around a tooth (dental abscess) [3].



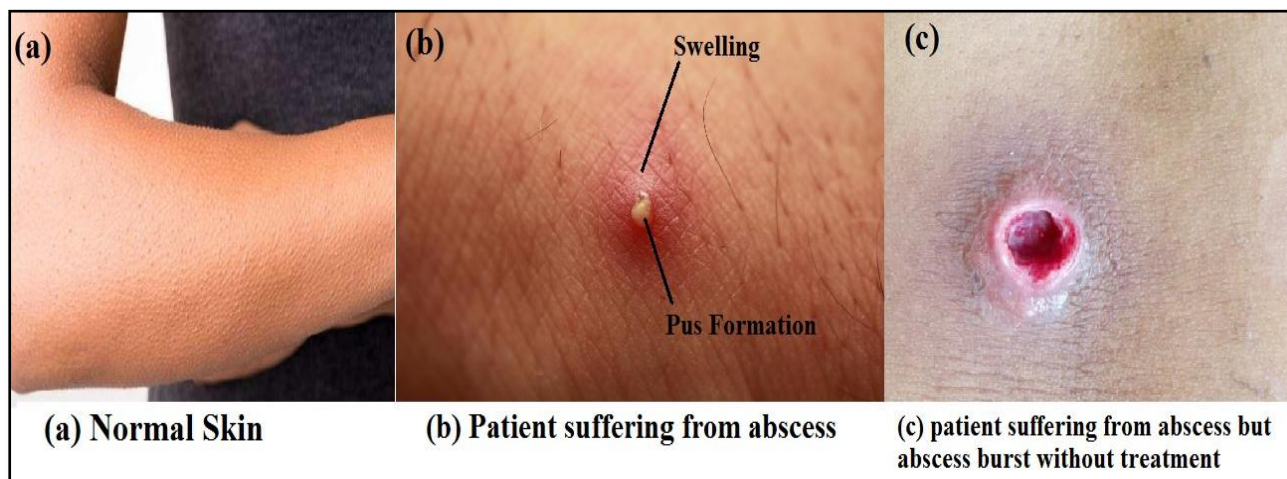
**Fig-1: An abscess**

An abscess is a tender, easily pressed mass generally surrounded by a colored area from pink to deep red. The middle of an abscess is full of pus and debris. Painful and warm to touch, abscesses can show up any place on your body. Liver abscesses are most

commonly due to pyogenic, amebic or mixed infections. Less commonly these may be fungal in origin [12]. Liver abscess has been recognized since Hippocrates [circa 400 B.C.] who speculated that the prognoses of the patients were related to the type of

fluid within the abscess cavity [13]. Liver abscess is a major tropical disease of the gastrointestinal system [14, 15]. The liver abscess is mainly classified into amebic and pyogenic. Pyogenic liver abscess which used to be mainly tropical in location is now more common due to increased biliary interventions, stenting, cholecystitis, cholangitis etc. Liver abscess is 3 to 10 times more common in men [16].

A brain abscess is a collection of pus, immune cells, and other material in the brain, usually from a bacterial or fungal infection. The germs that cause a brain abscess can reach the brain through the blood. The source of the infection is often not found. However, the most common source is a lung infection. Less often, a heart infection is the cause. Germs may also travel from a nearby infected area [for example, an ear infection or a tooth abscess] or enter the body during an injury [such as a gun or knife wound] or neurosurgery [17].



**Fig-2: (a) Normal skin; (b) Patient suffering from abscess; (c) Patient suffering from abscess but abscess burst without treatment**

Peritonsillar abscess (PTA), also known as a quinsy or quinsey, is a recognized complication of tonsillitis and consists of a collection of pus beside the tonsil in what is referred to as peritonsillar space [peri—meaning surrounding]. It is a commonly encountered otorhinolaryngological (ENT) emergency [18].

### Sign & Symptom

The main symptoms and signs of a skin abscess are redness, heat, swelling, tenderness, skin lesion that may be an open or closed sore [10], pain and loss of function. There may also be high temperature [fever] and chills [5].

If superficial, abscesses may be fluctuant when palpated. This is a wave-like motion which is caused by movement of the pus inside the abscess [4].

### Cause

Abscesses are caused by bacterial infection, parasites, or foreign substances. Bacterial infection is the most common cause [6]. Often many different types of bacteria are involved in a single infection [7]. In the United States and many other areas of the world the most common bacteria present is methicillin resistant *Staphylococcus aureus* [1]. Among spinal subdural abscesses, methicillin sensitive *Staphylococcus aureus* is the most common organism involved [8]. Rarely parasites can cause abscesses and this is more common

in the developing world. Specific parasites known to do this include: dracunculiasis and myiasis [9].

### Some other cause of Abscess

Indigestion Abscess is usually caused because of improper lifestyle and eating habits. Inadequate consumption of fresh food, lack of antioxidants in the body, lack of vitamin C, diet, Uncleanliness [11].

### Abscess can be formed in some area such as

#### Sites of abscess:

**a) External sites:** In external area some sites are mostly affected such as-

- Fingers and hand
- Neck
- Axilla
- Breast
- Foot
- Thigh
- Ischioanal and perianal region
- Abdominal wall
- Dental abscess, tonsillar abscess and other abscesses in the oral cavity

**b) Internal sites:** Internal area some sites are mostly affected such as-

- Abdominal, pelvic, paracolic, amoebic liver abscess, pyogenic abscess of liver, splenic abscess, pancreatic abscess.

- Perinephric abscess.
- Retroperitoneal abscess.
- Lung abscess.
- Brain abscess

### Pathophysiology

An abscess is a defensive reaction of the tissue to prevent the spread of infectious materials to other parts of the body. The organisms or foreign materials kill the local cells, resulting in the release of cytokines. The cytokines trigger an inflammatory response, which draws large numbers of white blood cells to the area and increases the regional blood flow.

The final structure of the abscess is an abscess wall, or capsule, that is formed by the adjacent healthy cells in an attempt to keep the pus from infecting neighboring structures. However, such encapsulation tends to prevent immune cells from attacking bacteria in the pus, or from reaching the causative organism or foreign object.

### Diagnosis

Abscesses must be differentiated from empyemas, which are accumulations of pus in a preexisting rather than a newly formed anatomical cavity. For those with a history of intravenous drug use, an X-ray is recommended before treatment to verify that no needle fragments are present [21]. In this population if there is also a fever present infectious endocarditis should be considered. Abdominal ultrasound- Reasonably reliable and safe test.

CT has proven reliable in helping to delineate fistulas and abscesses from isolated rectal inflammation [20]. It scan can be useful for patients with complex suppurative anorectal conditions, and is especially helpful in identifying supralelevator abscesses, or for those patients who would otherwise be difficult to examine without anesthesia [19].

Radioisotope scanning using white blood cells labelled with special radioactive substances that localise in the abscess. These are however very time consuming so will only be used if other investigations are negative

but it is still thought there is an abscess. Plain abdominal x-rays have little diagnostic value and often highlight the need for further investigation [26].

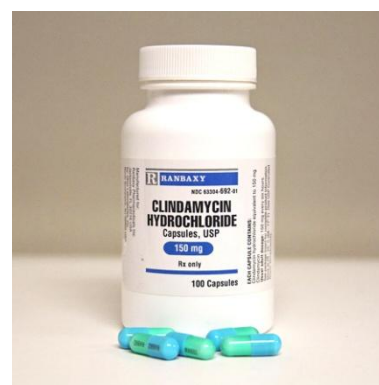
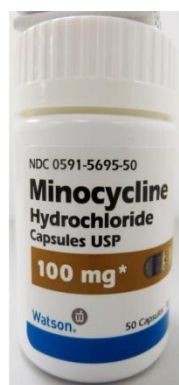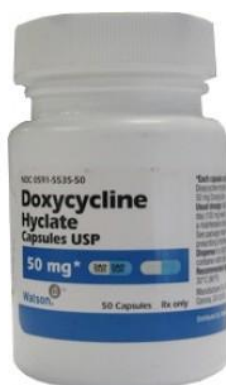An Abscess can easily be identified with swelling bumps on the skin with pain. It is usually accompanied with pain, there is a pus collection on the skin along with mild fever. Usually no medical tests are required as physical appearance confirms the condition.

### Allopathic Treatment of Abscess

The abscess should be inspected to identify if foreign objects are a cause, which may require their removal. If foreign objects are not the cause, a doctor will incise and drain the abscess and prescribe painkillers and possibly antibiotics. [22] In those cases of abscess which do require antibiotic treatment, Staphylococcus aureus bacteria are a common cause and an anti-staphylococcus antibiotic such as flucloxacillin or dicloxacillin is used. The Infectious Diseases Society of America advises that the draining of an abscess is not enough to address community-acquired methicillin-resistant Staphylococcus aureus [MRSA], and in those cases, traditional antibiotics may be ineffective. Alternative antibiotics effective against community-acquired MRSA often include clindamycin, doxycycline, minocycline, and trimethoprim-sulfamethoxazole [1]. The American College of Emergency Physicians advises that typical cases of abscess from MRSA get no benefit from having antibiotic treatment in addition to the standard treatment. If the condition is thought to be cellulitis rather than abscess, consideration should be given to possibility of strep species as cause that are still sensitive to traditional anti-staphylococcus agents such as dicloxacillin or cephalexin in patients able to tolerate penicillin [23].

Antibiotic therapy alone without surgical drainage of the abscess is seldom effective due to antibiotics often being unable to get into the abscess and their ineffectiveness at low pH levels. Surgical drainage of the abscess [e.g., lancing] is usually indicated once the abscess has developed from a harder serous inflammation to a softer pus stage.

### Some Marketed Product [Antibiotics] Used In Abscess





### Homeopathic Treatment

Homeopathic treatment of abscess can be a great boon to person suffering from it. Homeopathic medicines are very effective in treating skin abscess and boils. Once the abscess gets treated with homeopathic medicines, the chances of it recurring again are very less. Moreover, homeopathic medicines are very safe and natural medicines thus produce no side effects. Acute abscess of recent origin can respond to homeopathic medicines; however, it may take little longer than antibiotics. Homeopathy is best indicated in the cases of-

1. Frequent abscesses
2. Prolonged (chronic) abscess
3. Resistant abscess.

In the above three categories, the formation of an abscess is surely a sign of altered underlying immunity, which can be treated effectively using homeopathy. Homeopathy is strongly indicated for recurring and resistant cases of abscesses. Medicines used in abscess is given below-

#### Gun powder Belladonna

Is the remedy most often indicated for the initiatory symptoms of abscess. The parts swell rapidly, become bright red, there is intense throbbing which is painful, pus develops speedily the swelling increases and the redness radiates; here Belladonna is in close relation with Hepar and Mercurius. It comes in earlier than either of these remedies and corresponds more closely to the active, asthenic variety of abscess before pus is matured. In abscesses about the alveolar

processes, the so called gum boils, Belladonna is often the first remedy and Mercurius follows here in most cases. In acute glandular abscess Belladonna is often indicated and is a beginning remedy. Chamomilla is not a remedy to suggest itself in abscess, yet has proved valuable in promoting the formation of pus in chronic abscesses where Hepar has failed to act promptly, and in making the pains more bearable [27].

#### Hepar sulphur [Hep]

Is the great homoeopathic remedy for suppurations where the pus is not decomposed. It suits especially lymphatic, phlegmatic individuals. Excessive sensitiveness of the parts is a leading indication. It is further indicated by these symptoms: chilly sensations, throbbing in the parts, or sharp, sticking pains which are worse at night and from if given low in threatening suppuration it will favour the formation of pus.


#### Ayurvedic Treatment of an abscess

According to Ayurveda, in the very beginning stage of an abscess, always try to subside the swelling. Give hot fomentation to the patient around the area of an abscess. Do Ayurvedic bloodletting [Siravyadha Treatment] procedure near the affected area. Advise the patient to do fast for 24-48 hours or should give him light diet. One should apply the 'Ayurvedic herbal paste' having anti inflammatory properties on the affected area, e.g. Dashang lepa, Doshagna lepa, Triphala Kwath, Varunaadi Kwath, Punarnavaadi, Kwath, Shigru Kwath, Tab. Shilajit, Tab. Pathyadi ghanvati, etc. By using these above appropriate measure, if the swelling is not getting subsided and become larger and larger, then go for the next step, and

try to ripe the swelling fast. For achieving it, apply the 'Ayurvedic herbal paste' which can ripe, mild squeeze and burst the swelling, e.g. Lepa ghuti lepa, Apamarg kshara lepa, Yav kshara lepa etc. Incision and drainage of the abscess would be the last treatment choice. Incision and drainage [I & D]: It is done under local, spinal or general anaesthesia. A stab incision is made over the most prominent part of an abscess. The pus which

comes out is collected and sent for culture and sensitivity. A sinus forceps or a finger is introduced within the abscess cavity and all the loculi are broken down. Fresh bleeding is an indication of completeness of the procedure. The abscess cavity is irrigated with mild antiseptic agents like iodine solution or hydrogen peroxide solution [24].

#### Some Marketed Product Used In Ayurvedic Treatment of Abscess



#### Precaution

- Drink lots of water, let the body eliminate the toxins out of the body.
- Stay away from constipation, eat fresh fruits or go on a juice fasting couple of days in a week.
- Lose weight

#### Prognosis

Even without treatment they rarely result in death as they will naturally burst through the skin [27].

#### REFERENCE

1. Singer, A. J., & Talan, D. A. (2014). Management of skin abscesses in the era of methicillin-resistant *Staphylococcus aureus*. *New England Journal of Medicine*, 370(11), 1039-1047.
2. www.wikipedia.com
3. Hpathy Ezine, January, 2014
4. Churchill Livingstone medical dictionary. (16th ed.). Edinburgh: Churchill Livingstone. 2008. ISBN 9780080982458
5. United Kingdom National Health Service 'Abscess' [http://www.nhs.uk/Conditions/Abscess/Pages/Introduction.aspx]
6. Turkington, C., & Dover, J. S. (2009). *The encyclopedia of skin and skin disorders*. Infobase Publishing.
7. Elston, D. M. (2009). *Infectious Diseases of the Skin*. (http://books.google.ca/books?id=esPkuOxZajYC&pg=PA12). London: Manson Pub. p. 12.
8. Kraeutler, M. J., Bozzay, J. D., Walker, M. P., & John, K. (2015). Spinal subdural abscess following epidural steroid injection. *Journal of Neurosurgery: Spine*, 22(1), 90-93.
9. Marx, John, A. M. (2014). *Skin and Soft Tissue Infections*. Rosen's emergency medicine: concepts and clinical practice (8th ed. ed.). Philadelphia, PA: Elsevier/Saunders. pp. Chapter 137.
10. <http://www.nytimes.com/health/guides/disease/skin-abscess/overview.html>.
11. <http://www.treatmentguru.com/abscess>.
12. Singh, S., Chaudhary, P., Saxena, N., Khandelwal, S., Poddar, D. D., & Biswal, U. C. (2013). Treatment of liver abscess: prospective randomized comparison of catheter drainage and needle aspiration. *Annals of Gastroenterology: Quarterly Publication of the Hellenic Society of Gastroenterology*, 26(4), 332.
13. Adams, F. L. (1886). *The Genuine Works of Hippocrates vols. 1 and 2*. New York: WWood & Co.
14. Cook, G. C. (1991). Gastroenterological emergencies in the tropics. *Baillière's clinical gastroenterology*, 5(4), 861-886.
15. Reeder, M. M. (1975). Tropical diseases of the liver and bile ducts. *Semin Roentgenol*, 10, 229-243.
16. Sepulveda, B., & Manzo, N. T. G. (1986). Clinical manifestations and diagnosis of amebiasis. In: Martinez-Palomo A, ed. *Amebiasis: Human Parasitic Diseases*, No. 2, Amsterdam: Elsevier, 169-187.
17. Brain abscess: Medline Plus Medical Encyclopedia.
18. Raut, V. V. (2000). Management of peritonsillitis/peritonsillar. *Revue de laryngologie-otologie-rhinologie*, 121(2), 107-110.
19. Guillaumin, E., Jeffrey Jr, R. B., Shea, W. J., Asling, C. W., & Goldberg, H. I. (1986). Perirectal

- inflammatory disease: CT findings. *Radiology*, 161(1), 153-157.
20. Yousem, D. M., Fishman, E. K., & Jones, B. (1988). Crohn disease: perirectal and perianal findings at CT. *Radiology*, 167(2), 331-334.
  21. Khalil, P. N., Huber-Wagner, S., Altheim, S., Bürklein, D., Siebeck, M., Hallfeldt, K., ... & Kanz, G. G. (2008). Diagnostic and treatment options for skin and soft tissue abscesses in injecting drug users with consideration of the natural history and concomitant risk factors. *Eur J Med Res*, 13(9), 415-424.
  22. Green, J., & Wajed, S. (2000). *Surgery: facts and figures*. Cambridge University Press.
  23. American College of Emergency Physicians, "Five Things Physicians and Patients Should Question", Choosing Wisely: an initiative of the ABIM Foundation [American College of Emergency Physicians], retrieved January 24, 2014.
  24. Stay healthy with Ayurveda: Ayurvedic Treatment of an Abscess [http:// drchauhans. blogspot. in/2013/06/ayurvedic-treatment-of-abscess](http://drchauhans.blogspot.in/2013/06/ayurvedic-treatment-of-abscess).
  25. Marx, J. A. M. (2014). "Skin and Soft Tissue Infections". Rosen's emergency medicine: concepts and clinical practice (8th ed. ed.). Philadelphia, PA: Elsevier/Saunders.
  26. Steele, S. R., Kumar, R., Feingold, D. L., Rafferty, J. L., & Buie, W. D. (2011). Practice parameters for the management of perianal abscess and fistula-in-ano. *Diseases of the colon & rectum*, 54(12), 1465-1474.
  27. Home / Skin Problem / Homeopathic Treatment and Remedies for Skin Abscess and Boils.
  28. <http://www.webmd.com/a-to-z-guides/abscess>
  29. Bologna, J. (2011). Infections, hyper- and hypopigmentation, regional dermatology, and distinctive lesions in black skin. In: Goldman, L., & Schafer, A. I., eds. Cecil Medicine. 24th ed. Philadelphia, Pa: Saunders Elsevier; chap 449.

---

**Cite This Article:** Jyoti Nayak *et al* (2021). A Brief Study on Abscess: A Review. *EAS J Pharm Pharmacol*, 3(5), 138-143.