

Original Research Article

Anatomical Risk Factors of Anterior Cruciate Ligament Injury

Ameni Ammar^{1*}, Leila Jarray², Oussama Abcha³, Hamdi Grami⁴, Mahmoud Smida⁵, Mohamed Samir Daghfous⁶^{1,3}Traumatology Department, KASSAB Institute, Manouba, 2010, Tunisia²MT kassab institute, Mannouba Tunis 2010⁵Pediatric Orthopedic, KASSAB Institute, Manouba, 2010, Tunisia⁶Traumatology department, KASSAB Institute, Manouba, 2010, Tunisia

Article History

Received: 11.08.2021

Accepted: 18.09.2021

Published: 27.09.2021

Journal homepage:

<https://www.easpublisher.com>

Quick Response Code



Abstract: It has been suggested that an increased tibial slope and a narrow inter-condylar notch increase the risk of anterior cruciate ligament (ACL) injury. The aim of this study was to establish why there are conflicting reports on their significance. It was a retrospective and comparative case-control study out of 80 patients divided into two groups. Group 1 consisted of 40 patients with unilateral ACL rupture. Group 2 involved 40 control subjects. We measured the Tibial Slope on lateral knee X-ray by three methods. The geometry of the Inter-condylar Notch was evaluated by the notch width index, the notch shape index and the notch height index on Schuss radiography and on MRI. The Group 1 average Tibial Slope was above the Group 2 average regardless of the method of measurement, with a statistical difference significant ($P < 0.05$). Mean notch width index and mean notch shape index in-group 1 were lower than those in Group 2, with a statistically significant difference ($P < 0.05$). Ninety-five percent of our Group 1 had at least one of these two factors. Our study showed that a high Tibial Slope and narrow inter-condylar notch geometry were risk factors for ACL rupture. Sports medicine must screen for those factors, especially in pivot sports. The surgeon should take consideration of these factors both in the surgical technique and in the post-operative follow-up.

Keywords: Anatomical Risk tibial Ligament Injury.

Copyright © 2021 The Author(s): This is an open-access article distributed under the terms of the Creative Commons Attribution 4.0 International License (CC BY-NC 4.0) which permits unrestricted use, distribution, and reproduction in any medium for non-commercial use provided the original author and source are credited.

INTRODUCTION

The reconstruction of the anterior cruciate ligament (ACL) has evolved in recent years. However, we notice the frequency of iterative ruptures of the plasties and bilateral rupture of the ACL (2-9.5%). The risk factors for ACL rupture are multiple, some are extrinsic, and others are intrinsic. The objective of our study was to study the influence of the Tibial Slope (TS) and the geometry of the inter-condylar notch (ICN) on the risk of ACL rupture.

METHODS

This was a retrospective and comparative case-control study conducted on a two-year period, from January 2019 to December 2020. We conducted our study on 80 patients spread over two groups: group 1

involved 40 cases of rupture of the ACL and group 2 had 40 control subjects with healthy ACL.

We have specified for all patients of both groups the age, the sex, the affected side, the mechanism of the trauma and the level of sport activity.

On lateral knee x-ray (Figure 1), we determined three measures of the TS:

- Anterior cortical slope (ACS) using as reference axis the anterior tibial cortex below anterior tibial tuberosity.
- The Dejour and Bonin slope (DBS) using as a reference axis the proximal tibial anatomical axis of Dejour and Bonin modified [1, 2].
- Posterior cortical slope (PCS) using as reference axis the posterior tibial cortex under its proximal posterior concavity.

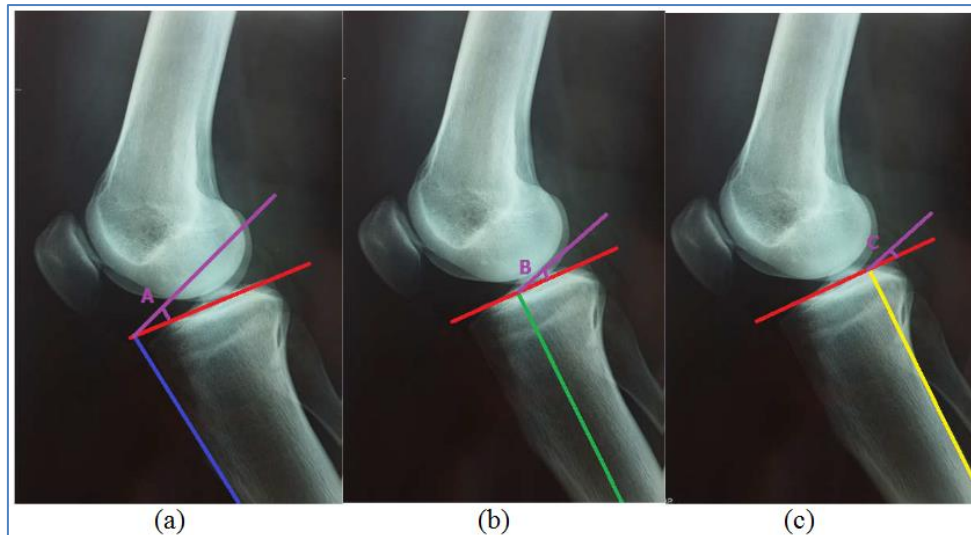


Fig-1: Tibial slope measurement techniques; a: Anterior cortical slope, b: The slope of Dejour and Bonin, c: Posterior cortical slope.

On Schuss and Coronal MR Slices through the popliteal dimple, we have made the following measurements: the width of the inter-condylar notch, the width of the femoral epiphysis, the height of the ICN and the height of the femoral epiphysis.

From these measurements, we calculated the following ratios

- The “notch width index” (NWI) that corresponds to the width ratio of the inter-condylar notch divided by the width of the femoral epiphysis.
- The “notch shape index” (NSI) that corresponds to the width ratio of the inter-condylar notch divided by the height of the inter-condylar notch.
- The Notch Height Index (NHI) that corresponds to the ratio of the height of cut divided by height of femoral epiphysis.

The data was analyzed using SPSS version 25.0 software. In all statistical tests, the significance threshold was set at 0.05 ($p=0.05$).

RESULTS

Our series included 80 patients: 75 men and 5 women. The average age was 30.95 years for group 1 and 34.9 years for group 2.

All Group 1 patients had ACL injury. Thirty percent were isolated. In 57.5%, there was an associated meniscal lesion and in 12.5% of cases, we noted chondropathies lesions. The Group 2 had intact ACL. Only 10% of patients had a healthy knee, 80% had a meniscal lesion and 10% had osteochondrosis.

The values of the TS varied depending on the benchmark used. The use of the anterior cortical as a landmark has made us observe the highest values of the TS, posterior cortical showed us the smallest values.

Comparative analysis between the TS of the group 1 and those in Group 2 (controls), showed an increase in the TS of the Group 1 statistically significant regardless of the method of measurement (Table 1).

Table-1: Comparative measurements of Tibial Slope in the two groups

Tibial slope	Group	Number	Average	Min	Max	Standard deviation	P
ACS	G1	40	15,67	11	20	2,690	0,038
	G2	40	14,56	8	20	3,316	
DBS	G1	40	11,92	7	18,5	2,349	0,013
	G2	40	10,27	2	16	3,392	
PCS	G1	40	8,60	4	14	1,918	0,024
	G2	40	7,53	2	14	2,977	

The values of the tibial slope varied according to the benchmark used. We found a highest tibial slope using the anterior cortex as a landmark, while use of the posterior cortex showed a smallest values (Figure 2).

Using the ACS, the difference between the means of the TS of both groups was 1.06 ° (Student's test, $p = 0.01 < 0.05$).

Using the DBS, the difference between the means of the TS of both groups was 1.65 ° (Student's test, $p = 0.013 < 0.05$).

Using the PCS, the difference between the means of the TS of both groups was 1.13 ° (Student's test, $p = 0.006 < 0.05$).

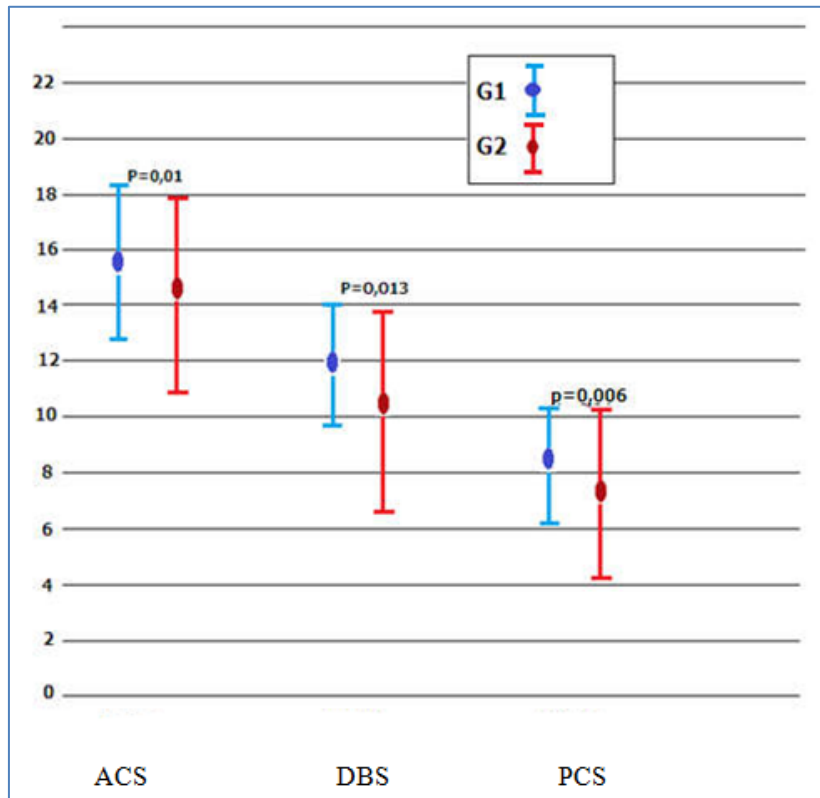


Fig-2: Comparison of the tibial slope measurements between the two groups according to measurement method

The comparative analysis of the parameters of the ICN geometry had shown that the average NWI of group 1 was less than the average NWI of group 2 and that the average NHI of group 1 was less than the average NHI of group 2. The differences were statistically significant.

The mean of the INS of group 1 was higher than the mean of group 2 NSI. The difference between the NSI of the two groups was not statistically significant (Table 2).

Table-2: Comparative analysis of the parameters of the inter-condylar notch geometry

ICN geometry	Group	Number	Average	Min	Max	Standard deviation	P
NWI(x-ray)	G1	40	0,22	0,16	0,32	0,390	0,002
	G2	40	0,24	0,17	0,29	0,240	
NWI(MRI)	G1	40	0,21	0,15	0,28	0,033	0,012
	G2	40	0,23	0,18	0,28	0,021	
NSI	G1	40	0,973	0,60	1,85	0,246	0,095
	G2	40	0,971	0,62	1,40	0,198	
NHI	G1	40	0,44	0,30	0,60	0,060	0,006
	G2	40	0,49	0,37	0,70	0,075	

Our analysis of the correlation between TS and ICN showed a statistically significant correlation only between the ACS and the values of the NHI. The correlation coefficient p was -0,225.

The correlation between P.C.A and IHE was weak ($P=0,044$) with a linear regression (Figure 3).

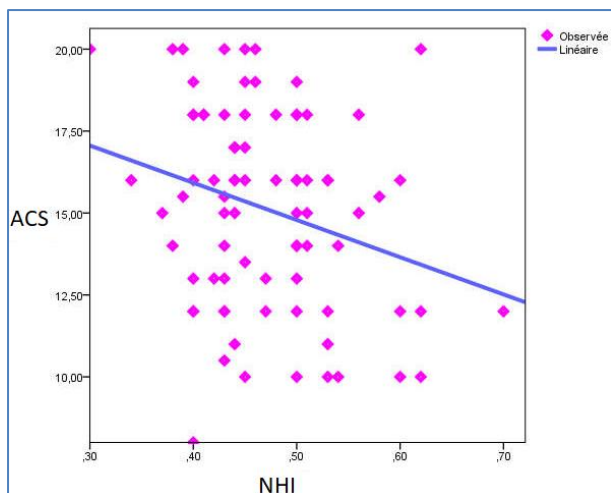


Fig-3: Linear regression between the ACS and the NHI

Ninety five percent of our patients with ACL rupture had at least one of these two factors. 47.5 % had one of these risk factors and 47.5% had both.

DISCUSSION

Our study showed that a high TS ($TS > 14^\circ$) and a narrow ICN ($NWI < 0.22$ and / or $NHI < 0.44$) are risk factors of ACL rupture.

The TS designates the tibial plateau in the sagittal plane. Although the measurement methods were different, most of the authors have concluded that increased TS predisposes to ACL rupture.

Titze [3] was the first to find a pathological relation between the TS and ACL rupture. Several authors have found that there is a significant correlation between ACL rupture and the increase in TS measured on the standard radiograph [1, 4-6].

Some authors have studied the slopes of the medial and lateral plateaus each separately on the MRI. Most studies have found that only the increase in the slope of the lateral tibial plateau is associated with an increased risk of ACL rupture [7-11]. Some have reported that the slope of the medial tibial plateau is also correlated [12-14]. However, some authors have shown that there is no relationship between ACL rupture and the increased TS on standard radiography and MRI [15, 16].

Palmer [17] was the first to mention in 1938 the existence of a pathological relationship between the ACL and the EIC. Since then, several authors have observed a correlation between a narrow notch and the risk of ACL rupture based on the NWI.

As the NWI does not give a complete idea of the geometry of the EIC, the studies have used other measurement parameters; the "Reverse Notch Width

Index" (RNWI), the "Notch Shape Index" (NSI), the Notch Height Index (NHI) and the "Notch Area Index" (NAI). They also identified angles to better understand this geometry: "Sagittal notch angle" (SNA) and "Transverse Notch Angle" (TNA). Other authors have carried out arthroscopic morphological studies of the ICN [18].

We think it's not a narrow ICN or a small ACL, it's rather a conflict between a container (ICN) and a content (ACL) that would be responsible for the rupture.

Although several authors have studied the TS and the ICN together, few studies have assessed the correlation between the two factors. Some authors [19] have observed a negative correlation between the PT and the NWI measured on the MRI sections. Thus, not taking in consideration of these two factors in the same study necessarily leads to a significant risk of selection bias. In our study, we found a negative correlation between NHI and ACS.

Although the TS and geometry of the ICN are the main factors in anatomical risk of ACL injury, other intrinsic factors seem to play a role. Among these factors we cite: a small ACL, a small tibial eminence, articular cartilage slope, meniscus geometry, increase of the Q-angle, condylar offset, genu recurvatum, mid-foot pronation, valgus of the hind-foot, femoral anteversion, age, obesity, tall stature, hyper-laxity, amateur level and family predisposition.

Women in pivot sports have a risk of ACL injury of four to seven times more than men at the same athletic level [20, 21]. Anatomical, neuromuscular, genetic and hormonal factors could be at the origin of this difference in sex ratio.

Taking into account the intrinsic risk factors, the prevention of the ACL rupture begins with identifying those at risk. We recommend for pivotal sports, a systematic radiological assessment of anatomical risk factors. This report includes a lateral knee x-ray to measure the TS and a Schuss view to assess the ICN. We recommend applying intensive programs to prevent ACL ruptures, especially in the context of high-level sport.

Several prevention programs have been published and evaluated: PEP, Frappier Acceleration Training Program, KIPP, The Walden's Program, HarmoKnee, FIFA11 and FIFA 11+. It is recommended to apply prevention programs both for the affected knee and for the contralateral knee since the risk of ACL rupture in the contralateral knee is double that in the ipsilateral knee [22].

As part of the consideration of the TS in the prevention of iterative rupture of the ACL transplant, it is recommended to associate a Tibial deflection osteotomy at ACL ligamentoplasty. Several authors in first-line ligamentoplasty [23, 24] and especially recovery [25, 27] proposed this attitude. Support as well as the resumption of sport should be postponed postoperatively in case of high PT.

As part of the consideration of the intercondylar notch in the prevention of iterative rupture of the ACL transplant, some authors have recommended the notchplasty during the ligamentoplasty in case of a Narrow EIC [28, 29].

For some authors, the notchplasty should be systematic [27,30] and for others the double-bundle ligamentoplasty is not recommended in case of a narrow ICN [31]. The threshold, from which we are talking about a pathological EIC, must be adapted to the population studied because the studies have clearly shown a variation in measurements between different ethnicities [32]. We also recommend studying more than one parameter to be able to identify a narrow EIC.

CONCLUSION

Our study showed that a high PT (PT > 14 °) and a narrow ICN (NWI < 0.22) were risk factors for ACL rupture. Sports medicine must detect these two factors in competitive athletes, especially in pivot sports. The surgeon must take these factors into consideration as in the surgical technique than in the postoperative follow-up, in order to limit the risks of iterative rupture and prevent the risk of contralateral ligament injury.

Competing interests

The authors declare no competing interests.

Authors' contributions

Ameni Ammar and Oussama Abcha have participated in all phases of this study during proposal preparation, data collection, data analysis and manuscript writing. Hamdi Grami and Amal Abayed have participated in the manuscript writing. Mahmoud Smida and Mohamed Samir Daghfous contributed in the manuscript revision. All the authors read and approved the final version of the manuscript.

REFERENCES

1. Dejour, H, Bonnin, M. (1994). Tibial translation after anterior cruciate ligament rupture. Two radiological tests compared. *J Bone Jt Surg Br*, 76(5), 745-749.
2. Jaafar A, Dadjo A, Riahi N, Bouselmame N. (2010). Pente tibiale et rupture du ligament croisé antérieur : étude anatomo-radiologique. *J Traumatol Sports*, 2(27), 58-61.
3. Titze, A. (1951). Die variationen der neigung der schienbeinkopf gelenkfläche. *Z Orthop Chir*, 1(1), 436-444.
4. Lipps, D. B., Wilson, A. M., Ashton-Miller, J. A., & Wojtys, E. M. (2012). Evaluation of different methods for measuring lateral tibial slope using magnetic resonance imaging. *The American journal of sports medicine*, 40(12), 2731-2736.
5. Brandon, M. L., Haynes, P. T., Bonamo, J. R., Flynn, M. I., Barrett, G. R., & Sherman, M. F. (2006). The association between posterior-inferior tibial slope and anterior cruciate ligament insufficiency. *Arthroscopy: The Journal of Arthroscopic & Related Surgery*, 22(8), 894-899.
6. Voos, J. E., Suero, E. M., Citak, M., Petrigliano, F. P., Bosscher, M. R., Citak, M., ... & Pearle, A. D. (2012). Effect of tibial slope on the stability of the anterior cruciate ligament-deficient knee. *Knee Surgery, Sports Traumatology, Arthroscopy*, 20(8), 1626-1631.
7. Stijak, L., Herzog, R. F., & Schai, P. (2008). Is there an influence of the tibial slope of the lateral condyle on the ACL lesion?. *Knee surgery, sports traumatology, arthroscopy*, 16(2), 112-117.
8. McLean, S. G., Lucey, S. M., Rohrer, S., & Brandon, C. (2010). Knee joint anatomy predicts high-risk in vivo dynamic landing knee biomechanics. *Clinical biomechanics*, 25(8), 781-788.
9. Hashemi, J., Chandrashekar, N., Mansouri, H., Gill, B., Slauterbeck, J. R., Schutt Jr, R. C., ... & Beynon, B. D. (2010). Shallow medial tibial plateau and steep medial and lateral tibial slopes: new risk factors for anterior cruciate ligament injuries. *The American journal of sports medicine*, 38(1), 54-62.
10. Khan, M. S., Seon, J. K., & Song, E. K. (2011). Risk factors for anterior cruciate ligament injury: assessment of tibial plateau anatomic variables on conventional MRI using a new combined method. *International orthopaedics*, 35(8), 1251-1256.
11. Simon, R. A., Everhart, J. S., Nagaraja, H. N., & Chaudhari, A. M. (2010). A case-control study of anterior cruciate ligament volume, tibial plateau slopes and intercondylar notch dimensions in ACL-injured knees. *Journal of biomechanics*, 43(9), 1702-1707.
12. Vyas, S., Van Eck, C. F., Vyas, N., Fu, F. H., & Otsuka, N. Y. (2011). Increased medial tibial slope in teenage pediatric population with open physes and anterior cruciate ligament injuries. *Knee Surgery, Sports Traumatology, Arthroscopy*, 19(3), 372-377.
13. Terauchi, M., Hatayama, K., Yanagisawa, S., Saito, K., & Takagishi, K. (2011). Sagittal alignment of the knee and its relationship to noncontact anterior cruciate ligament injuries. *The American journal of sports medicine*, 39(5), 1090-1094.

14. Ristić, V., Janović, M. M., Peričin, B., Harhaji, V., & Milankov, M. Z. (2014). The relationship between posterior tibial slope and anterior cruciate ligament injury. *Medicinski preglod*, 67(7-8), 216-221.
15. Meister, K., Talley, M. C., Horodyski, M. B., Indelicato, P. A., Hartzel, J. S., & Batts, J. (1998). Caudal slope of the tibia and its relationship to noncontact injuries to the ACL. *The American journal of knee surgery*, 11(4), 217-219.
16. van Diek, F. M., Wolf, M. R., Murawski, C. D., van Eck, C. F., & Fu, F. H. (2014). Knee morphology and risk factors for developing an anterior cruciate ligament rupture: an MRI comparison between ACL-ruptured and non-injured knees. *Knee Surgery, Sports Traumatology, Arthroscopy*, 22(5), 987-994.
17. Palmer, I. (1938). On the injuries to the ligaments of the knee joint. A clinical study. *Acta Chir Scand.*, 4(53), 17-22.
18. Zeng, C., Gao, S. G., Wei, J., Yang, T. B., Cheng, L., Luo, W., ... & Lei, G. H. (2013). The influence of the intercondylar notch dimensions on injury of the anterior cruciate ligament: a meta-analysis. *Knee Surgery, Sports Traumatology, Arthroscopy*, 21(4), 804-815.
19. Sonnery-Cottet, B., Archbold, P., Cucurulo, T., Fayard, J. M., Bortolotto, J., Thaunat, M., ... & Chambat, P. (2014). Influence de la pente tibiale et de la taille de l'échancrure intercondylienne dans la rupture du ligament croisé antérieur. *Journal de Traumatologie du Sport*, 31(1), 54-57.
20. Lefevre, N., Bohu, Y., Cascua, S., & Herman, S. (2011). Revue de littérature: la rupture du ligament croisé antérieur: particularités féminines. *Journal de traumatologie du sport*, 28(1), 24-30.
21. Smith, H. C., Vacek, P., Johnson, R. J., Slauterbeck, J. R., Hashemi, J., Shultz, S., & Beynon, B. D. (2012). Risk factors for anterior cruciate ligament injury: a review of the literature—part 1: neuromuscular and anatomic risk. *Sports health*, 4(1), 69-78.
22. Wright, R. W., Magnussen, R. A., Dunn, W. R., & Spindler, K. P. (2011). Ipsilateral graft and contralateral ACL rupture at five years or more following ACL reconstruction: a systematic review. *The Journal of Bone and Joint Surgery. American volume.*, 93(12), 1159.
23. Trojani, C., Elhor, H., Carles, M., & Boileau, P. (2014). La reconstruction du ligament croisé antérieur associée à une ostéotomie tibiale de valgisation permet la reprise du sport. *Revue de Chirurgie Orthopédique et Traumatologique*, 100(2), 166-170.
24. Li, Y., Zhang, H., Zhang, J., Li, X., Song, G., & Feng, H. (2015). Clinical outcome of simultaneous high tibial osteotomy and anterior cruciate ligament reconstruction for medial compartment osteoarthritis in young patients with anterior cruciate ligament-deficient knees: a systematic review. *Arthroscopy: The Journal of Arthroscopic & Related Surgery*, 31(3), 507-519.
25. Dejour, D., Saffarini, M., Demey, G., & Baverel, L. (2015). Tibial slope correction combined with second revision ACL produces good knee stability and prevents graft rupture. *Knee Surgery, Sports Traumatology, Arthroscopy*, 23(10), 2846-2852.
26. Gifstad, T., Drogset, J. O., Viset, A., Grøntvedt, T., & Hortemo, G. S. (2013). Inferior results after revision ACL reconstructions: a comparison with primary ACL reconstructions. *Knee Surgery, Sports Traumatology, Arthroscopy*, 21(9), 2011-2018.
27. Schuster, P., Schulz, M., & Richter, J. (2016). Combined biplanar high tibial osteotomy, anterior cruciate ligament reconstruction, and abrasion/microfracture in severe medial osteoarthritis of unstable varus knees. *Arthroscopy: The Journal of Arthroscopic & Related Surgery*, 32(2), 283-292.
28. Lund-Hanssen, H., Gannon, J., Engebretsen, L., Holen, K. J., Anda, S., & Vatten, L. (1994). Intercondylar notch width and the risk for anterior cruciate ligament rupture: a case-control study in 46 female handball players. *Acta Orthopaedica Scandinavica*, 65(5), 529-532.
29. LaPrade, R. F., & Burnett, Q. M. (1994). Femoral intercondylar notch stenosis and correlation to anterior cruciate ligament injuries: a prospective study. *The American Journal of Sports Medicine*, 22(2), 198-203.
30. Tanzer, M., & Lenczner, E. (1990). The relationship of intercondylar notch size and content to notchplasty requirement in anterior cruciate ligament surgery. *Arthroscopy: The Journal of Arthroscopic & Related Surgery*, 6(2), 89-93.
31. Van Eck, C. F., Martins, C. A., Vyas, S. M., Celentano, U., van Dijk, C. N., & Fu, F. H. (2010). Femoral intercondylar notch shape and dimensions in ACL-injured patients. *Knee Surgery, Sports Traumatology, Arthroscopy*, 18(9), 1257-1262.
32. Shelbourne, K. D., Gray, T., & Benner, R. W. (2007). Intercondylar notch width measurement differences between African American and white men and women with intact anterior cruciate ligament knees. *The American journal of sports medicine*, 35(8), 1304-1307.

Citation: Ameni Ammar *et al* (2021). Anatomical Risk Factors of Anterior Cruciate Ligament Injury. *EAS J Orthop Physiother*, 3(5): 87-92.