

Case Report

Atypical Radiological Presentation of Intracranial Intra-Axial Fungal Infection: A Case Report

Muhammad Omer Altaf^{*1}, Nosheen Kanwal², Omna Younas², Palwasha Gul³, Saad Khalil⁴ & Muhammad Atif Naveed⁵¹Shaukat Khanum Cancer Hospital and research center**Article History**

Received: 26.02.2020

Accepted: 25.03.2020

Published: 30.03.2020

Journal homepage:<https://www.easpublisher.com/easjrjt>**Quick Response Code**

Abstract: CNS infections represent a wide spectrum of diseases, out of which fungal infections make a fare subset. In the last two decades, more frequent use of immunosuppressive therapies especially in patients with autoimmune diseases along with usage of chemotherapeutic agents in oncological patients has led to increase in the incidence of fungal infections. Occasionally the radiological manifestations overlap with that of primary brain glial cell tumors as seen in our case. A 20 years old female presented to a tertiary care cancer hospital with complaints of headache and vomiting for last two months. On imaging there was heterogeneously enhancing left frontal parasagittal mass involving genu of corpus callosum with surrounding vasogenic edema. There was adjacent meningeal enhancement also seen. It was favored to be a high grade glioma; however differentials of Cerebritis and focal infective lesion were also considered. MR Spectroscopy was interpreted as of intra-axial high-grade glial cell tumor. Burr hole biopsy samples were sent for histopathology revealed multiple scattered granulomas containing few giant cells representing fungal infection. Fungal infections usually manifests as intracranial extra axial lesions with heterogeneous or peripheral enhancement. The imaging findings overlap with that of high-grade gliomas and can be misinterpreted as in this case. Thus, it is important to have a good understanding of the radiological presentation as well as have a known how of the clinical presentations to reach to a better diagnosis.

Keywords: Intra cranial, fungal infections, glioma mimics.

Copyright © 2020 The Author(s): This is an open-access article distributed under the terms of the Creative Commons Attribution **4.0 International License (CC BY-NC 4.0)** which permits unrestricted use, distribution, and reproduction in any medium for non-commercial use provided the original author and source are credited.

INTRODUCTION:

Neural axis infectious diseases range from self-limiting to progressive in nature which can lead to further life-threatening conditions (Sharma, R. R. 2010). CNS infections represent a wide spectrum of diseases, out of which fungal infections make a substantial amount. Approximately 200 species out of total of 50000 in the kingdom fungi cause infection in human (Orlowski, H. L. *et al.*, 2017). These are further categorized on the basis of the morphological appearances (Kayser, F.H. (005). Most of the mycosis affect in immunocompromised states, while very few of the fungal infections seen in immunocompetent patients. Most of the times this CNS infection is owing to direct spread or haematogenous spread from other infected organs in the body most commonly the lungs. The Angioinvasive intracranial mycoses is most commonly caused by *Aspergillus* species out of these *aspergillus fumigatus* is most common (Starkey, J. *et al.*, 2004) this can present as meningitis, cerebral abscess formation or granulomas (Murthy, J.M., & Sundaram, C. 2014). Invasive aspergillosis is characterized by tissue invasion with *aspergillus hyphae* and, unlike the non-invasive forms, it has a high

morbidity and mortality (Batsakis, I.G., & Sciubb, J.J. 1991). We present a case of intracranial fungal infection involving the left frontal lobe which was this interpreted as high grade glioma on both MRI imaging and MR spectroscopy. This is to aware the radiologists about the atypical presentation of fungal infections, thus not to have a false diagnosis and to help in better patient management.

CASE DESCRIPTION:

A 20 Years old female presented at Shaukat Khanum Cancer Hospital Pakistan with complaints of headache and vomiting since 2 months. She had no previous history of trauma. No family history of cancer or any comorbidities. She had no relevant past treatment history or any related interventional history in particular to the head and neck. Her physical examination was unremarkable with GCS of 15 /15. CT brain without IV contrast showed a heterogeneous left frontal parasagittal infiltrative lesion involving the genu of corpus callosum. Moderate peripheral vasogenic edema noted. High-density secretions noted within the left maxillary sinus. Left-sided concha bullosa with internal high-density area (99HU) reported as chronic

inspissated secretions/ calcifications. On imaging, the possibility of fungal infection of paranasal sinuses was kept low. Subsequently MRI brain with IV contrast showed a large infiltrating left frontal lobe abnormality extending corpus callosum. There was also seen central heterogeneous contrast enhancement with punctate configuration. Mild mass effect with expansion of the gyri was also noted. Owing to its post contrast enhancement it was favored on imaging to be of high grade nature of glioma; however differentials of cerebritis and focal infective lesion was also considered. Meningeal enhancement was also seen which was favouring infection. MRI spectroscopy was performed for further evaluation. On MR spectroscopy there is

significantly elevated choline peak within the tumor with decreased NAA with elevated Cho/NAA ratio, while the single voxel in contralateral deep white matter demonstrated normal spectrum. No lipid lactate peak was observed. Keeping MR spectro findings the lesion was labeled as an intra-axial high grade glial cell tumor. Burr hole biopsy was performed. The histopathology of the specimen revealed reactive gliosis and inflammatory cells along with granulomatous inflammation secondary to fungal infection (a few septate fungal hyphae were seen). The serum Beta D glucan was also high with a range of 166.177 pg/ml. The patient was treated with antifungal therapy and is planned to have a followup with clinical and radiological teams.

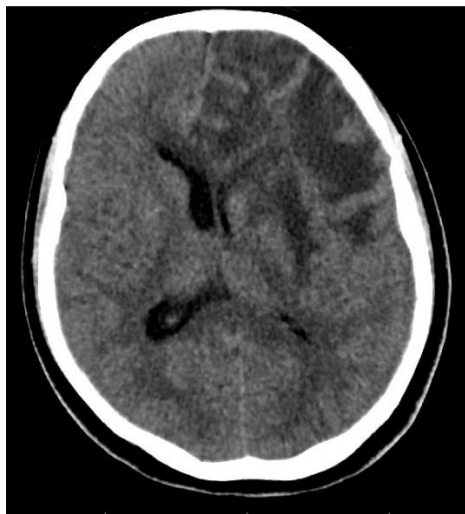

Figure of 1 A

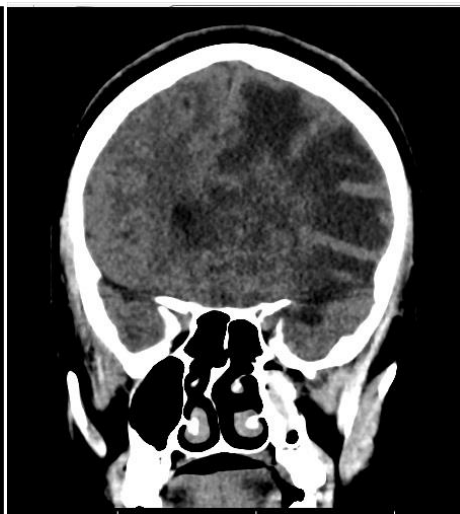

figure 1B

(Figure 1 A and B) show Unenhanced acquisition on CT brain with axial (left) and coronal (right) slices showing a diffusely infiltrative mass-like configuration involving the left frontal lobe with

associated surrounding representing oedema and expansion of the brain parenchyma. It is also showing mass effect with effacement of the frontal horn of the left lateral ventricle.

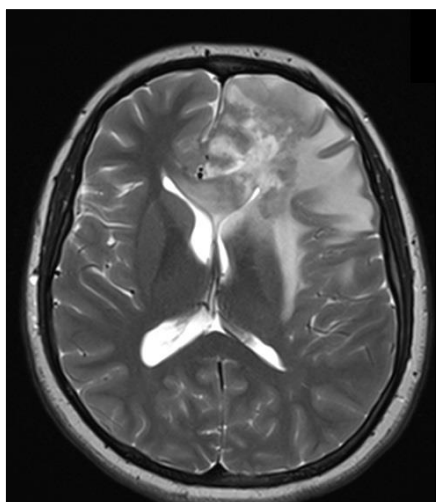


Figure 2A

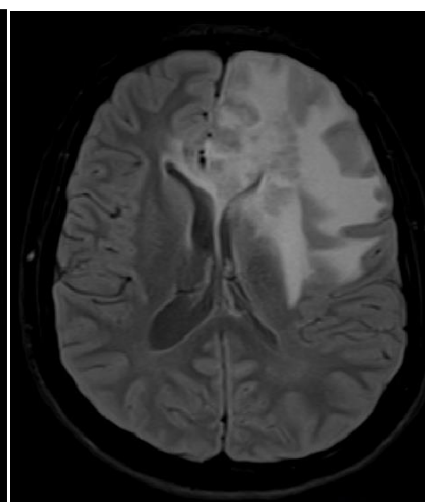


figure 2B

Figure 2A and 2B show axial sections of MRI scan T2 sequence (on left) and FLAIR sequence (on right) showing an infiltrative lesion involving

predominantly the white matter of the left frontal lobe with extension into the corpus callosum anteriorly heterogeneous signal intensity changes with associated

effacement of the frontal horn of the left lateral

ventricle is again appreciated.

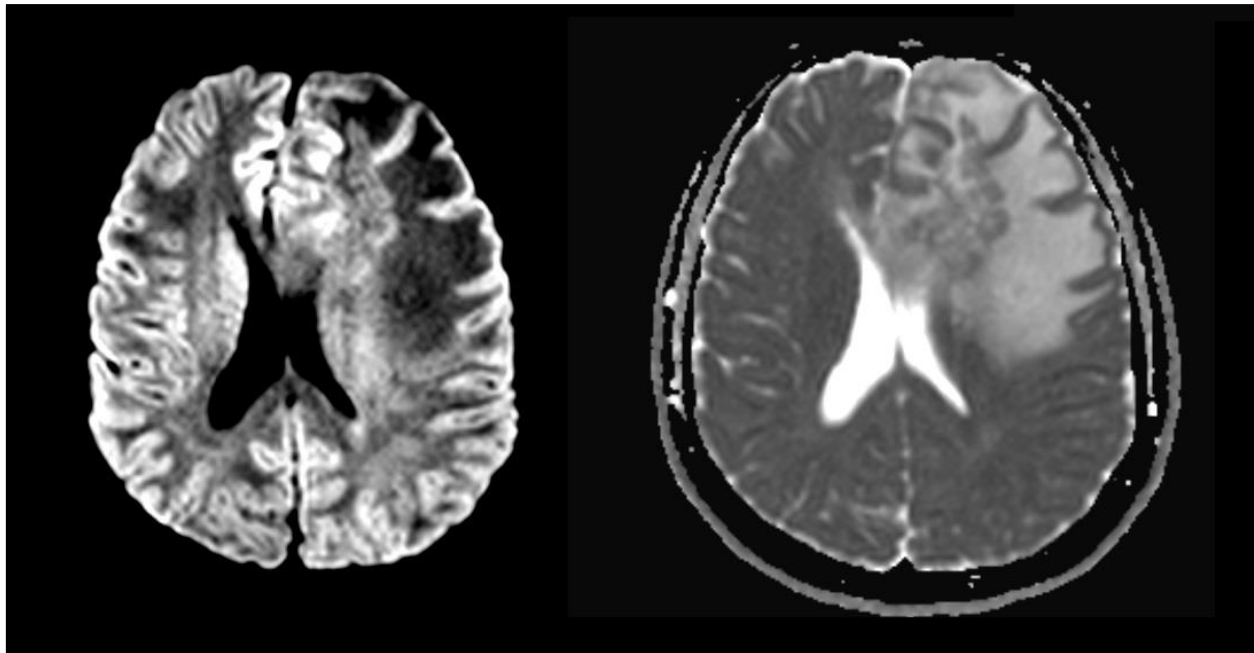


Figure 3

Figure 3 shows diffusion-weighted imaging on the left with ADC sequence on the right showing mildly restricted diffusion in the paraventricular region with associated representing oedema and gyral expansion.

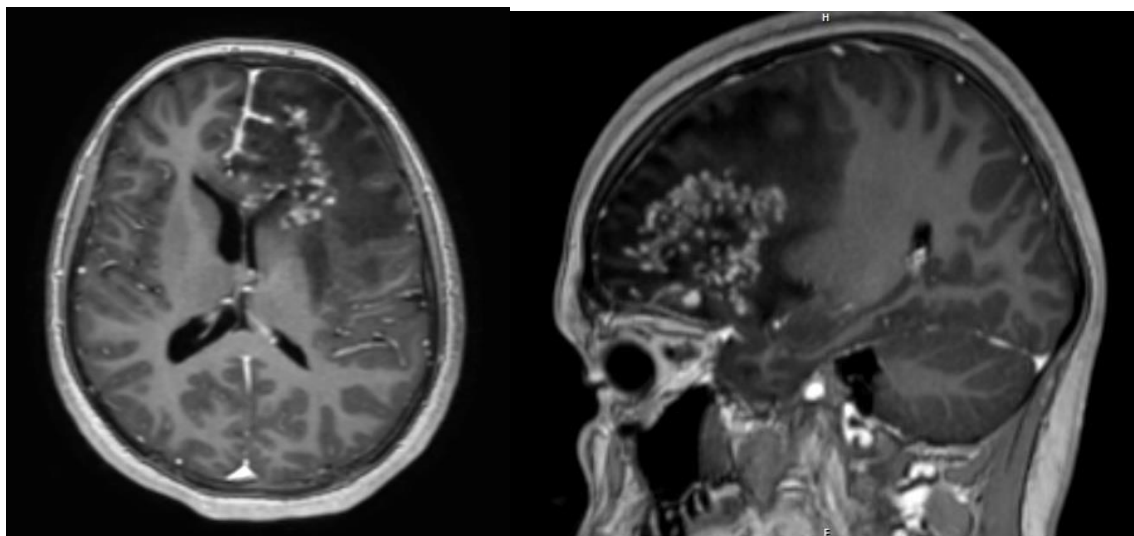


Figure 4 A and 4B

Figure 4 A and 4B shows axial slice on left and sagittal slice on right through the MRI scan in post-IV contrast T1 sequence showing heterogeneous mixed punctate enhancing foci in the region of the previously noted diffusion restriction. Note the pattern of enhancement is central which is different from that of the primary high grade glioma which show peripheral

nodular enhancement. Also associated meningeal enhancement is usually seen in infective disease process rather than primary glial tumours. No definite extensive metastatic oedema is seen in the vicinity without any enhancement. Marked meningeal enhancement is noted along the sagittal and parasagittal location anteriorly.

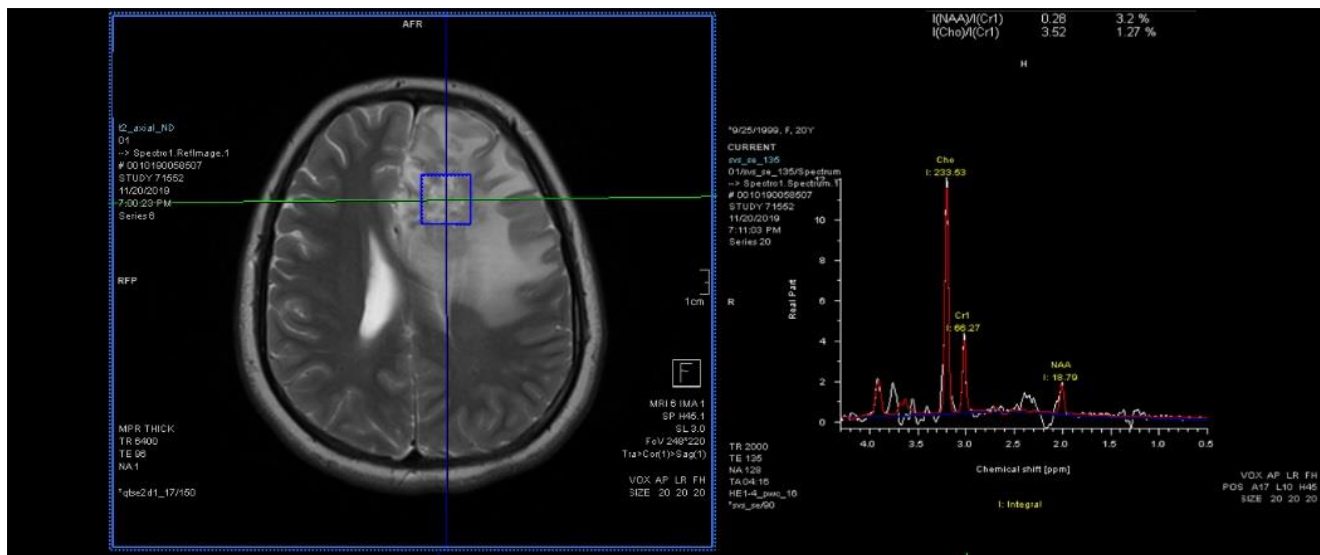


Figure 5

The figure 5 shows spectroscopy assessment on the site of abnormality in the left frontal lobe air scan clearly depicted on the graph seen on the right, with elevated choline peak and reduced NAA peak, thus, mimicking the primary glioma.

DISCUSSION:

Intracranial fungal infections have higher mortality rate reaching up to 63% (Chakrabarti, A. 2007). CNS mycoses most commonly results from hematological spread from other organs mostly from pulmonary fungal infections. The most common fungus is *Aspergillus* spp. to cause intracranial infections (Tempkin, A. D. *et al.*, 2006) CT findings can be often non-specific; usually these are associated with minimal inflammatory reaction. Calcification and necrosis are also seen (Jain, K. K. *et al.*, 2007). Fungal granulomas are not commonly found in immunocompetent or diabetic patients (Tintelnot, K., & Haase, G. 2013). MRI shows hypo to isointense mass within the white matter, with central heterogeneous signal on T1 weighted images. Typical peripheral or central post contrast enhancement can also be seen. Primary gliomas can also show peripheral enhancement which is usually nodular in morphology. DWI restriction is not widely associated with primary gliomas (Upadhyay, N., & Waldman, A. 2011). A broad spectrum of non-neoplastic conditions can mimic a brain tumor including infections, demyelination, vascular diseases and infectious / inflammatory disorders. Non-enhancing diffusely infiltrative lesions include low grade gliomas or cerebritis (Horská, A., & Barker, P. B. 2010). In our study we have noted that the pattern of enhancement is central which is different from that of the primary high grade gliomas, which show peripheral nodular enhancement. Also associated meningeal enhancement is usually seen in infective disease process rather than primary glial tumours. Parth A *et al.*, discussed the MRI spectroscopy findings to be overlapped with the of the primary glioma with high choline as seen in our case the spectroscopy showed increased choline to

creatinine ratio. The decreased NAA peak, and increased lactate peak which are the features of high grade glioma is also noted, thus was misinterpreted as high grade glioma (Luthra, G. *et al.*, 2007). By having keen radiological knowledge of various atypical presentations of fungal infections, these can be further differentiated from non-fungal aetiologies using a combination of the conventional imaging, DWI, and PMRS features (Pickering, J. W. *et al.*, 2005). The Fungitell assay is also used and is indicative for presumptive diagnosis of fungal infection. It should be used in conjunction with other diagnostic procedures. The Fungitell assay does not detect certain fungal species such as the genus *Cryptococcus*, which produces very low levels of (1-3) Beta D Glucan (Khandelwal, N. *et al.*, 2011). Quick detection of intracranial infections especially fungal infections can have a significant effect on patient outcomes with regard to morbidity and mortality. Furthermore this leads to better management of complications if present any. A combined approach of imaging, clinical settings, microbiology and histopathology with cerebrospinal fluid (CSF) assessment should be done.

CONCLUSION:

We present an atypical presentation of intracranial fungal infection, where the neuroimaging features were misinterpreted as for a high grade glial cell tumor due to overlapping features. But on histopathological analysis, findings were suggestive of a fungal infection. The purpose of this case report is to aware the radiologists regarding the non-neoplastic etiologies which comes in the differential diagnosis of primary high grade glial tumors. To a greater extent a

combination of clinical, pathological and imaging correlation should be done for better diagnosis.

REFERENCE:

1. Batsakis, I.G., & Sciubb, J.J. (1991). Fungal diseases. In: Blitzer A, Lawson W, Friedman WH (eds) *Surgery of the paranasal sinuses*. Saunders, Philadelphia, pp 122-123
2. Chakrabarti, A. (2007). Epidemiology of central nervous system mycoses. *Neurology India*, 55(3), 191-197.
3. Horská, A., & Barker, P. B. (2010). Imaging of brain tumors: MR spectroscopy and metabolic imaging. *Neuroimaging Clinics*, 20(3), 293-310.
4. Jain, K. K., Mittal, S. K., Kumar, S., & Gupta, R. K. (2007). Imaging features of central nervous system fungal infections. *Neurology India*, 55(3), 241-250.
5. Kayser, F.H. (2005). General mycology and fungi as human pathogens. In: Kayser FH, Bienz KA, Eckert J, Zinkernagel RM, eds. *Medical microbiology*. Stuttgart, Germany: Georg Thieme Verlag, 348–374.
6. Khandelwal, N., Gupta, V., & Singh, P. (2011). Central nervous system fungal infections in tropics. *Neuroimaging Clinics*, 21(4), 859-866.
7. Luthra, G., Parihar, A., Nath, K., Jaiswal, S., Prasad, K. N., Husain, N., ... & Gupta, R. K. (2007). Comparative evaluation of fungal, tubercular, and pyogenic brain abscesses with conventional and diffusion MR imaging and proton MR spectroscopy. *American Journal of Neuroradiology*, 28(7), 1332-1338.
8. Murthy, J.M., & Sundaram, C. (2014). Fungal infections of the central nervous system. *Handb Clin Neurol* 121, 1383–1401
9. Orłowski, H. L., McWilliams, S., Mellnick, V. M., Bhalla, S., Lubner, M. G., Pickhardt, P. J., & Menias, C. O. (2017). Imaging spectrum of invasive fungal and fungal-like infections. *Radiographics*, 37(4), 1119-1134.
10. Pickering, J. W., Sant, H. W., Bowles, C. A., Roberts, W. L., & Woods, G. L. (2005). Evaluation of a (1→3)-β-D-glucan assay for diagnosis of invasive fungal infections. *Journal of clinical microbiology*, 43(12), 5957-5962.
11. Sharma, R. R. (2010). Fungal infections of the nervous system: current perspective and controversies in management. *International journal of surgery*, 8(8), 591-601.
12. Starkey, J., Moritani, T., & Kirby, P. (2014). MRI of CNS fungal infections: review of aspergillosis to histoplasmosis and everything in between. *Clinical neuroradiology*, 24(3), 217-230.
13. Tempkin, A. D., Sobonya, R. E., Seeger, J. F., & Oh, E. S. (2006). Cerebral aspergillosis: radiologic and pathologic findings. *Radiographics*, 26(4), 1239-1242.
14. Tintelnot, K., & Haase, G. (2013). Fungal infections of the central nervous system in the immunocompetent host. *Der Pathologe*, 34(6), 534-539.
15. Upadhyay, N., & Waldman, A. (2011). Conventional MRI evaluation of gliomas. *The British journal of radiology*, 84(special_issue_2), S107-S111.