

Case Report

“A Case Report of Para-Spinal Hydatid Disease”

Dr. K. Subrahmany Eswar^{1*}, Dr. Saikumar Reddy², Dr. Prabhakaran M³

^{1,2}Post Graduate Resident, ³Head of Department, Department of Radio-diagnosis Sree Balaji Medical College and Hospital 7 Works Road, Chromepet Chennai, Tamilnadu India

Article History

Received: 04.09.2021

Accepted: 11.10.2021

Published: 13.10.2021

Journal homepage:

<https://www.easpublisher.com>

Quick Response Code



Abstract: Hydatid disease is a parasitic tapeworm infection. It usually occurs in liver and lungs. Involvement of hydatid cyst in para-spinal muscles is very rare. En bloc resection without inducing rupture and spreading the daughter cyst is recommended treatment strategy and accepted to be curative for intramuscular hydatid cyst. The authors here report a rare case of para-spinal hydatid disease CT scan of dorsolumbar showed a lesion comprised of multiple septated cysts involving the bilateral paraspinous region and MRI showed multilobulated multiseptated lesion involving bilateral paraspinous soft tissues.

Keywords: Hydatid cyst, paraspinous, computed tomography, magnetic resonance imaging.

Copyright © 2021 The Author(s): This is an open-access article distributed under the terms of the Creative Commons Attribution **4.0 International License (CC BY-NC 4.0)** which permits unrestricted use, distribution, and reproduction in any medium for non-commercial use provided the original author and source are credited.

INTRODUCTION

Hydatid disease is a parasitic tapeworm infection. It usually occurs in liver and lungs. Involvement of hydatid cyst in para-spinal muscles is very rare. En bloc resection without inducing rupture and spreading the daughter cyst is recommended treatment for intramuscular hydatid cyst. Clinically it manifests as pressure effects, obstruction, and allergic response to cystic fluid. Parasite penetrates the intestinal muscle and enters into the inferior vena cava system through small venous connections between this system and portal circulation. Then it reaches retroperitoneum, spinal and paraspinous structures via lumbar epidural venous plexuses [4]. Currently treatment choice of muscular hydatid cyst is the combination of en bloc resection and albendazole chemotherapy. Puncture, aspiration, injection and re-aspiration (PAIR) is a non-operative technique which is

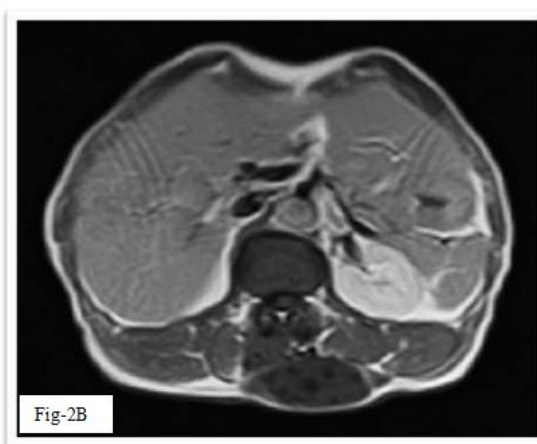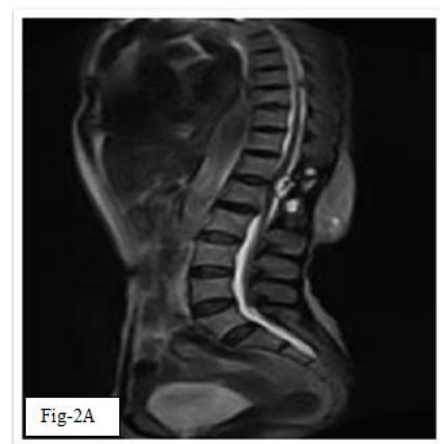
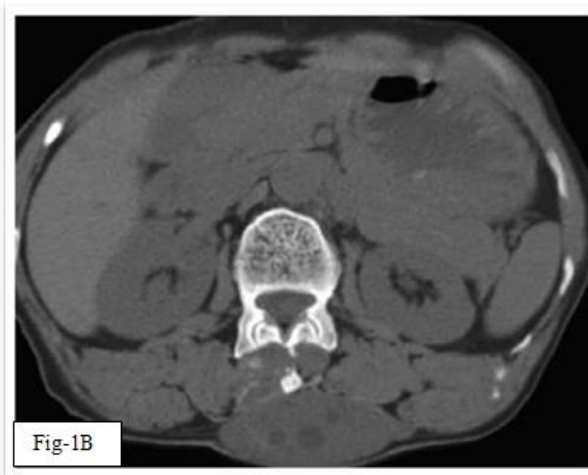
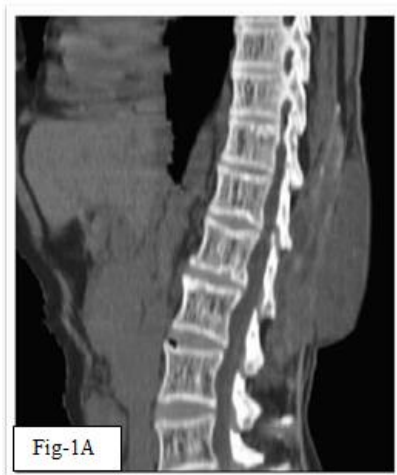now widely used for the treatment of liver hydatid cyst [2].

METHODS

It is an observational study and is carried out in the department of Radio-diagnosis at Sree Balaji Medical college & hospital, Chennai. A female patient aged 60 years presented with complaints of backache and palpable swelling in the dorso-lumbar region since 3 years. The patient voluntarily included in the study and the patient was neither supported nor additionally burdened financially.

CASE REPORT

A 60 year old female patient presents with complaints of backache and palpable swelling in the dorso-lumbar region since 3 years, progressively increasing in size.



CT SCAN of Dorso-lumbar Spine showed soft tissue attenuation lesion extending from T10- L2 vertebral levels. The lesion comprised of multiple septated cysts of average CT value of (10-17 HU) involving the sub-cutaneous region, bilateral paraspinous region and extending into soft tissues bilaterally more on right side with normal vertebral bodies. (FIG: 1A & B).

MRI of Dorso-lumbar Spine showed multilobulated multiseptated lesion from T10 – L2 vertebral levels involving the subcutaneous tissue, bilateral paraspinous soft tissues and erector spinae muscles, more on right side. The lesion has intraspinal extension causing displacement of the spinal cord anteriorly and laterally. The lesion appears isointense on T1WI and isointense to hyperintense on T2WI with multiple low signal intensity septae on T1, T2 and STIR sequences. Multiple daughter cysts are seen within it with no vertebral body destruction. (FIG: 2A & B).

DISCUSSION

Hydatid disease is a parasitic tapeworm infection. It usually occurs in liver and lungs. Involvement of hydatid cyst in para-spinal muscles is very rare [1, 2]. En bloc resection without inducing rupture and spreading the daughter cyst is

recommended treatment for intramuscular hydatid cyst [3, 4]. Clinically it manifests as pressure effects, obstruction, allergic response to cystic fluid. Parasite penetrates the intestinal muscle and enters into the inferior vena cava system through small venous connections between this system and portal circulation. Then it reaches retroperitoneum, spinal and paraspinous structures via lumbar epidural venous plexuses [4]. Currently treatment choice of muscular hydatid cyst is the combination of en bloc resection and albendazole chemotherapy [2]. Puncture, aspiration, injection and re-aspiration (PAIR) is a non-operative technique which is now widely used for the treatment. Serologic tests are valuable when they are positive but in half of the primary intramuscular hydatidosis case serology is false negative because the capsule isolates the parasite from the host's immune system. Therefore, complete reliance on serology for definitive diagnosis is not recommended [4]. However, the extent of lesion and the identification of involved structures can be best known by magnetic resonance imaging. The disease generally is not curable, and recurrence is likely. Surgery is the treatment of choice in osseous echinococcosis, although it can only eliminate the macroscopic cysts and local recurrence is reported half of the patients. However, en bloc resection without inducing rupture and spreading the daughter cyst is recommended treatment strategy [2, 4]. Puncture, aspiration, injection and re-aspiration

(PAIR) is a non-operative technique which is now effective for treatment of primary uncomplicated hepatic cysts. There is only one study in which a modification of PAIR (percutaneous drainage without re-aspiration) has been used for the treatment of muscular hydatid cyst in the literature. Puncture of a hydatid cyst leads to complications, such as anaphylactic shock or risk of iatrogenic spreading [6].

CONCLUSION

Isolated paraspinal muscle hydatid is rare and is important to diagnose this condition accurately as the treatment for it is different from other cystic lesions. Risk of leakage of fluid into surrounding tissues can cause anaphylactic shock. MRI shows exact extent and soft tissue involvement in para spinal hydatid disease.

REFERENCES

1. Cemil, B., Tun, K., Gurcay, A. G., Uygur, A., & Kaptanoglu, E. (2009). Cranial epidural hydatid cysts: Clinical report and review of the literature. *Acta neurochirurgica*, 151(6), 659-662.
2. Reuter, S., Seitz, H. M., Kern, P., & Junghanss, T. (2000). Extrahepatic alveolar echinococcosis without liver involvement: a rare manifestation. *Infection*, 28(3), 187-192.
3. Örmeci, N., Idilman, R., Akyar, S., Palabıyıkoglu, M., Çoban, S., Erdem, H., & Ekiz, F. (2007). Hydatid cysts in muscle: a modified percutaneous treatment approach. *International journal of infectious diseases*, 11(3), 204-208.
4. Sener, R. İ. F. A. T., Calli, C., Kitis, O., & Yalman, O. S. M. A. N. (2001). Multiple, primary spinal–paraspinal hydatid cysts. *European radiology*, 11(11), 2314-2316.
5. Bilgic, S., Kose, O., Sehrioglu, A., Safaz, I., & Ozkan, H. (2009). Primary paraspinal hydatid cyst treated with puncture, aspiration, injection and re-aspiration (PAIR) technique: a case report. *European Spine Journal*, 18(2), 165-167.
6. Örmeci, N., Idilman, R., Akyar, S., Palabıyıkoglu, M., Çoban, S., Erdem, H., & Ekiz, F. (2007). Hydatid cysts in muscle: a modified percutaneous treatment approach. *International journal of infectious diseases*, 11(3), 204-208.

Cite This Article: K. Subrahmany Eswar *et al* (2021). “A Case Report of Para-Spinal Hydatid Disease”. *EAS J Radiol Imaging Technol*, 3(5), 277-279.