

## Case Report

## Purple Urine Bag Syndrome: A Fascinating Cause for Purple Discoloration of Urine

Milan C. Gunawardene<sup>1\*</sup>, Madura C. Ambegoda<sup>2</sup>, Munipriya A. Willaraarachchi<sup>3</sup>, Anuruddha M. Abeygunasekera<sup>4</sup>

<sup>1</sup>Senior Registrar in Urology Department of Urology, Colombo South Teaching Hospital, Kalubowila, Sri Lanka

<sup>2</sup>Senior Registrar in Urology, Department of Urology, Colombo South Teaching Hospital, Kalubowila, Sri Lanka

<sup>3</sup>Consultant Urological Surgeon, Department of Urology, Colombo South Teaching Hospital, Kalubowila, Sri Lanka

<sup>4</sup>Consultant Urological Surgeon, Department of Urology, Colombo South Teaching Hospital, Kalubowila, Sri Lanka

### Article History

Received: 24.09.2021

Accepted: 30.10.2021

Published: 05.11.2021

### Journal homepage:

<https://www.easpublisher.com>

### Quick Response Code



**Abstract:** Purple urine bag syndrome (PUBS) is a rare clinical condition in elderly constipated females on long term urinary catheters. By-products of dietary tryptophan metabolism are implicated in its pathogenesis. Bacteria in large intestine deaminate tryptophan to indole which is detoxified in liver to indoxyl sulphate and excreted in urine. Uropathogens colonizing the catheter bags and tubes convert indoxyl sulphate to indigo (blue pigment) and indirubin (red pigment) under aerobic and anaerobic conditions respectively. The reaction between the above urinary pigments and polyvinyl chloride (PVC) is essential for the characteristic purple discoloration in urine. Asymptomatic patients are treated with regular catheter change and laxatives for constipation. Patients with symptomatic urinary tract infection, urosepsis, immunosuppression and persistent PUBS need antibiotics. Here we report PUBS in a patient with neurogenic bladder.

**Keywords:** Purple urine bag syndrome (PUBS), Urinary tract infection (UTI), Tryptophan, Indoxyl sulphate, Indigo, Indirubin.

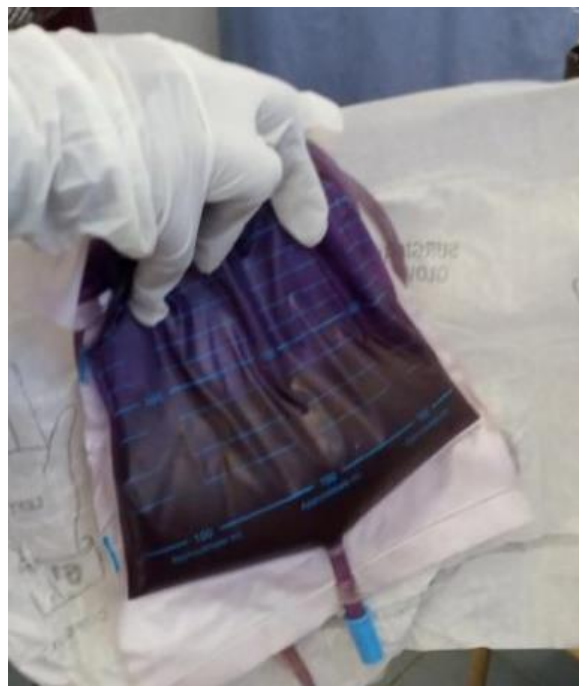
**Copyright © 2021 The Author(s):** This is an open-access article distributed under the terms of the Creative Commons Attribution **4.0 International License (CC BY-NC 4.0)** which permits unrestricted use, distribution, and reproduction in any medium for non-commercial use provided the original author and source are credited.

## INTRODUCTION

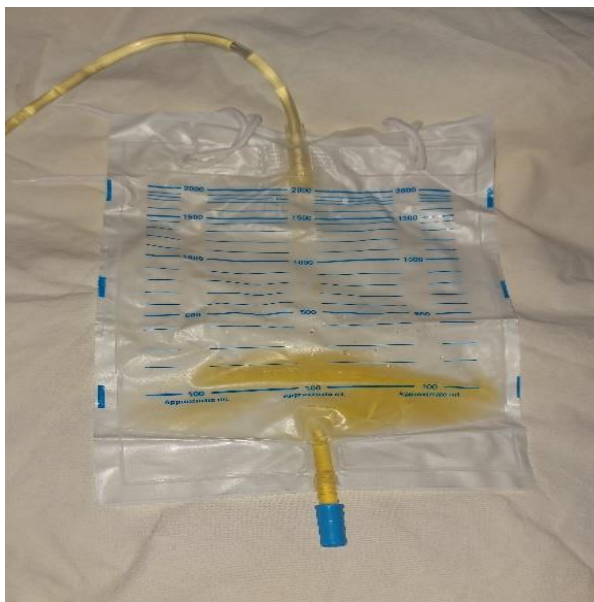Purple discoloration of urine in the catheter bag and its tubing is a rare clinical entity first reported in 1978 by Barlow and Dickson. It is a complication of urinary tract infection (UTI) by bacteria which degrade products of tryptophan metabolism [1, 2]. Here we report a case of Purple urine bag syndrome (PUBS) in an elderly female with a neurogenic bladder.

## CASE PRESENTATION

A 63 years old female was referred to the urology clinic due to purple discoloration of urine for two weeks. She was having an indwelling urethral catheter for last 28 years due to neurogenic bladder. She was asymptomatic except having constipation for last one month. There was purple colour urine in her catheter bag (Figure: 1). Urinalysis revealed 10-15 pus cells. Her urine culture showed a pure growth of *Proteus mirabilis* which was sensitive for co-trimoxazole. Her urinary catheter was changed and she was treated with oral co-trimoxazole 960 mg twice daily and laxatives for ten days. After two weeks, her urine was clear (Figure: 2) and culture remained sterile.



**Fig-1: Purple colour urine in the catheter bag and its tubing**



**Fig-2: Clear urine after treatment with antibiotics**

## DISCUSSION

PUBS is a clinically benign, less common condition even though there are reported cases with progression to Fournier's gangrene and urosepsis in immunocompromised patients [3, 4]. Advanced age, female gender, end-stage renal disease, constipation, long-term catheterization, high urinary bacterial load, alkaline urine and catheter bags and tubing made up of polyvinyl chloride (PVC) are main contributing factors for PUBS [1, 2]. Except end-stage renal disease, this patient had most of the above risk factors for PUBS.

In PUBS, catheter bags and tubes are commonly colonized with *Escherichia coli* (20.8%), *Proteus mirabilis* (16.2%) and *Klebsiella pneumoniae* (13.6%). Other less commonly involved organisms in descending order include *Enterococcus* species, *Pseudomonas aeruginosa*, *Providencia stuartii*, *Morganella morganii*, *Proteus vulgaris*, *Providencia rettgeri*, *Streptococcus faecalis*, *Enterococcus cloacae* and *Serratia marcescens* [1, 2]. Urine culture of this patient showed a pure growth of *Proteus mirabilis*.

Pathophysiology is related to tryptophan metabolism. In large intestine, tryptophanase producing gut bacteria deaminate dietary tryptophan to produce indole which is rapidly transported through enterohepatic circulation and detoxified in liver. First, cytochrome P450 2E1 (CYP 2E1) enzyme hydroxylate indole to 3-hydroxy indole and then sulfonated by SULT 1A1 iso-enzyme to form indoxyl sulphate/ indican. It is a colourless, water soluble organic compound filtered from the kidney and excreted in urine [1, 2].

Indoxyl sulphatase and phosphatase enzymes from bacteria colonizing the catheter convert indoxyl sulphate to indoxyl. This conversion most commonly (91.3%) occurs in alkaline urine. But, it is not an obligatory factor as there are few case reports in patients having slightly acidic urine (pH 6.0-6.5) also [1, 2]. Under aerobic conditions, indoxyl is oxidized to indigo (blue pigment) while conversion to indirubin (red pigment) occurs in anaerobic conditions [3]. Indigo and indirubin react with PVC in catheter bag and its tubing to produce purple colour. Without this reaction between these pigments and PVC, the urine may be dark brown in colour [4]. Furthermore, purple discoloration becomes deeper when the duration of exposure with PVC increases.

There are no standard protocols to investigate and treat the condition. Urinalysis and culture helps to confirm an associated UTI. Asymptomatic patients need regular catheter change and laxatives for constipation [5]. Antibiotics are only indicated in patients with symptomatic UTI, urosepsis, immunosuppression and persistent PUBS [4].

## CONCLUSION

PUBS is a rare clinical entity commonly seen in elderly, constipated females who are on long-term urinary catheters. Lack of awareness among healthcare professionals is a common cause for misdiagnosis and inappropriate treatment. Moreover, it is an alarming finding both to the patient and to the unaware health care workers.

## REFERENCES

1. Sabanis, N., Paschou, E., Papanikolaou, P., & Zagkotsis, G. (2019). Purple urine bag syndrome: more than eyes can see. *Current urology*, 13(3), 125-132.
2. Kalsi, D. S., Ward, J., Lee, R., & Handa, A. (2017). Purple urine bag syndrome: a rare spot diagnosis. *Disease markers*, 2017.
3. Rooney, H., Mokool, L., Ramsay, A., & Nalagatla, S. (2018). Purple urine bag syndrome: a truly harmless sign?. *Scottish medical journal*, 63(3), 99-101.
4. Worku, D. A. (2019). Purple urine bag syndrome: An unusual but important manifestation of urinary tract infection. Case report and literature review. *SAGE open medical case reports*, 7, 2050313X18823105.
5. Van Keer, J., Detroyer, D., & Bammens, B. (2015). Purple urine bag syndrome in two elderly men with urinary tract infection. *Case reports in nephrology*.

**Cite This Article:** Milan C. Gunawardene et al (2021). Purple Urine Bag Syndrome: A Fascinating Cause for Purple Discoloration of Urine. *East African Scholars J Med Surg*, 3(11), 197-198.