

Original Research Article

The Mesh Graft Technique for the Treatment of Phimosis

António Gentil Martins, MD, Prof., FICS, OLY^{1*}

¹Department of Pediatric Surgery, Children’s Hospital de D. Estefania (Hospital of Lisbon’s Central Hospitals), Lisbon, Portugal

¹Department of Childrens and Adolescents Oncology - Portuguese Cancer Institute Francisco Gentil, Lisbon, Portugal

Article History
Received: 22.09.2021
Accepted: 06.11.2021
Published: 12.11.2021

Journal homepage:
<https://www.easpublisher.com>

Quick Response Code



Abstract: Objectives: Correct the phimosis but preserving the prepuce. **Methods:** using the mesh graft plastic surgical principle often used in extensive 3rd degree burns. **Results:** Excellent aesthetic and functional results. **Conclusion:** the method of choice if one wants to correct the phimosis but preserve the prepuce. **Keywords:** Urogenital malformations, phimosis, mesh graft principle.

Copyright © 2021 The Author(s): This is an open-access article distributed under the terms of the Creative Commons Attribution 4.0 International License (CC BY-NC 4.0) which permits unrestricted use, distribution, and reproduction in any medium for non-commercial use provided the original author and source are credited.

INTRODUCTION

Phimosis means an almost closed preputial meatus, a very frequent problem for young males, usually associated with a penis of normal dimensions. Apart from the indications for circumcision due to religious beliefs, and although many times the simple use of progressive foreskin retraction (often associated with corticosteroids) can solve the problem, in some more severe cases of phimosis, surgery becomes mandatory for normal penile function.

MATERIAL AND METHODS

Significant Phimosis can be a motive for great anxiety both for the child and his parents, so it should be corrected as soon as the problem is detected. Some surgeons to assure a more perfect preputial removal prefer to use an appropriate device.

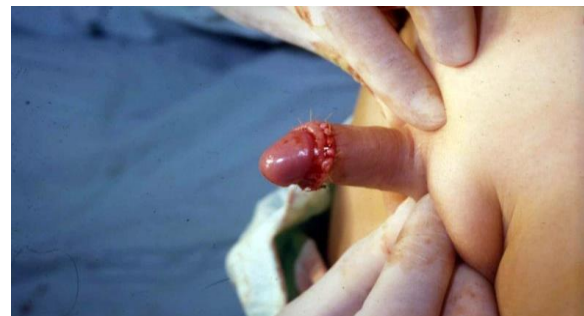

Fig-2: Final appearance, as in any “classical” circumcision, the skin being sutured with plain cat-gut

The technique we suggest for the correction of phimosis while preserving the prepuce, is inspired in the mesh graft technique used in plastic surgery, namely in burns, when there is not enough skin available for grafting.

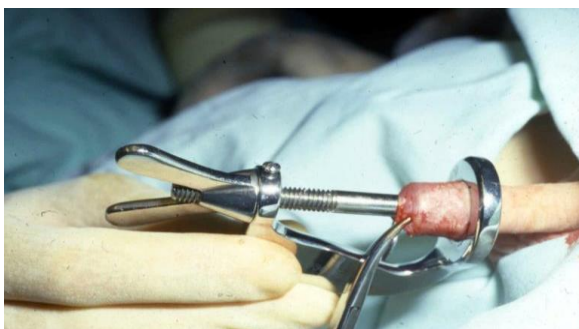

Fig-1: Circumcision, using a gadget for removal of the foreskin

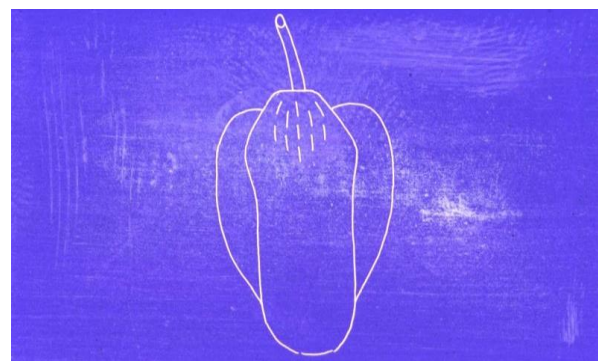


Fig-3: Schematic Drawing of the preputial incisions

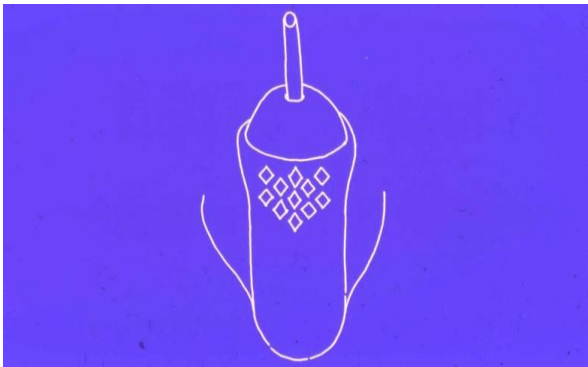

Fig-4: Schematic Drawing of the “opened” preputial incisions

Surgical Technique

Starting at the most stenosed anterior area, several small (approximately 4mm) non matched superficial incisions of the skin and dartos are performed all around, until one reaches complete disappearance of the constriction, the skin remaining with multiple small open diamond wounds.

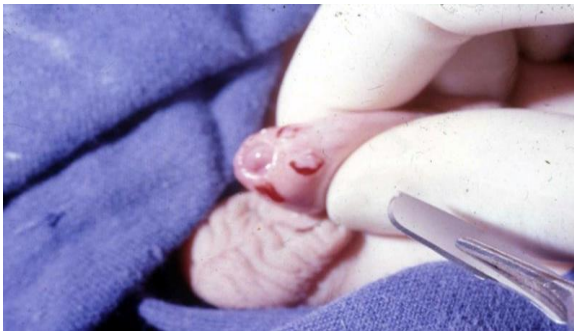

Fig-5: Small incisions started at the stenotic prepuce, with the open diamond wounds at operation

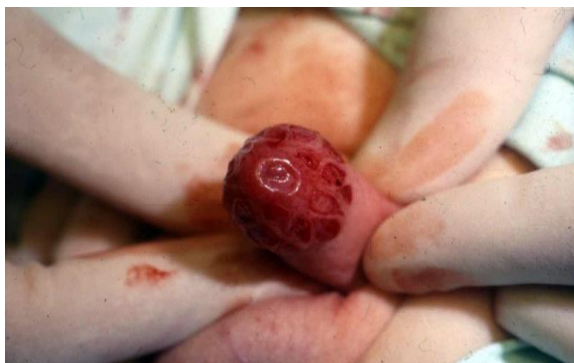

Fig-6: Progressively prolonging proximally the preputial skin incisions

One tries to avoid damaging the dartos vessels but, if needed, electrocoagulation is used. In order to avoid restenosing of the prepuce, the penile skin immediately behind the open diamond wounds, is sutured to the pubo-scrotal skin and is to be maintained retracted at least a minimum of 5 days, to allow for complete healing (epithelialization) of the raw preputial surfaces.

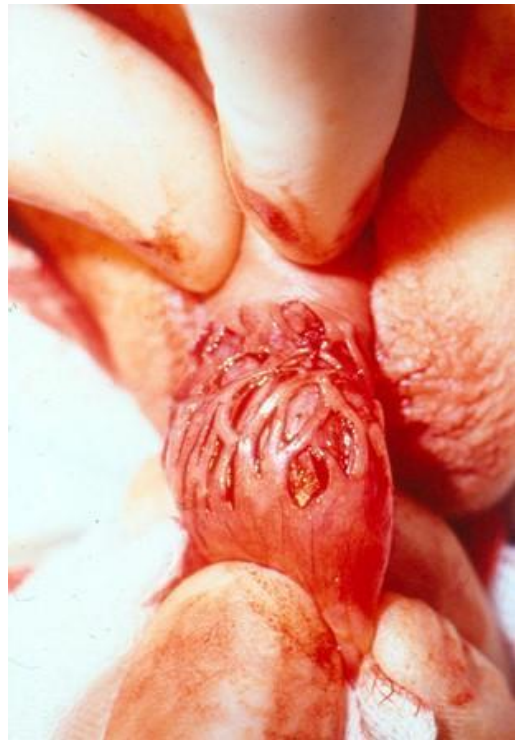

Fig-7: “Mesh graft” appearance of the wound

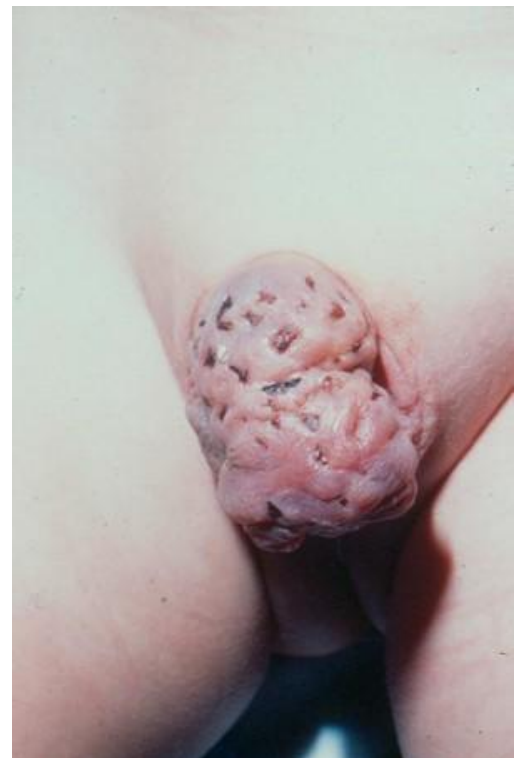

Fig-8: Overcoming of phimosis but still maintaining the full preputial skin

Edema may remain for several days, but when it completely fades away, then the penile look just looks normal and with no phimosis.

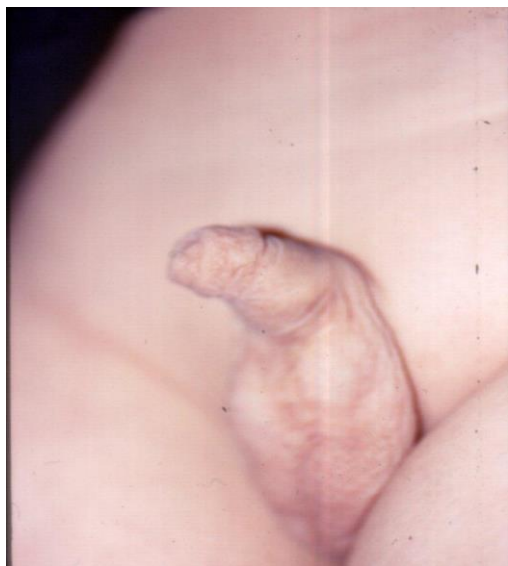

Fig-9: Appearance some weeks later

DISCUSSION AND RESULTS

In some patients and when the phimosis is not too severe, a simple dorsal incision on the prepuce (the so-called Estor maneuver) can be used. For complete removal simple surgery can be performed or one can use a special and appropriate device.

A Patient suffering from phimosis is usually treated with foreskin removal, the so-called circumcision. The preputial wound is then closed with separate stitches of a absorbable material, usually plain cat-gut.

With the technique we are suggesting the prepuce can be preserved with an excellent cosmetic and functional result, pleasing patients and Parents. Nevertheless it is important to explain to the Parents that local preputial edema may persist for a long time (simulating a non-existing paraphimosis) but that ultimately will subside, (although at times lasting a long time.....). In spite of the sutures placed between penile skin and the peno-scrotal junction it is important to alert the Parents to daily verify the preputial retraction and if needed to do it, even manually, for the minimal time to allow for total epithelialization of the open diamond wounds. The final results are excellent, with a normal looking and functional non-phimosis prepuce, although only recognizable later, what must be stressed to the Parents for their alternative decision.

In the vast majority of phimosis and if one wants to preserve the prepuce, the technique is simple and effective, bringing peace to the Parents and the children.

The mesh graft technique for the treatment of phimosis allows for the integral maintenance of the

preputial skin. On the other end there will not be any functional problems in the future.

Disclaimer

- The paper is a single author piece and presents no conflict of interests
- Conflict of interest (Please disclose all relevant and potential Conflict of interest as described in 4. ETHICAL CONSIDERATION in this guideline) - No conflict of interest
- Approval of the research protocol by an Institutional Review Board - N/A
- Informed Consent - N/A
- Registry and the Registration No. of the study/trial- N/A
- Animal Studies - N/A

REFERENCES

1. Ad, Hutson, J.M., Beasley, S.W., Woodward, A. (1992). A Chapter 30 The penis Circumcision pag 176 Hypospadias 177-179 Jone's Clinical Pediatric Surgery Blackwell Scientific Publications.
2. Arkovitz, M.S., Ziegler, M.M., Azizkhan, R.G., Weber, T.R. (2003). Chapter 81 Circumcision Operative Pediatric Surgery International Edition.
3. Ed Benson, C.D., Mustard, W.T. Ravitch, M.M. Snyder Jr W H Welch K J Inc Chapter 63 The male Genital Tract Phimoses 1024-1025 Inc Chapter 63 The male Genital Tract Phimoses 1024-1025 1962 Pediatric Surgery Vol II Year Book Medical Publishers
4. Ed Benson, C.D., Mustard, W.T., Ravitch, M.M. Snyder Jr W H Welch K J Chapter 64 Hypospadias 1062-1081 Pediatric Surgery Vol II Year Book Medical Publishers Inc
5. Figueroa, T.E., Casale, P. (2003). Surgical Directives Pediatric Surgery Peter Mattei Chapter 123 Circumcision Lippincott Williams & Wilkins.
6. Gentil, Martins, A. (1977). A new Technique for the treatment of phimosis IV World Symposium of Pediatric Surgery Barcelona July.
7. Hamed, T. (2009). Hadidi Chapter 30 Penis 30.1 Phimosis pag 615-618 Ed Zacharias Zachariou Pediatric Surgery Digest Springer.
8. Homewood, Nixon, H. (1978). Chapter 29 Abnormalities of the Male Genital System Circumcision 346 Homewood Nixon H Surgical Conditions in Pediatrics Butterworths.
9. Leape, L. L. (1980). Circumcision Pediatric Surgery W.B.Saunders Company Chapter , 59; 793-795
10. Ombrédanne, L. (1923). Phimosis Ombrédanne L Précis Clinique et opératoire de Chirurgie Infantile Masson & Cie; 573-578
11. Trier, W. C., Drach, G.W. (1973). Concealed penis: another complication of circumcision American Journal of Diseases of Children, 125; 276-277
12. Swenson, O. (1958). Chapter 30 Phimosis Pediatric Surgery Appleton Century Crofts Inc, 545-551.

Cite This Article: António Gentil Martins (2021). The Mesh Graft Technique for the Treatment of Phimosis. *East African Scholars J Med Surg*, 3(11), 226-228.