

Review Article

Penetrating Rectal Injury Presenting as Scrotal and Perineal Cellulitis – A Case Report and Review of Literature

Dr. Parthasarathi Hota^{1*}, Dr. Aaryan Kanwarinder Singh Dhillon², Dr. Bhanu Pratap Rana²¹Assistant Professor, Department of General Surgery, Pacific Institute of Medical Sciences, Udaipur, India²Junior Resident, Department of General Surgery, Pacific Institute of Medical Sciences, Udaipur, India**Article History**

Received: 18.10.2021

Accepted: 24.11.2021

Published: 30.11.2021

Journal homepage:<https://www.easpublisher.com>**Quick Response Code**

Abstract: Rectal injuries due to blunt or penetrating trauma are associated with significant morbidity and mortality, yet there is a lack of consensus regarding their optimal management. The management of penetrating rectal trauma invokes a complex decision tree that has been established based on lessons learned during war. It involves proximal faecal diversion by a stoma, rectal washout and placement of pre-sacral drain. Today surgeons worldwide variably use these techniques. We present a case where a young male accidentally slipped and fell on a beer bottle which got inserted in his rectum. He presented a few days later with scrotal and perineal cellulitis.

Keywords: Rectal injury, extraperitoneal rectal injury, penetrating rectal injury, scrotal cellulitis.

Copyright © 2021 The Author(s): This is an open-access article distributed under the terms of the Creative Commons Attribution **4.0 International License (CC BY-NC 4.0)** which permits unrestricted use, distribution, and reproduction in any medium for non-commercial use provided the original author and source are credited.

INTRODUCTION

Although intra- and extra peritoneal rectal injuries are both relatively uncommon, largely due to the protected position of the rectum within the bony pelvis, they can be difficult to diagnose and are often missed at patients' initial presentation [1]. There are numerous studies in the literature examining the management options and outcomes following colonic trauma, with considerable evidence that most colonic injuries can be safely managed by primary repair or resection and anastomosis [2, 3]. Diverting stomas are only indicated in the sickest of patients following colonic trauma, i.e., those with high Injury Severity Scores (ISS) or significant comorbidities, and in the elderly population [4, 5]. However, the management of rectal trauma entails complex decision making regarding the need for faecal diversion (end or loop colostomy), distal rectal irrigation, and presacral drainage, as well as the need for suture repair or resection and anastomosis [6]. There is currently insufficient information from robust rectal trauma data to accurately inform this process.

CASE PRESENTATION

A 41 year old male patient presented in the emergency complaining pain over his scrotum and perineum for last two days. He was also experiencing difficulty in passing stool for last 2 days. Patient gave a curious history upon detailed questioning. About 5 days ago, he accidentally slipped and fell over a beer bottle in his house. The bottle got inserted in this rectum. He took out the bottle himself which was followed by some bleeding per rectally. Next morning he passed stool normally but afterwards a pain started over the perineal region which gradually intensified over time and scrotal pain soon followed.

On examination, he was conscious but febrile. Scrotum was enlarged, tense and tender more in the left side. There was tenderness in the perineum and perianal region. Abdomen was soft without any tenderness and bowel sounds were normal.

On per rectal examination, a full thickness tear at the rectal wall palpated around 3 O'clock position which was admitting examining finger. It was painful and there was blood staining on the finger. Sphincter integrity was not compromised. Proctoscopy not done.

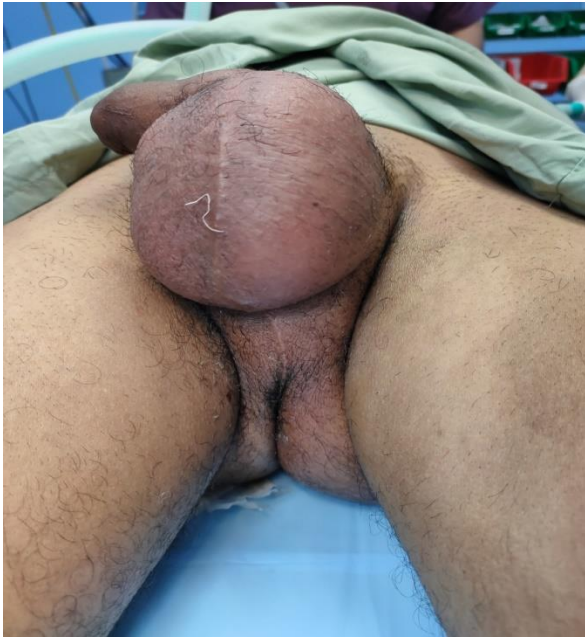

Fig 1: Clinical photograph showing enlarged and inflamed scrotum and perineum

Laboratory investigations were essentially normal except leucocytosis which is to be expected in these cases. Abdominal ultrasonography was normal.

Ultrasonography scrotum & perineum shows:

1. Minimum amount of fluid collection with internal air foci in left scrotal sac.
2. Slightly increased vascularity in left testis.
3. Probe tenderness in left half of scrotum & perineum.

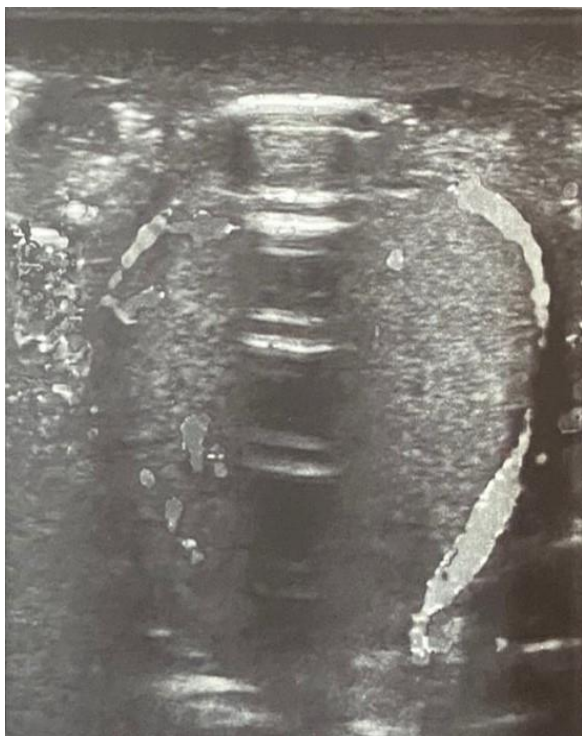

Fig 2: Ultrasonography of scrotum & perineum

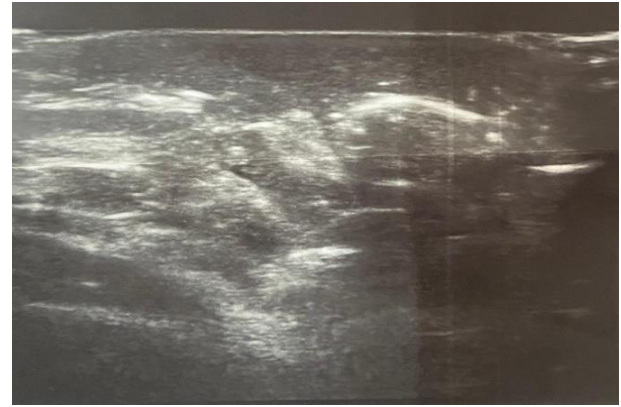


Fig 3: Ultrasonography of scrotum & perineum

Our provisional diagnosis was scrotal & perineal cellulitis secondary to extraperitoneal full thickness rectal injury. Patient was posted for surgery on the same day.

EUA [Examination under anaesthesia] was done and full thickness breach in rectal wall about 4cm in size at 3 o' clock position was present in lower rectum. Finger was going through the left ischio-rectal fossa and there was a large ischio-rectal abscess on the left side.

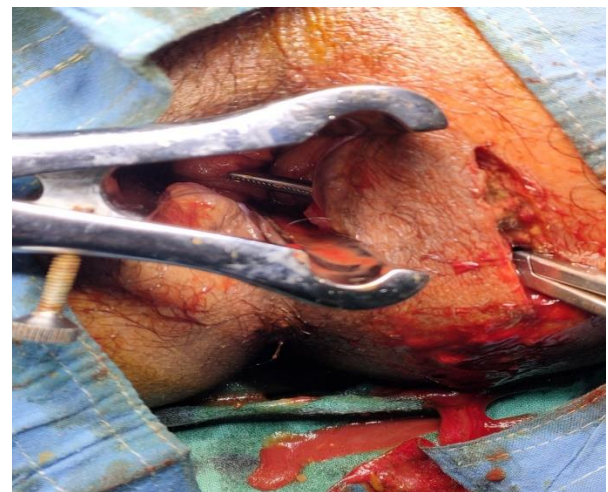


Fig 4: Operative photograph shows full thickness breach in the rectal wall and communication with the ischio-rectal fossa

We decided in favour of faecal diversion by doing loop ileostomy. We drained the ischio-rectal abscess after taking sample for culture and repaired rectal injury by interrupted vicryl sutures. Debridement of the necrotic tissue done in ischio-rectal fossa. Proper toileting of the abscess cavity done and pack given. Scrotal sac was found to be oedematous but there was no abscess in the scrotum. Post-operative recovery of the patient was uneventful. Antibiotics were given to the patient according to the culture and sensitivity report.

Repeated dressings were done daily for few days and patient was discharged after 7 days with healthy condition with stoma functioning properly and wound over ischio-rectal fossa healthy with red granulation tissue and no pus. Patient was advised sitz bath and ileostomy reversal planned after 3 months.

DISCUSSION

Although rectal injuries are relatively rare, they are associated with a significant mortality rate and most commonly occur in young, male patients following penetrating trauma. We identified the substantial morbidity associated with such injuries, including high rates of SSI, pneumonia, and AKI, in addition to a prolonged length of ICU and overall hospital stay. Over the last century, mortality rates following rectal injuries have fallen but much controversy still remains regarding the optimal management of such injuries. The introduction of primary suture repair with occasional use of diverting colostomy during World War I reduced mortality from 90 to 67% [7]. Subsequently, during World War II with standard fecal diversion and presacral drainage, mortality was reduced to 30%. With improved resuscitation techniques and antibiotic prophylaxis, primary repair and distal rectal washout further reduced mortality during the Vietnam War to 15% [7-9].

Current treatment of rectal injuries includes various combinations of what we refer to as the four D's of rectal trauma: (1) distal rectal washout, (2) damage repair, (3) diversion of the faecal stream, and (4) drainage of the presacral space. The use of all these therapeutic manoeuvres is accepted in high-velocity wartime injuries. However, the treatment of civilian rectal injuries is a subject of great debate. Diversion of the faecal stream proximal to the site of rectal injury remains the gold standard for the treatment of civilian rectal trauma.[10-12] Recently, the first prospective randomized study in the field of civilian rectal trauma was performed to evaluate the role of presacral drainage.[11] These authors concluded that placement of a presacral drain had no effect on infectious complications in penetrating rectal injuries.

Our patient had extraperitoneal rectal injury without compromising sphincter integrity. He had a full thickness rectal wall breach and associated with large ischio-rectal abscess in the left side. We performed proximal faecal diversion in the form of loop ileostomy. Though most of the literature suggests faecal diversion in the form of colostomy, we decided in favour of loop ileostomy as it is technically easier to perform with comparable results. Ischio-rectal abscess drained and rectal injury repaired with interrupted absorbable sutures.

Gash *et al.*, in their study found that, for isolated extraperitoneal injuries, primary suture repair alone (without stoma) was associated with a

comparable overall complication rate and mortality, to the suture repair of intraperitoneal injuries. For extraperitoneal rectal injuries, patients managed with resection/ repair + stoma had a significantly longer hospital stay and higher postoperative morbidity compared to resection/repair without stoma despite no significant difference in ISS. Thus, suture repair or resection without ostomy may offer sufficient surgical management for isolated extraperitoneal injuries [13].

Gonzalez *et al.*, prospectively analysed outcomes for 14 patients with penetrating, non-destructive extraperitoneal rectal injuries, managed without stoma formation, demonstrating good results and advocating avoidance of faecal diversion [14]. Similarly, Levine *et al.*, investigated whether primary repair without diversion was adequate management for extraperitoneal rectal injuries [15]. Of the 30 patients included, six were managed with primary suture repair and no stoma [repair + stoma ($n = 11$) and defunctioning stoma alone ($n = 13$)]. There was no significant difference in morbidity or mortality for the no stoma group. They concluded that it was feasible to avoid a stoma, in stable patients with minimal contamination, without major associated injuries, but advise faecal diversion where the laceration cannot be safely visualized and repaired without extensive rectal mobilization. Weinberg *et al.* in their study outlined the implementation of a clinical pathway to standardize care of patients with rectal trauma, according to the characterization of the injury relative to retroperitoneal involvement [16]. Stomas were avoided in selected patients with extraperitoneal injury—where the defect could be safely repaired, although inaccessible injuries were diverted. Infective complications were significantly lower (13 vs. 31%, $p < 0.05$) when compared with a prepathway matched cohort.

Our patient came to us five days after the trauma when he already developed unilateral ischio-rectal abscess along with scrotal & perineal cellulitis. At surgery we found that the abscess cavity was large with considerable pus and necrotic tissue. It was communicating with the rectal wall through the full thickness breach. Therefore we decided to perform faecal diversion. Furthermore, the rectal wall injury was clearly palpable but not adequately visible. Sutures were placed mostly under the guidance of surgeon's finger. We believe faecal diversion by ileostomy/colostomy should be done in all such cases.

For intraperitoneal injuries, or for extensive low rectal injuries that cannot be satisfactorily sutured transanally, laparotomy and primary repair are currently advocated, with or without distal rectal washout, presacral drainage, and/ or stoma formation. While the posterior rectal wall should ideally be examined in anterior wall injuries, whether the extraperitoneal rectum should be mobilised remains a matter of debate [17].

Diversion is usually advocated in patients in whom an anastomosis may not heal, i.e., those with delayed diagnosis or haemorrhagic/septic shock with potential compromise of gut perfusion. If primary repair is not feasible or the patient is compromised, forming a defunctioning loop colostomy, which diverts faeces away from the defect and can be easily closed at a later date, has been advocated [17]. With extensive extraperitoneal injury, a Hartmann's procedure may be indicated, or if a rectal defect could be repaired transanally, but the patient also has significant pelvic or perineal injuries, it is considered appropriate to perform faecal diversion [18]. In such patients, stomas reduce the rates of necrotizing fasciitis in pararectal fat from contamination [19].

CONCLUSION

Trauma or unintentional injury is a leading cause of morbidity and mortality throughout the world. Prompt trauma assessment and immediate attention to life-threatening injuries as per advanced trauma life support (ATLS) protocol is crucial. Afterwards, the management of rectal injuries is multifactorial and requires considerable judgment to tailor treatment to specific patients to optimise outcomes. Rectal injury should be suspected in all blunt or penetrating injuries involving the pelvic and perineal region and managed accordingly. Isolated extra peritoneal rectal injury in stable patients without complication can be managed by repair alone but other patients with considerable injury, abscess formation, difficult location, delayed presentation or with complication and in cases of intraperitoneal injury, faecal diversion by a stoma should be considered.

Declarations:

Conflict of Interest: None

Ethical Approval: Not required

REFERENCES

- Hefny, A. F., Al-Ashaal, Y. I., Bani-Hashem, A. M., & Abu-Zidan, F. M. (2010). Seatbelt syndrome associated with an isolated rectal injury: case report. *World journal of emergency surgery*, 5(1), 1-6.
- Carrillo, E. H., Somberg, L. B., Ceballos, C. E., Martini Jr, M. A., Ginzburg, E., Sosa, J. L., & Martin, L. C. (1996). Blunt traumatic injuries to the colon and rectum. *Journal of the American College of Surgeons*, 183(6), 548-552.
- Maxwell, R. A., & Fabian, T. C. (2003). Current management of colon trauma. *World journal of surgery*, 27(6), 632-639.
- Steele, S. R., Maykel, J. A., & Johnson, E. K. (2011). Traumatic injury of the colon and rectum: the evidence vs dogma. *Diseases of the colon & rectum*, 54(9), 1184-1201.
- Hatch, Q., Causey, M., Martin, M., Stoddard, D., Johnson, E., Maykel, J., & Steele, S. (2013). Outcomes after colon trauma in the 21st century: an analysis of the US National Trauma Data Bank. *Surgery*, 154(2), 397-403.
- Bosarge, P. L., Como, J. J., Fox, N., Falck-Ytter, Y., Haut, E. R., Dorion, H. A., ... & Gonzalez, R. P. (2016). Management of penetrating extraperitoneal rectal injuries: an Eastern Association for the Surgery of Trauma practice management guideline. *Journal of Trauma and Acute Care Surgery*, 80(3), 546-551.
- Wallace, C. (1916). A study of 1200 cases of gunshot wounds of the abdomen. *Journal of British Surgery*, 4(16), 679-743.
- McGrath, V., Fabian, T. C., Croce, M. A., Minard, G., & Pritchard, F. E. (1998). Rectal trauma: management based on anatomic distinctions. *The American surgeon*, 64(12), 1136-1141.
- Taylor, E. R., & Thompson, J. E. (1948). The early treatment, and results there of, of injuries of the colon and rectum, with 70 additional cases. *J Am Med Assoc*, 138(1), 209-228.
- Grasberger, R. C., & Hirsch, E. F. (1983). Rectal trauma: a retrospective analysis and guidelines for therapy. *The American Journal of Surgery*, 145(6), 795-799.
- Gonzalez, R. P., Falimirski, M. E., & Holevar, M. R. (1998). The role of presacral drainage in the management of penetrating rectal injuries. *Journal of Trauma and Acute Care Surgery*, 45(4), 656-661.
- McGrath, V., Fabian, T. C., Croce, M. A., Minard, G., & Pritchard, F. E. (1998). Rectal trauma: management based on anatomic distinctions. *The American surgeon*, 64(12), 1136-1141.
- Gash, K. J., Suradkar, K., & Kiran, R. P. (2018). Rectal trauma injuries: outcomes from the US National Trauma Data Bank. *Techniques in coloproctology*, 22(11), 847-855.
- Gonzalez, R. P., Phelan III, H., Hassan, M., Ellis, C. N., & Rodning, C. B. (2006). Is fecal diversion necessary for nondestructive penetrating extraperitoneal rectal injuries?. *Journal of Trauma and Acute Care Surgery*, 61(4), 815-819.
- Levine, J. H., Longo, W. E., Pruitt, C., Mazuski, J. E., Shapiro, M. J., & Durham, R. M. (1996). Management of selected rectal injuries by primary repair. *The American journal of surgery*, 172(5), 575-579.
- Weinberg, J. A., Fabian, T. C., Magnotti, L. J., Minard, G., Bee, T. K., Edwards, N., ... & Croce, M. A. (2006). Penetrating rectal trauma: management by anatomic distinction improves outcome. *Journal of Trauma and Acute Care Surgery*, 60(3), 508-514.
- Gonzalez, R. P., & Turk, B. (2002). Surgical options in colorectal injuries. *Scandinavian journal of surgery*, 91(1), 87-91.
- Miller, B. J., & Schache, D. J. (1996). Colorectal injury: where do we stand with repair?. *Australian and New Zealand journal of surgery*, 66(6), 348-352.
- Merlino, J. I., & Reynolds, H. L. (2004). Management of rectal injuries. *Semin Colon Rectal Surg*, 15, 70-79.

Cite This Article: Parthasarathi Hota et al (2021). Penetrating Rectal Injury Presenting As Scrotal and Perineal Cellulitis – A Case Report and Review of Literature. *East African Scholars J Med Surg*, 3(11), 232-235.