

## Case Report

## Adenoid Cystic Carcinoma Bronchus - A Case Report

Dr. Alina Mariam Varghese<sup>1\*</sup>, Dr. Sankar S<sup>2</sup><sup>1</sup>Junior Resident, Department of Pathology, Government Medical College, Kottayam, Kerala, India<sup>2</sup>Professor and Head of the Department, Department of Pathology, Government Medical College, Kottayam, Kerala, India

## Article History

Received: 11.11.2021

Accepted: 15.12.2021

Published: 28.01.2022

## Journal homepage:

<https://www.easpublisher.com>

## Quick Response Code



**Abstract:** Primary adenoid cystic carcinoma of lung is an unusual thoracic neoplasm, which is considered as a slow-growing low-grade malignancy. Usually, it is diagnosed at a higher clinical stage and is difficult to resect due to its central location. A 48-year-old female presented with history of breathlessness. On chest Xray and CT-Thorax showed well defined soft tissue lesion in left main bronchus. She underwent left pneumonectomy and subcarinal node dissection. Histopathological examination was consistent with Adenoid Cystic Carcinoma Bronchus.

**Keywords:** Adenoid cystic carcinoma, bronchus, central.

**Copyright © 2022 The Author(s):** This is an open-access article distributed under the terms of the Creative Commons Attribution **4.0 International License (CC BY-NC 4.0)** which permits unrestricted use, distribution, and reproduction in any medium for non-commercial use provided the original author and source are credited.

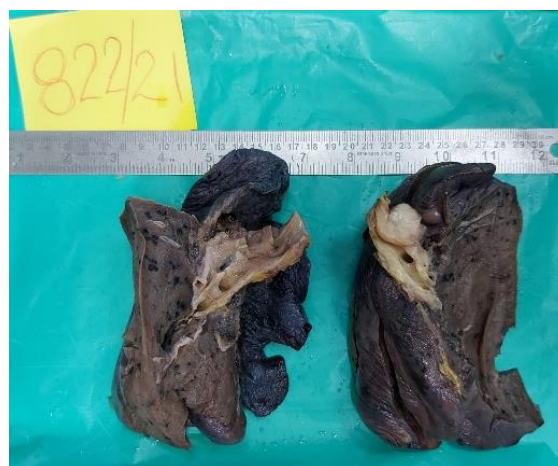## INTRODUCTION

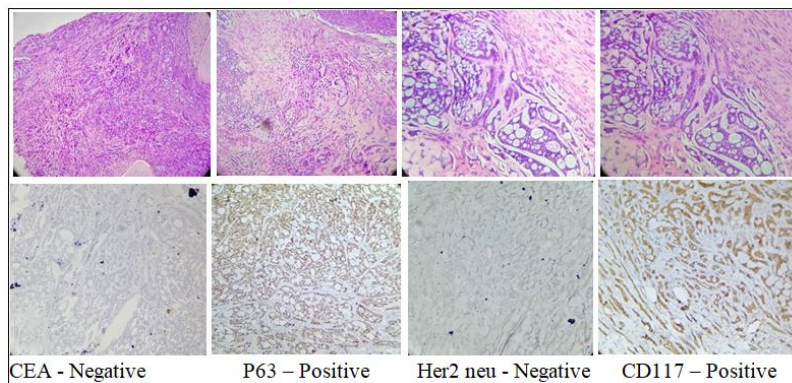
Malignant salivary gland type tumors, originating outside the head and neck, are rare. They are reported in the breast, skin, cervix, and lung. Primary adenoid cystic carcinoma of lung is a rare tumor, and probably accounts for 0.04-0.2% of all primary pulmonary tumors. They originate from the peribronchial glands and they are usually proximally located. ACC is more common in the central bronchi than in the segmental bronchi. Unlike other bronchopulmonary tumors, ACCs are not associated with smoking or other risk factors and they are considered as low-grade malignant neoplasms.

## CASE REPORT

A 48-year-old female who presented with breathlessness since 2 months. On evaluation, Chest X-ray and CT Thorax showed an intraluminal well defined soft tissue density enhancing lesion measuring 2.2x 1.9cm in left main bronchus. PET-CT also showed enhancing lesion involving left main bronchus. So she underwent left pneumonectomy and sub carinal node dissection. Microscopic examination showed an infiltrating neoplasm composed of cells arranged in cribriform pattern, tubules and cords. Individual cells

with scanty cytoplasm, mildly pleomorphic round /oval hyperchromatic nuclei. Mitosis sparse. The tubules were lined by luminal cells which are cuboidal and abluminal flattened cells. They are filled with mucinous material. Perineural invasion seen. Neoplasm is seen tracking along cartilaginous plates. It was extending throughout the thickness of bronchial wall. Immunohistochemistry showed, CD117-Positive, P63-positive, CEA-Negative, Her2 neu-Negative which favored Adenoid Cystic Carcinoma Bronchus.





**Follow-up:** Patient underwent radiotherapy.

## DISCUSSION

ACC is a rare but distinct salivary gland-type malignant neoplasm arising uncommonly as a primary tumor in the lung. ACC of the lung is a malignant tumor arising in the tracheobronchial glands distributed in the airway submucosa, with a morphology similar to ACC arising in the salivary glands. ACC of the lung was reported mainly in young patients, with a slight female predominance. Unlike other lung carcinomas, smoking is not thought to be a definite risk factor for the development of primary ACC. Clinically, coughing was the most common symptom, followed by hemoptysis and shortness of breath. Symptoms were not specific and misleading, explaining the delay in diagnosis. As a result, several patients are wrongly treated for asthma and bronchitis.

Tumor exhibits three predominant histological growth patterns. The most frequent and predominant pattern is the cribriform followed by the tubular pattern and then the least frequent and the most aggressive is the solid pattern. The solid histological pattern has been associated with a more aggressive clinical course and early distant metastases, in contrast to the cribriform type which shows a more benign behavior. Vascular emboli and lymph node metastases are uncommon, while perineural invasion has been frequently reported, which was consistent with our findings.

In order to eliminate the diagnosis of conventional adenocarcinoma and small cell carcinoma of lung in areas showing a predominant solid or tubular pattern, the immunohistochemistry study is highly recommended. In fact, the expression of myoepithelial markers, such as P63, SMA, C-kit, and S-100 protein, is a strong argument for ACC of the lung.

The first-line treatment for ACC is surgical resection. As ACC often arises in the central airways, tracheobronchoplasty is also often indicated. In addition, although the tumor may appear localized, the resection margins may show positive results for tumor cells due to widespread invasion along the airway. However, radiation sensitivity is relatively high, so radiotherapy may be useful.

ACC of the lung may show a partial response to targeted therapies. The place of Imatinib has been demonstrated in strongly c-Kit expressing tumors.

## CONCLUSION

ACC of the lung is indolent and slow growing tumor, long-term recurrences are quite frequent. The prognostic parameters depend on predominant histological pattern, tumor staging and surgical margin status. A case of Adenoid cystic carcinoma in a middle-aged woman in main bronchus is reported.

## REFERENCES

- William, D. T. (2015). WHO Classification of tumors of the Lung, Pleura, Thymus and Heart, 4th Edition, France, International Agency for research on Cancer.
- Kitada, M., Ozawa, K., Sato, K., Hayashi, S., Tokusashi, Y., Miyokawa, N., & Sasajima, T. (2010). Adenoid cystic carcinoma of the peripheral lung: a case report. *World journal of surgical oncology*, 8(1), 1-4.
- Bhattacharyya, T., Bahl, A., Kapoor, R., Bal, A., Das, A., & Sharma, S. C. (2013). Primary adenoid cystic carcinoma of lung: a case report and review of the literature. *Journal of cancer research and therapeutics*, 9(2), 302-304.
- Krifa, M., Bdioui, A., Lajmi, Z., Missaoui, N., Hmissa, S., & Mokni, M. (2021). Primary adenoid cystic carcinoma of the lung: A case report and literature review. *Heliyon*, 7(2), e06206.

**Cite This Article:** Alina Mariam Varghese & Sankar S (2022). Adenoid Cystic Carcinoma Bronchus - A Case Report. *East African Scholars J Med Sci*, 5(1), 21-22.