

Effects of *Spondias mombin* and *Aspilia africana* Aqueous Extracts on Rats with Monosodium Glutamate-Induced Leiomyoma

P. E. Eze-Steven^{1*}, S. C. Udedi², C. M. Ude¹

¹Applied Biochemistry Department, Enugu State University of Science and Technology, Enugu State, Nigeria

²Applied Biochemistry Department, Nnamdi Azikiwe University, Awka, Anambra State, Nigeria

*Corresponding author:

P. E. Eze-Steven

Received: 25.01.2019

Accepted: 06.02.2019

Published: 25.02.2019

Abstract: Uterine leiomyoma is commonly known as fibroid. Increased use of chemicals is believed to enhance its prevalence and monosodium glutamate is implicated. Fibroid is prevalent among black women with no known drug for its treatment. It is therefore necessary to determine a safer method for fibroid treatment. This work investigated effects of different aqueous extracts of *Spondias mombin* (hog plum) and *Aspilia africana* (wild sunflower) leaves on uterus and kidney cells of rats with monosodium glutamate (MSG)-induced fibroid. Twenty-eight rats used in this study were divided into four groups of seven rats each and acclimatized. Fibroid was induced on the Positive control, Groups III and IV, after daily ingestion of 750mg/kg body weight of MSG for 28 days. Negative control had no fibroid but the Positive control remained untreated. Groups III and IV were continuously ingested with same dose of MSG for the next 28 days with daily oral treatment using 250mg/kg body weight aqueous extracts of hog plum and wild sunflower, respectively. Histological examinations were performed on the 2nd and 4th weeks, respectively, on two rats from each group for the next 28 days. Results showed degenerated endometrial cells and preserved nephritic tissues after treatment with aqueous extracts of *S. mombin* leaves. There was mild hyperplasia of endometrial cells after treatment with extract of *A. africana* in the 2nd week which differed from the 4th week. MSG has nephrotoxic properties and aqueous extract of *S. mombin* alleviated MSG oxidative powers on rats' endometrial cells. With continuous ingestion, *A. africana* aqueous extract better preserved rat's endometrium from oxidizing action of MSG. These extracts could be used as safer chemotherapy in fibroid management.

Keywords: Leiomyoma, monosodium glutamate (MSG), *Spondias mombin*, *Aspilia africana*, uterus, kidney.

INTRODUCTION

Global civilization has made the use synthetic chemicals part of our everyday life with monosodium glutamate (MSG), used popularly in Nigeria as a food seasoning, a common example [1]. These chemicals, known as endocrine disruptors, interfere with our developmental processes by affecting the endocrine system [2] leading to various disorders like leiomyoma. Also known as fibroid [3], uterine leiomyoma is a benign disorder that is prevalent among black women [4] in their reproductive-age bracket [5] with high morbidity and mortality rates [6].

In Nigeria, the high incidence of fibroid among reproductive-aged women ranges from 17.9 – 26% compared to 5 – 11% reported in Europe and United States [7]. Therefore, seeking a better therapeutic

alternative is vital in checking the high mortality rates and financial involvements associated with leiomyoma.

Monosodium glutamate (MSG) is also in use, in Nigeria, as a bleaching agent for stain removal from clothes [8]. MSG has been shown to be toxic to humans and experimental animals [9], induces fibroid in laboratory rats [10], and leads to the excessive production of free radicals (ROS) following its ingestion [11].

In Nigeria, the choice of alternative medicine in treatment of diseases is on the increase with *Spondias mombin* (Linn) used in treating postpartum infections of the uterus [12] while *Aspilia africana* (C. D. Adams Compositae) is used to induce delivery [13]. The use of these plants in the management of uterine fibroid has

Quick Response Code



Journal homepage:

<http://crosscurrentpublisher.com/ccijmb/>

Copyright © 2019 The Author(s): This is an open-access article distributed under the terms of the Creative Commons Attribution 4.0 International License (CC BY-NC 4.0) which permits unrestricted use, distribution, and reproduction in any medium for non-commercial use provided the original author and source are credited.

DOI: 10.36344/ccijmb.2019.v01i01.005

not been documented, hence this study. The objective of this study is to investigate the effects of these leaves on uterine and kidney cells of Wistar rats with monosodium glutamate-induced fibroid.

MATERIALS AND METHODS

This experiment was done at the Biochemistry Department of Enugu State University of Science and Technology (ESUT), Agbani, Enugu State and Histopathology Laboratory of ESUT Teaching Hospital, Enugu, Enugu State.

Two different leaves Hog plum (*Spondias mombin*) and Wild sunflower (*Aspilia africana*) were used in this study. Both plants were harvested young from ESUT surroundings, Agbani, around 4.00pm. Plants were identified by Professor J. C. Okafor, a Taxonomist with the Applied Biology and Biotechnology Department, Enugu State University of Science and Technology, Enugu State.

Soxhlet method described by Redfern *et al.*, [14] was used in preparing the extracts.

Animal Studies

Experimental animals used for this research study were apparently healthy adult female Wistar albino rats of about 6 to 8 weeks old with average weight of 150 to 250g. Rats were confirmed as adults following the method described by Lenschow *et al.*, [15]. All the rats were obtained from Faculty of Veterinary Sciences, University of Nigeria, Nsukka (UNN).

Preparation of Monosodium Glutamate (MSG) Solution

The solutions of the MSG given to the animals were prepared following the dissolution of a calculated volume of MSG in a warm water (MSG is sparingly soluble in cold water/water at room temperature but readily soluble in hot water).

Experimental Design

Leiomyoma induction and treatment

Twenty-eight (28) adult female albino Wistar rats were used in this study. Animals were acclimatized for two (2) weeks and divided into four (4) groups of

seven (7) rats each. All animals were fed orally according to the methods described by Wheatley [16].

The negative control group received feed and water only. The positive control group received feed, water and 750mg/kgbw of MSG daily for twenty-eight (28) days. Group III rats received feed, water and 750mg/kgbw of MSG daily for twenty-eight (28) days and later received food, water, 750mg/kgbw of MSG and 250mg/kgbw of aqueous extract of hog plum daily for another twenty-eight (28) days.

Group IV rats had food, water and 750mg/kgbw of MSG daily for first twenty-eight (28) days. In the second twenty-eight (28) days, they were treated with oral ingestion of 250mg/kgbw of aqueous extract of wild sunflower while receiving food, water and 750mg/kgbw of MSG.

Leiomyoma was induced in rats in the positive control, Groups III, and IV following the initial administration of 750mg/kgbw of MSG daily for twenty-eight (28) days. Groups III and IV rats continued to receive MSG with the different extracts in the second twenty-eight (28) days as specified above according to the method described by Cheng *et al.*, [17].

Histopathology procedures carried out on the tissues was according to the method described by Slaoui and Fiette [18]. Sections were stained according to Hematoxylin and Eosin (H&E) technique for general tissue structure. After staining the sections, the slide was mounted with DPX (Diphenyl Phthalate Xylene) and care was taken to avoid air bubbles while mounting the slide. The sections were examined after staining using Olympus Binocular Microscope with in-built lighting system. The sections were later photographed professionally using AmScope Microscope Digital Camera (Model MU500) attached to an eyepiece of microscope.

RESULTS AND DISCUSSION

Photomicrographs of tissues of negative control female albino Wistar rat compared with the positive control.

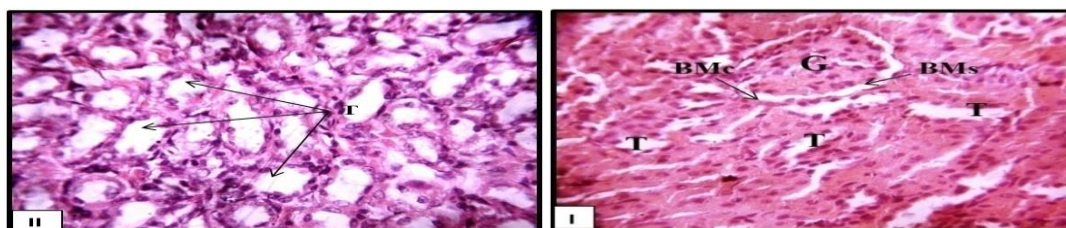


Plate 1: Kidney section photomicrographs from negative control rat showing normal histoarchitecture of the cortex (I) and medullary (II) regions. The glomerulus (G), cortical and medullary tubules (T), Bowman's capsule (BMc) and space (BMs) appear normal. (Stain: H&E; Mag: I&II-x400)

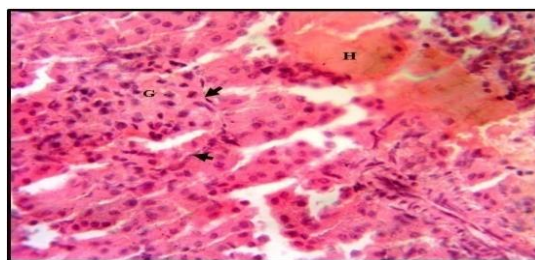


Plate 2: Kidney section photomicrograph from positive control rat after MSG intoxication without treatment. Adhesion of glomerulus (G) to Bowman's capsule (arrow heads) and evidence of haemorrhage (H) are noted. (Stain: H&E; Mag: - x400)

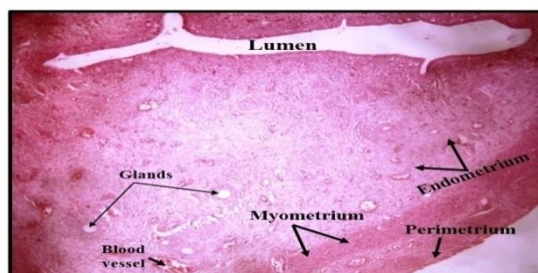


Plate 3: Uterus section photomicrograph from negative control rat showing normal histoarchitecture of the tissue. The perimetrium, myometrium, endometrium bearing the glands, and blood vessels, appear normal (Stain: H&E; Mag: -x100)

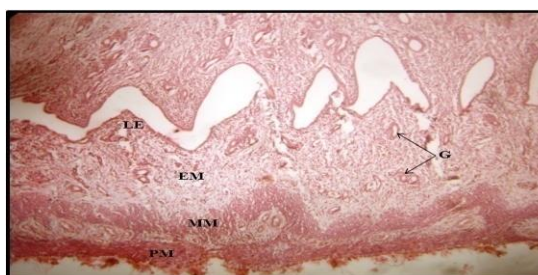


Plate 4: Uterus section photomicrograph from the same negative control rat showing evidence of a moderately preserved histomorphology. The luminal epithelium (LE), endometrium (EM) bearing the glands (G), myometrium (MM) and perimetrium (PM) show no observable abnormality (Stain: H&E; Mag: - x100)

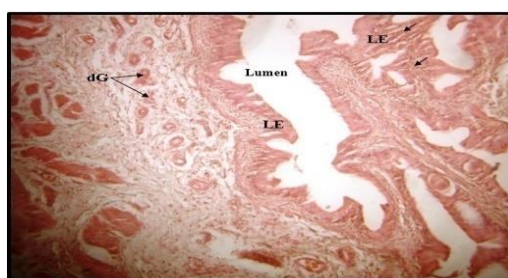

Plate 5: Uterus section photomicrograph from positive control rat shows evidence of hyperplasia of the luminal epithelium (LE), infiltration of inflammatory cells (arrows) and degeneration of endometrial glands (dG). (Stain: H&E; Mag: - x100) Photomicrographs of tissues of Group III female albino Wistar rats treated with water extract of *Spondias mombin* leaves.

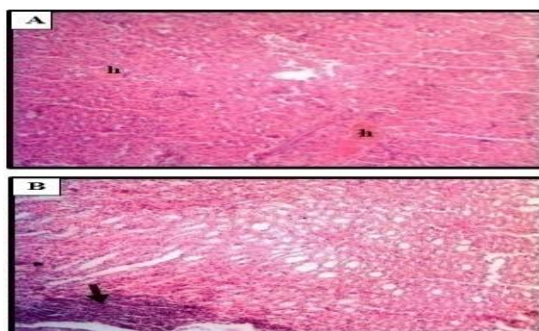


Plate 6: Kidney section photomicrograph from rat treated with 250mg/kgbw of *Spondias mombin* for two weeks following MSG intoxication. The histoarchitecture of the cortical (A) and medullary (B) regions appear intact, however, haemorrhage (h) and marked cellular infiltration (arrow) are observed in the cortex and medulla respectively. (Stain: H&E; Mag:(A) & (B) - x100)

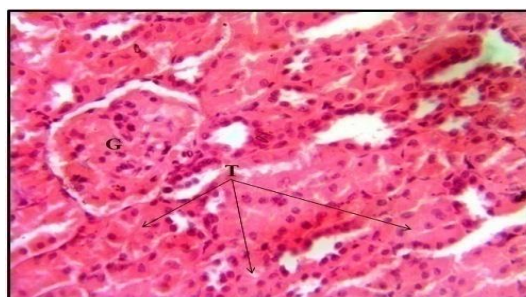

Plate 7: Kidney section photomicrograph from rat treated with 250mg/kgbw of *Spondias mombin* for four weeks following MSG intoxication showing evidence of tissue preservation. The glomerulus (G) and tubules (T) shown appear normal. (Stain: H&E; Mag: - x100)

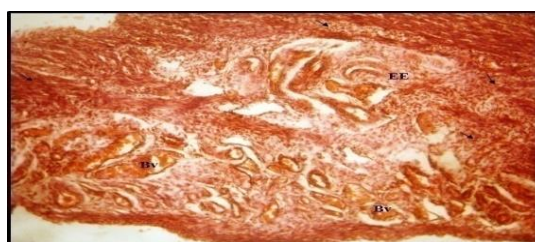

Plate 8: Uterus section photomicrograph from rat treated with 250mg/kgbw of *Spondias mombin* water extract for two weeks following MSG intoxication showing markedly degenerated endometrial epithelium (EE) and inflammatory cellular infiltration (arrows). Most blood vessels (Bv) at the basal region appear congested. (Stain: H&E; Mag: - x100)

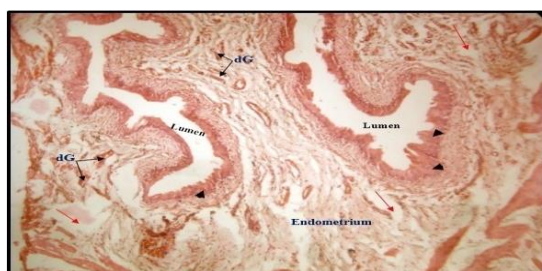

Plate 9: Uterus section photomicrograph from rat treated with 250mg/kgbw of *Spondias mombin* for four weeks following MSG intoxication. The intervening stroma of the endometrium appears degenerated (red arrows), and degenerating glands (dG) are also noted. Mild hyperplasia of the luminal epithelium is also noted (arrow heads). (Stain: H&E; Mag: - x100). Photomicrographs of tissues of Group IV female albino Wistar rats treated with water extract of *Aspilia africana* leaves.

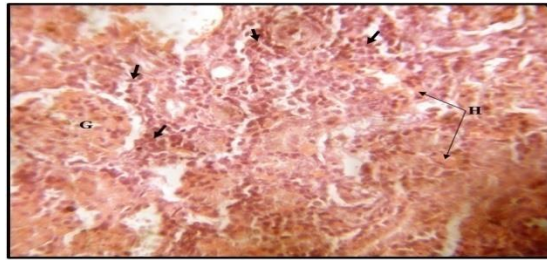


Plate 10: Kidney section photomicrograph from rat treated with 250mg/kgbw of *Aspilia africana* for 2 weeks following MSG intoxication showing distorted tissue parenchyma. The glomerulus (G) appear normal, however, peri-glomerular and peri-tubular regions are invaded by inflammatory cells (arrows). Evidence of haemorrhage (H) and tubular degeneration is also noted. (Stain: H&E; Mag: - x400)

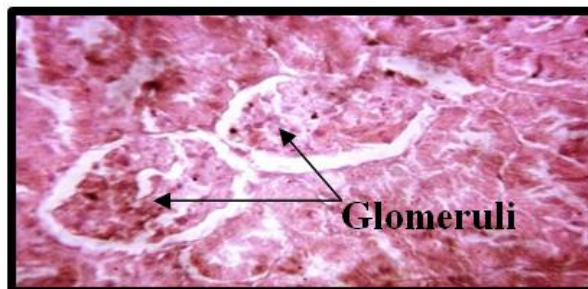


Plate 11: Kidney section photomicrograph from rat treated with 250mg/kgbw of *Aspilia Africana* water extract for four weeks following MSG intoxication and showing mildly constricted glomeruli. (Stain: H&E; Mag: -x400)

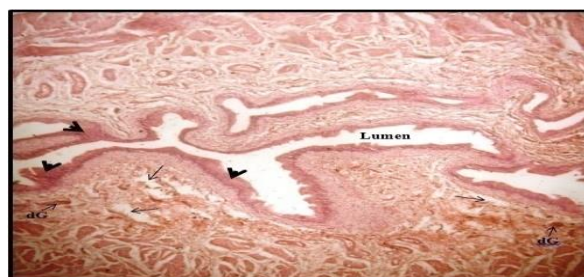

Plate 12: Uterus section photomicrograph from rat treated with 250mg/kgbw of *Aspilia africana* for two weeks following MSG intoxication. Histoarchitectural alteration (arrows) is observed at the apical areas of the endometrium extending to the luminal epithelia, and some of the glands appear to be degenerating (dG). Mild hyperplasia (arrow heads) is also noted in the luminal epithelium. (Stain: H&E; Mag: - x100)

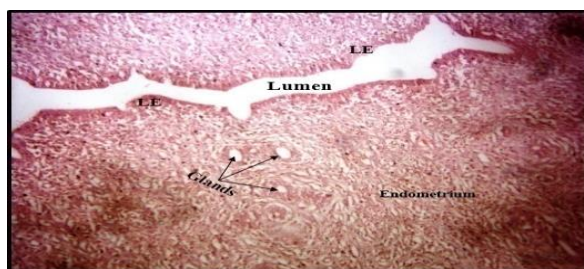


Plate 13: Uterus section photomicrograph from rat treated with 250mg/kgbw of *Aspilia africana* for four (4) weeks following MSG intake. Mild cellular infiltration is observed within the endometrium. However, the endometrial glands and luminal epithelium (LE) appear fairly intact. (Stain: H&E; Mag: - x200)

Photomicrographs of kidney sections of negative control rat show normal histoarchitecture of the kidney cortex (Plate 1) and uterine sections of the same rat (Plates 3 and 4) show normal perimetrium, myometrium, and endometrium with no observable abnormality. The uterine section of the positive control rat (Plate 5) shows evidence of hyperplasia of the

uterine epithelium unlike the negative control rat (Plates 3 and 4). Evidences of tissue degeneration seen in Plates 2 and 5 are indications of the oxidative powers of MSG. Kazmi *et al.*, [19] reported that MSG is toxic to hepatocytes; however this study shows it also causes degeneration of kidney cells and uterine walls (Plates 2 and 5).

Group III rat shows a degenerated endometrial epithelium at two (2) weeks of treatment with *Spondias mombin* aqueous extract (Plate 8). There was mild hyperplasia of the luminal epithelium (Plate 9) at the fourth (4th) week of treatment with *S. mombin* aqueous extract.

Rats' kidney cells at the fourth week of treatment also reported evidence of tissue preservation (Plate 7) compared to the second weeks when there was haemorrhage and marked cellular infiltration (Plate 6).

Plates 12 and 13 are photomicrographs of the uterine sections of Group VI rats for a two (2) weeks and four (4) weeks treatment using *Aspilia africana* aqueous extract, respectively. There was mild hyperplasia of the endometrium (Plate 12) within two weeks of treatment with *A. africana* following MSG ingestion compared with positive control (Plate 5) which shows degeneration of endometrial glands. Continuous treatment with *A. africana* for four weeks indicated that the endometrial glands and the luminal epithelium were fairly intact (Plate 12), though mild cellular infiltration was observed within the epithelium (Plate 13). This is an indicator of a positive improvement to the normal (Plates 4 and 5).

The histopathology examination of two weeks of treatment with *A. africana* following MSG intoxication shows the kidney cells were not spared as evidence of haemorrhage with tubular degeneration (Plate 10) and constricted glomeruli (Plate 11) were observed.

There was haemorrhage and cellular infiltration in week 2 of *Spondias mombin* treatment compared to tissues preservation noted in week 4. Therefore, continuous intake of *S. mombin* aqueous extract preserves kidney cells of rats ingested with MSG (Plates 6 and 7). However, when compared with the endometrial cells of rat's uterus, there were degeneration of the endometrium at 2 weeks and 4 weeks of MSG ingestion (Plates 8 and 9). This is an indication that the intake of *S. mombin* could not preserve the integrity of the rats' endometrium.

Comparing the effects of *S. mombin* intake (Plate 9) with *Aspilia africana* (Plate 13), both at 4 weeks, showed that *A. africana* better preserved the endometrium.

However, at 2 weeks (Plates 8 and 12), both extracts showed no potency in preserving the endometrium and kidney cells (Plates 6 and 10) from the oxidative damage of MSG.

From these results, the management of MSG ingestion with *Aspilia africana* aqueous extract agrees with the findings of Oyesola *et al.*, [20] that it has anti-fertility effect on ovulation in Wistar rats. The work

indicates that the aqueous extracts of *Aspilia africana* and *Spondias mombin* leaves offered protection to the uterine and kidney cells of female Wistar rats induced with leiomyoma. They have anti-fibroid properties hence their usage among local inhabitants.

REFERENCES

- Sharma, A., Prasongwattana, V., Cha'on, U., Selmi, C., Hipkayo, W., Boonnate, P., ... & Puapiroj, A. (2013). Monosodium glutamate (MSG) consumption is associated with urolithiasis and urinary tract obstruction in rats. *PLoS one*, 8(9), e75546.
- World Health Organization/United Nations Environment Programme (WHO/UNEP), Edited by Bergman, Å., Heindel, J. J., Jobling, S., Kidd, K., Zoeller, T. R. (2013). State of the Science of Endocrine Disrupting Chemicals - 2012. An assessment of the state of the science of endocrine disruptors prepared by a group of experts for the United Nations Environment Programme and World Health Organization. *An Inter-Organization Programme for the Sound Management of Chemicals*. 1-289.
- Baird, D. D., Dunson, D. B., Hill, M. C., Cousins, D., & Schectman, J. M. (2003). High cumulative incidence of uterine leiomyoma in black and white women: ultrasound evidence. *American journal of obstetrics and gynecology*, 188(1), 100-107.
- Taylor, D. K., Holthouser, K., Segars, J. H., & Leppert, P. C. (2015). Recent scientific advances in leiomyoma (uterine fibroids) research facilitates better understanding and management. *F1000 Research*, 4(F1000 Faculty Rev).
- Levy, G., Hill, M. J., Beall, S., Zarek, S. M., Segars, J. H., & Catherino, W. H. (2012). Leiomyoma: genetics, assisted reproduction, pregnancy and therapeutic advances. *Journal of assisted reproduction and genetics*, 29(8), 703-712.
- Stewart, E. A., Nicholson, W. K., Bradley, L., & Borah, B. J. (2013). The burden of uterine fibroids for African-American women: results of a national survey. *Journal of women's health*, 22(10), 807-816.
- Ekine, A. A., Lawani, L. O., Iyoke, C. A., Jeremiah, I., & Ibrahim, I. A. (2015). Review of the clinical presentation of uterine fibroid and the effect of therapeutic intervention on fertility. *Am J Clin Med Res*, 3, 9-13.
- Ogunlabi, O. O., Adegbesan, B. O., Sumaoya, O. B., & Ajani, E. O. (2014). Modulating effects of *Allium sativum* (garlic) extract in monosodium glutamate induced injuries in rats. *Medicinal Plants-International Journal of Phytomedicines and Related Industries*, 6(1), 28-35.
- Cemaluk, E. A. C., Madus, E. P., & Nnamdi, O. L. (2010). Influence of sub-chronic oral exposure to high monosodium glutamate on some serum markers of the renal functions in male Wistar

- rats. *African Journal of Biochemistry Research*, 4(9), 225-228.
10. Zia, M. S., Qamar, K., Hanif, R., & Khalil, M. (2014). Effect of monosodium glutamate on the serum estrogen and progesterone levels in female rat and prevention of this effect with diltiazem. *Journal of Ayub Medical College Abbottabad*, 26(1), 18-20.
 11. Sharma, A. (2015). Monosodium glutamate-induced oxidative kidney damage and possible mechanisms: a mini-review. *Journal of biomedical science*, 22(1), 93.
 12. Uchendu, C. N., & Isek, T. (2008). Antifertility activity of aqueous ethanolic leaf extract of *Spondias mombin* (Anacardiaceae) in rats. *African health sciences*, 8(3), 163-167.
 13. Okwu, D. E., & Josiah, C. (2006). Evaluation of the chemical composition of two Nigerian medicinal plants. *African Journal of Biotechnology*, 5(4), 357-361.
 14. Redfern, J., Kinninmonth, M., Burdass, D., & Verran, J. (2014). Using soxhlet ethanol extraction to produce and test plant material (essential oils) for their antimicrobial properties. *Journal of microbiology & biology education*, 15(1), 45.
 15. Lenschow, C., Sigl-Glöckner, J., & Brecht, M. (2017). Development of rat female genital cortex and control of female puberty by sexual touch. *PLoS biology*, 15(9), e2001283.
 16. Wheatley, J. L. (2002). A gavage dosing apparatus with flexible catheter provides a less stressful gavage technique in the rat. *Laboratory Animals*. 31(7): 53 – 56.
 17. Chen, H. G., Lan, Z. H. U., Cui, Q. C., Lang, J. H., & Li, B. (2011). Estrogen induced rat model of uterine leiomyoma. *Zhongguo yi xue ke xue yuan xue bao. Acta Academiae Medicinae Sinicae*, 33(4), 408-411.
 18. Slaoui, M., & Fiette, L. (2011). Histopathology procedures: from tissue sampling to histopathological evaluation. In *Drug Safety Evaluation* (pp. 69-82). Humana Press.
 19. Kazmi, Z., Fatima, I., Perveen, S., & Malik, S. S. (2017). Monosodium glutamate: Review on clinical reports. *International Journal of Food Properties*, 20(sup2), 1807-1815.
 20. TO, O., Oyesola, O. A., & Okoye, C. S. (2010). Effects of aqueous extract of *Aspilia africana* on reproductive functions of female Wistar rats. *Pakistan Journal of Biological Sciences*, 13(3), 126-131.