

## Photographic Assessment of Cephalometric Measurements in Different Malocclusions in Raichur Population-An in Vivo Study

Dr. Sangamesh B<sup>1\*</sup>, Dr. Mogal Bava Nasar<sup>2</sup>, Dr. Vinodh S<sup>3</sup>, Dr. Arshiya Kausar Maniyar<sup>4</sup>

<sup>1</sup>Prof & HOD, <sup>2-4</sup>Post Graduate, Departmen of Orthodontics AME's Dental College & Hospital Raichur, Karnataka India

### \*Corresponding author:

Dr. Sangamesh B

Received: 16.07.2019

Accepted: 15.08.2019

Published: 30.08.2019

**Context:** The present study is to assess the coherence of facial photographs as a viable means for analysis of the soft tissues in orthodontic patients. **Aim:** To assess the repeatability and creditability of measurements obtained from lateral cephalograms and facial photographs. **Methods and Material:** The study was done on standardized lateral cephalograms and facial photographs obtained from a total of 120 patients. An observational collation of linear and angular measurements was formulated between lateral cephalometric radiographs and homologous measurements procured from facial photographs. With patient in ortho position and adhesive dots set on the anatomical landmarks, right profile photographs were captured in NHP. With protractor connecting the tip of the nose and the soft tissue pogonion, a plumb line recorded the NHP angle. Likewise, digital lateral skull radiographs were taken with a PLANMECA and it was analyzed if the same position achieved during photographic record had also been acquired on the radiographic record. Both digital photographic and radiographic records were uploaded into nemoceph 10.4.2 software program for windows and were scrutinized by a single examiner. A total of 19 parameters were analyzed. **Results:** All angular and linear parameter showed statistically insignificant differences. The parameters which showed the mean difference between cephalometric measurements and photogrammetric measurements which is greater than one degree in angular parameters and one mm in linear parameters. **Conclusion:** The photogrammetric analysis can be used as a screening or adjunctive aid in clinical diagnosis.

**Keywords:** Nemoceph, Facial photographs, Lateral cephalograms.

## INTRODUCTION

The overall changes in the facial appearance of young patients undergoing orthodontic treatment occur as a result of both tooth movement as well as growth. Therefore, clinicians need to anticipate the relative contributions of these two factors on the facial changes. Several methods have been used to evaluate facial changes including anthropometry, photogrammetry, cephalometry and more recently computer imaging [1].

Cephalometric radiographs are used in orthodontics to show skeletal discrepancies. Alternatives have been suggested, mainly to reduce radiation exposure. Unnecessary irradiation of patients should be avoided, since there is high threshold dose

(msv=2.4) which may cause biologic damage [2]. Stoner [4] described a method of an

The use of photographs for orthodontic diagnosis and treatment planning needs to be emphasized. Graber stated that the photographs assumes even greater importance when dentists do not have equipment for taking cephalograms, hence consider facial photographs an essential diagnostic tool [3].

Photogrammetry may be defined as the art, science and technology of obtaining reliable information about physical objects through processes of

Quick Response Code



Journal homepage:

<http://crosscurrentpublisher.com/ccijmb/>

**Copyright © 2019 The Author(s):** This is an open-access article distributed under the terms of the Creative Commons Attribution 4.0 International License (CC BY-NC 4.0) which permits unrestricted use, distribution, and reproduction in any medium for non-commercial use provided the original author and source are credited.

DOI: 10.36344/ccijmb.2019.v01i04.003

recording, measuring and interpreting photographic images [4].

In 1955, Stoner described a method of analyzing photographs to evaluate the effect of orthodontic treatment. He developed standards derived from post treatment profile photographs of patients exhibiting excellent form and balance. Neger conducted a similar study using the same landmarks but different reference lines and angles. He compared a group of patients with normal occlusion to patients exhibiting class II division 1, class II, division 2 and class III malocclusions [5].

As cephalometric analysis constitutes the gold standard for diagnosing craniofacial morphology in clinical practice, the possibility of predicting cephalometric values through photographs may be relevant as a non-invasive diagnostic tool. The relationship between craniofacial measurements obtained from cephalometric radiographs and analogous measurements from standardized facial profile photographs by means of regression prediction models shows a consistent relationship between facial overlying tissues and skeletal structures. However, comparisons involving cephalometric and photographic measurements have seldom been performed and conflicting results have been found [6].

Hence, the present study has been conducted to evaluate the reliability and validity of the “Photographic assessment of cephalometric measurements in different malocclusions in Raichur Population”

## MATERIALS AND METHODS

The present study is designed as an observational comparison of linear and angular measurements from standardized lateral cephalometric radiographs with analogous measurements from standardized facial photographs using Nemoceph software. (Version - 10.4.2 software program for windows).

### Study Population

The study participants consisted of patients reporting to department of orthodontics, AMEs Dental College and Hospital during the period from 1-1-2017 to 1-1-2018. Patients seeking orthodontic treatment in the age range 18-30 years were examined. Based on the previous studies and prevalence of malocclusion of Raichur district the sample size was determined to be 120 patients, of the 300 patients examined, 120 patients were recruited who fulfill the inclusion criteria i.e., All six maxillary anterior teeth present. While exclusion criteria were previous orthodontic or surgical treatment, craniofacial trauma, congenital anomalies, Neurologic disturbances, non-cooperative patients.

## PROCEDURE

### PHOTOGRAPHIC EQUIPMENT USED

A digital camera (Nikon 3200) mounted with a macro lens (EF 105 mm f/2.8 OS Macro lens) was used to obtain photographic records.



Fig-2



Fig-3

### Photographic setup



Fig-4

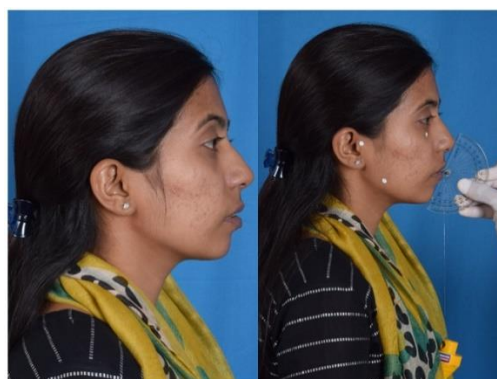

Fig-5: Photographic Procedure

- Standardized right profile photographs taken in the natural head position (NHP), with maximum intercuspation and lips at rest. (Fig 4)
- Adhesive dots placed on anatomic landmarks obtained by palpation. (Fig 5)
- The Me' point identified with an adhesive Styrofoam bead to allow better visibility by the camera.
- Patients will be asking to keep feet slightly apart and arms relaxed and to stand a step behind a line drawn 120 cm from the mirror.
- To achieve the "orthoposition," patients will be instructed to tilt their head up and down with decreasing amplitude until they felt relaxed, take a step forward, and keep looking straight ahead into the reflection of their eyes in the mirror
- A protractor placed on the tip of the nose and the soft tissue pogonion, and a plumb line recorded the NHP angle. (Fig 5)
- The photographic land marks discussed in TABLE 1.

### Photographic Landmarks

**Table-1**

SL. No	Soft Tissue Landmark	Ab	Definition
1.	Soft tissue Glabella	G'	Most prominent or anterior point in mid-sagittal plane of the forehead at the level of the superior orbital ridges
2.	Soft tissue Nasion	N'	Concave or retruded point in the tissue overlying the area of the frontonasal suture
3.	Pronasale	Pn	Most prominent or anterior point of the nose tip
4.	Nasal Tip	NT	Midline point on the nasal tip taken at the level of the dome projecting points of the lower lateral cartilage.
5.	Subnasale	Sn	Point where the lower margin of the nasal septum is confluent with the integumental upper lip.
6.	Soft tissue subspinale	A'	Point of greatest concavity in the midline of upper lip between subnasale(Sn) and labrale superius(Ls).
7.	Labrale superius (upper lip anterior)	UL	Most anterior point on the margin of the upper membranous lip
8.	Superior Labial Sulcus	SLS	Deepest concavity between Sn and ULA
9.	Stomion Superior	Sto	Upper most median point of upper lip when the lips are closed.
10.	Stomion inferior	Sti	Upper most median point of lower lip when the lips are closed
11.	Labrale inferius(Lower lip anterior)	Li	Most anterior point on the margin of the lower membranous lip.
12.	Inferior Labial Sulcus	ILS	Deepest concavity between lower lip vermilion and supra pogonion.
13.	Soft tissue Pogonion	Pog'	Most prominent or anterior points on the soft tissue chin in the midsagittal plane.
14.	Soft tissue Gnathion	Gn'	Midpoint between the most anterior and inferior points of the soft tissue chin in the midsagittal plane.
15.	Soft tissue Menton	Me'	Most inferior point of the soft tissue chin, in the midsagittal plane.
16.	Soft tissue Orbitale	Or'	Lowest point on the inferior orbital rim obtained by palpation.
17.	Tragion	Trg'	The point where the inner crease meets the outer edge at the center of the ear
18.	Soft tissue Gonion	Go'	Analogous to the gonial angle of the mandible, located by palpation

### Radiographic Method

- Digital lateral skull radiographs taken with a PLANMECA. Cephalometric radiographs taken in an NHP with maximum intercuspation and lips at rest (fig no 6).
- The Radiographic land marks discussed in TABLE 2

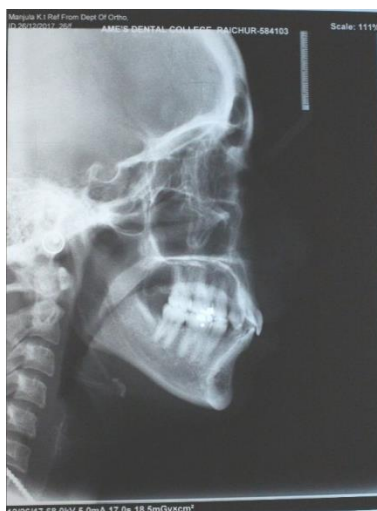

Fig-6

### Radiographic Landmarks

Table-2

SL. No	Soft Tissue Landmark	Ab	Definition
1	Glabella	G'	Most prominent or anterior point in mid-sagittal plane of the forehead at the level of the superior orbital ridges.
2	Nasion	N'	Concave or retruded point in the tissue overlying the area of the frontonasal suture.
3.	Subspinale	A'	Point of greatest concavity in the midline of the upper lip between subnasale (Sn) and labrale superius (Ls).
4.	Pogonion	Pog'	Most prominent or anterior point on the soft tissue chin in the midsagittal plane.
5.	Gnathion	Gn'	Midpoint between the most anterior part and inferior points of the soft tissue chin in the midsagittal plane.
6.	Menton	Me'	Most inferior point of the soft tissue chin, in the midsagittal plane
7.	Gonion	Go'	Analogous to the gonial angle of the mandible, located by palpation.
8.	Sella	S'	Point representing the geometric centre of the pituitary fossa (sella turcica), in the midsagittal plane
9.	Porion	Po'	Most superior point of the outline of the external auditor meatus
10.	Orbitale	Or'	Lowest point on the inferior orbital rim
11.	Anterior Nasal Spine	ANS'	Tip of the bony anterior nasal spine.
13.	Articulare	Ar'	Point of intersection of the images of the posterior border the mandibular ramus and the inferior border of the basilar part of the occipital bone.
14.	Pterygomaxillary fissure	PTM	Most inferior point at the junction of the anterior and posterior borders of the Pterygomaxillary fissure

### Digital (computerized) identification of landmarks

Both digital photographic & radiographic records of the 120 subjects uploaded into nemoceph

10.4.2 software program for windows. The above-mentioned soft tissue & hard tissue land marks were digitally identified by a single examiner.

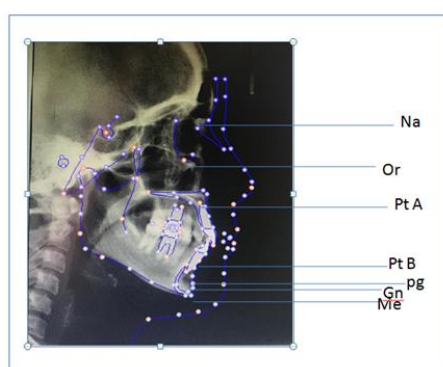


Fig-7

### Computerized assessment of lateral cephalogram and photographs

A total of 19 measurements were carried out using the customized landmarks of which 7 were angular (TABLE 3) and 12 were linear (TABLE 4) measurements.

**Table-3: Angular measurements**

S.No	PHOTO	CEPH
1	FMA	FMA
2	ANB	ANB
3	Facial Angle	Facial Angle
4	Angle of Convexity	Angle of Convexity
5	Gonial Angle	Gonial Angle
6	Occlusal Plane Angle	Occlusal Plane Angle
7	Nasolabial angle	Nasolabial angle

**Table-4: Linear measurements**

S.No	PHOTO	CEPH
1	LAFH	LAFH
2	AFH	AFH
3	PFH	PFH
4	Upper Lip Length	Upper Lip Length
5	Lower Lip Length	Lower Lip Length
6	Upper Lip Protrusion	Upper Lip Protrusion
7	Lower Lip Protrusion	Lower Lip Protrusion
8	Mento Labial sulcus	Mento Labial sulcus
v9	Vertical lip Chin Ratio	Vertical lip Chin Ratio
10	Maxillary Incisor Exposure	Maxillary Incisor Exposure
11	Inter Labial Gap	Inter Labial Gap
12	WITS	WITS

## RESULTS

The standardized lateral cephalograms and standardized profile photographs were obtained from 120 subjects. The present study is designed as an observational comparison of linear and angular measurements from standardized lateral cephalometric radiographs with analogous measurements from standardized facial photographs.

Angular ceph vs photo –manova test-since more than two independent variables are compared with many dependent variables assuming the homogeneous and equal number of patient distribution among the groups-Table-5

### Angular measurements

The FMA of ceph total (23.473°) and FMA of photo total (22.506°) the difference between ceph total and photo total (0.967°) which is less than 1°, hence FMA shows insignificant value. The FMA of ceph male (22.271°) and FMA of photo male (21.751°) the difference between ceph male and photo male (0.52°) which is less than 1°, hence FMA shows insignificant value. The FMA of ceph female (23.968°) and FMA of photo female (22.816°) the difference between ceph female and photo female (1.152°) which is less than 2°, hence FMA shows insignificant value.

The ANB of ceph total (4.118°) and ANB of photo total (4.661°) the difference between ceph total

and photo total (-0.5°) which is less than 1°, hence ANB shows insignificant value. The ANB of ceph male (3.589°) and ANB of photo male (3.591°) the difference between ceph male and photo male (-0.02°) which is less than 1°, hence ANB shows insignificant value. The ANB of ceph female (4.336°) and ANB of photo female (5.101°) the difference between ceph female and photo female (-0.7°) which is less than 1°, hence ANB shows insignificant value.

The facial angle of ceph total (87.840°) and facial angle of photo total (90.221°) the difference between ceph total and photo total (-2.38°) which is less than 1°, hence facial angle shows insignificant value. The facial angle of ceph male (89.171°) and facial angle of photo male (92.326°) the difference between ceph male versus female and photo male versus female (-3.15°) which is less than 1°, hence facial angle shows insignificant value. The facial angle of ceph female (87.292°) and facial angle of photo female (89.354°) the difference between ceph female and photo female (-2.05°) which is less than 1°, hence facial angle shows insignificant value.

The angle of convexity of ceph total (7.075°) and angle of convexity of photo total (7.482°) the difference between ceph total and photo total (-0.40°) which is less than 1°, hence angle of convexity shows insignificant value. The angle of convexity of ceph male (5.260°) and angle of convexity of photo male

(5.260°) the difference between ceph male and photo male (0°) which is less than 1°, hence angle of convexity shows insignificant value. The angle of convexity of ceph female (7.822°) and angle of convexity of photo female (8.398°) the difference between ceph female and photo female (-0.5°) which is less than 1°, hence facial angle shows insignificant value.

The gonial angle of ceph total (116.406°) and the gonial angle of photo total (115.237°) the difference between ceph total and photo total (0.76°) which is less than 1°, hence gonial angle shows insignificant value. The gonial angle of ceph male (117.400°) and the gonial angle of photo male (116.763°) the difference between ceph male and photo male (0.64°) which is less than 1°, hence the gonial angle shows insignificant value. The gonial angle of ceph female (115.996°) and the gonial angle of photo female (114.609°) the difference between ceph female and photo female (1.38°) which is more than 1°, hence gonial angle shows insignificant value.

The occlusal plane angle of ceph total (15.376°) and the occlusal plane angle of photo total (13.160°) the difference between ceph total and photo

total (2.26°) which is more than 1°, hence occlusal plane angle show insignificant value. The occlusal plane angle of ceph male (12.837°) and the occlusal plane angle of photo male (10.843°) the difference between ceph male and photo male (1.99°) which is more than 1°, hence the occlusal plane angle shows insignificant value. The occlusal plane angle of ceph female (16.421°) and the occlusal plane of photo female (14.114°) the difference between ceph female and photo female (2.30°) which is more than 1°, hence occlusal plane show insignificant value.

The nasolabial angle of ceph total (119.532°) and the nasolabial angle of photo total (120.136°) the difference between ceph total and photo total (-0.46°) which is less than 1°, hence nasolabial angle shows insignificant value. The nasolabial angle of ceph male (119.109°) and the nasolabial angle of photo male (120.466°) the difference between ceph male and photo male (-1.33°) which is more than 1°, hence The nasolabial angle shows insignificant value. The nasolabial angle of ceph female (119.706°) and the nasolabial plane of photo female (120.000°) the difference between ceph female and photo female (-0.294°) which is more than 1°, hence nasolabial angle shows insignificant value.

**Table-5: Comparison of angular measurements**

Angular		GENEDER	N(TOTAL )	MEAN	SD	F VALUE	SIGNIF	INFERENCE
FMA	1(CEPH)	1(M)	35	22.271	7.0590			
		2(F)	85	23.968	6.6890			
		TOTAL	120	23.473	6.8132			
	2(PHOTO)	1(M)	35	21.751	7.5160			
		2(F)	85	22.816	5.9923			
		TOTAL	120	22.506	6.4593			
	TOTAL	1(M)	70	22.011	7.2428	2.148	.144	NS
		2(F)	170	23.392	6.3577			
		TOTAL	240	22.990	6.6424			
ANB	1(CEPH)	1(M)	35	3.589	3.5123			
		2(F)	85	4.336	3.2513			
		TOTAL	120	4.118	3.3321			
	2(PHOTO)	1(M)	35	3.591	3.5130			
		2(F)	85	5.101	8.0242			
		TOTAL	120	4.661	7.0322			
	TOTAL	1(M)	70	3.590	3.4871	2.090	.150	NS
		2(F)	170	4.719	6.1159			
		TOTAL	240	4.390	5.4977			
FACIAL ANGLE	1(CEPH)	1(M)	35	89.171	15.4618			
		2(F)	85	87.292	14.3693			
		TOTAL	120	87.840	14.6557			
	2(PHOTO)	1(M)	35	92.326	6.9820			
		2(F)	85	89.354	10.2921			
		TOTAL	120	90.221	9.5152			
	TOTAL	1(M)	70	90.749	12.0144	1.911	.168	NS
		2(F)	170	88.323	12.5039			
		TOTAL	240	89.030	12.3874			
ANGLE OF CONVEXICITY	1(CEPH)	1(M)	35	5.260	7.6318			
		2(F)	85	7.822	6.8716			
		TOTAL	120	7.075	7.1652			
	2(PHOTO)	1(M)	35	5.260	7.6318			
		2(F)	85	8.398	8.7962			
		TOTAL	120	7.482	8.5621			
	TOTAL	1(M)	70	5.260	7.5763	6.588	.011	NS
		2(F)	170	8.110	7.8747			
		TOTAL	240	7.279	7.8807			
GONIAL ANGLE	1(CEPH)	1(M)	35	117.400	10.8456			

		2(F)	85	115.996	9.2006			
		TOTAL	120	116.406	9.6836			
	2(PHOTO)	1(M)	35	116.763	11.1721			
		2(F)	85	114.609	14.6002			
		TOTAL	120	115.237	13.6784			
	TOTAL	1(M)	70	117.081	10.9347	1.113	.293	NS
		2(F)	170	115.303	12.1865			
		TOTAL	240	115.822	11.8402	.360	.549	NS
OCCLUSAL PLANE	1(CEPH)	1(M)	35	12.837	10.0814			
		2(F)	85	16.421	13.7121			
		TOTAL	120	15.376	12.8233			
	2(PHOTO)	1(M)	35	10.843	6.3171			
		2(F)	85	14.114	6.3311			
		TOTAL	120	13.160	6.4750			
	TOTAL	1(M)	70	11.840	8.4115	5.735	.017	NS
		2(F)	170	15.268	10.7106			
	TOTAL	240	14.268	10.1971	2.258	.134	NS	
NASOLABIAL ANGLE	1(CEPH)	1(M)	35	119.109	12.9654			
		2(F)	85	119.706	11.8412			
		TOTAL	120	119.532	12.1276			
	2(PHOTO)	1(M)	35	120.466	13.4235			
		2(F)	85	120.000	15.1033			
		TOTAL	120	120.136	14.5790			
	TOTAL	1(M)	70	119.787	13.1183	.001	.973	NS
		2(F)	170	119.853	13.5312			
	TOTAL	240	119.834	13.3848	.186	.666	NS	

### Linear parameters

Linear ceph vs photo –manova test-since more than two independent variables are compared with many dependent variables assuming the homogeneous and equal number of patient distribution among the groups-Table-6

The LAFH of ceph total (63.507) and LAFH of photo total (64.601) the difference between ceph total and photo total (-1.09) which is less than 1mm, hence LAFH shows insignificant value. The LAFH of ceph male (57.977) and LAFH of photo male (57.980°) the difference between ceph male and photo male (0.003) which is less than 1mm, hence LAFH shows insignificant value. The LAFH of ceph female (65.784) and LAFH of photo female (67.327) the difference between ceph female and photo female (-1.54) which is more than 1mm, hence LAFH shows insignificant value.

The AFH of ceph total (62.973) and AFH of photo total (63.280) the difference between ceph total and photo total (-0.30) which is less than 1mm, hence AFH shows insignificant value. The AFH of ceph male (58.177) and AFH of photo male 57.177) the difference between ceph male and photo male (0.9) which is less than 1mm, hence AFH shows insignificant value. The AFH of ceph female (64.948) and AFH of photo female (65.793) the difference between ceph female and photo female (0.84) which is less than 1mm, hence AFH shows insignificant value.

The PFH of ceph total (44.82) and PFH of photo total (42.09) the difference between ceph total and photo total (2.73) which is more than 1mm, hence PFH shows insignificant value. The PFH of ceph male

(48.30) and PFH of photo male 48.59) the difference between ceph male and photo male (-0.29) which is less than 1mm, hence PFH shows insignificant value. The PFH of ceph female (43.39) and PFH of photo female (43.53) the difference between ceph female and photo female (-0.14) which is less than 1mm, hence PFH shows insignificant value.

The upper lip length of ceph total (19.606) and upper lip length of photo total (19.580) the difference between ceph total and photo total (0.026) which is more than 1mm, hence upper lip length shows insignificant value. The upper lip length of ceph male (18.351) and upper lip length of photo male 18.074) the difference between ceph male and photo male (0.277) which is less than 1mm, hence upper lip length shows insignificant value. The upper lip length of ceph female (20.122) and upper lip length of photo female (20.20) the difference between ceph female and photo female (-0.078) which is less than 1mm, hence upper lip length shows insignificant value.

The lower lip length of ceph total (40.978) and lower lip length of photo total (42.253) the difference between ceph total and photo total (-1.275) which is more than 1mm, hence lower lip length shows insignificant value. The lower lip length of ceph male (38.877) and lower lip length of photo male 38.657) the difference between ceph male and photo male (0.22) which is less than 1mm, hence lower lip length shows insignificant value. The lower lip length of ceph female (41.844) and upper lip length of photo female (42.253) the difference between ceph female and photo female (-0.409) which is less than 1mm, hence lower lip length shows insignificant value.

The upper lip protrusion of cephalometric total (5.37) and upper lip protrusion of photographic total (5.61) the difference between cephalometric total and photographic total (-0.024) which is more than 1mm, hence upper lip protrusion shows insignificant value. The upper lip protrusion of cephalometric male (4.90) and upper lip protrusion of photographic male (5.04) the difference between cephalometric male and photographic male (-0.14) which is less than 1mm, hence upper lip protrusion shows insignificant value. The upper lip protrusion of cephalometric female (5.57) and upper lip protrusion of photographic female (5.84) the difference between cephalometric female and photographic female (-0.078) which is less than 1mm, hence upper lip protrusion shows insignificant value.

The lower lip protrusion of cephalometric total (-6.222) and lower lip protrusion of photographic total (-6.652) the difference between cephalometric total and photographic total (-0.42) which is more than 1mm, hence lower lip protrusion shows insignificant value. The lower lip protrusion of cephalometric male (-5.297) and lower lip protrusion of photographic male (-5.523) the difference between cephalometric male and

photographic male (-0.226) which is less than 1mm, hence lower lip protrusion shows insignificant value. The lower lip protrusion of cephalometric female (-6.604) and lower lip protrusion of photographic female (-7.116) the difference between cephalometric female and photographic female (-0.512) which is less than 1mm, hence lower lip protrusion shows insignificant value.

The mentolabial sulcus of cephalometric total (-4.344) and mentolabial sulcus of photographic total (-4.492) the difference between cephalometric total and photographic total (-0.148) which is more than 1mm, hence mentolabial sulcus shows insignificant value. The mentolabial sulcus of cephalometric male (-4.180) and mentolabial sulcus of photographic male (-3.983) the difference between cephalometric male and photographic male (-0.197) which is less than 1mm, hence mentolabial sulcus shows insignificant value. The mentolabial sulcus of cephalometric female (-4.412) and mentolabial sulcus of photographic female (-4.701) the difference between cephalometric female and photographic female (-0.289) which is less than 1mm; hence mentolabial sulcus shows insignificant value.

#### LINEAR MEASUREMENTS –CEPH VS PHOTO – Table-6

Table-6

LINEAR		GENEDER	N(TOTAL )	MEAN	SD	F VALUE	SIGNIF	INFERENCE
LOWER ANTERIOR FACIAL HEIGHT	1(CEPH)	1(M)	35	57.977	33.1040			
		2(F)	85	65.784	32.0095			
		TOTAL	120	63.507	32.3891			
	2(PHOTO)	1(M)	35	57.980	33.1076			
		2(F)	85	67.327	31.0380			
		TOTAL	120	64.601	31.8024			
	TOTAL	1(M)	70	57.979	32.8650	3.564	.060	NS
		2(F)	170	66.555	31.4436			
		TOTAL	240	64.054	32.0346			
ANT FACIAL HEIGHT	1(CEPH)	1(M)	35	58.177	31.9861			
		2(F)	85	64.948	30.8045			
		TOTAL	120	62.973	31.1720			
	2(PHOTO)	1(M)	35	57.177	32.7706			
		2(F)	85	65.793	30.2883			
		TOTAL	120	63.280	31.1426			
	TOTAL	1(M)	70	57.677	32.1492	3.037	.083	NS
		2(F)	170	65.371	30.4599			
		TOTAL	240	63.127	31.0924			
POSTERIOR FACIAL HEIGHT	1(CEPH)	1(M)	35	48.30	62.451			
		2(F)	85	43.39	19.291			
		TOTAL	120	44.82	37.176			
	2(PHOTO)	1(M)	35	38.59	22.578			
		2(F)	85	43.53	19.402			
		TOTAL	120	42.09	20.407			
	TOTAL	1(M)	70	43.45	46.871	.000	.998	NS
		2(F)	170	43.46	19.290			
		TOTAL	240	43.46	29.956			
UPPER LIP LENGTH	1(CEPH)	1(M)	35	18.351	10.5250			
		2(F)	85	20.122	9.8472			
		TOTAL	120	19.606	10.0375			
	2(PHOTO)	1(M)	35	18.074	12.9541			
		2(F)	85	20.200	10.8629			
		TOTAL	120	19.580	11.4971			
	TOTAL	1(M)	70	18.213	11.7172	1.614	.205	NS
		2(F)	170	20.161	10.3368			
		TOTAL	240	19.593	10.7694			
LOWER LIP LENGTH	1(CEPH)	1(M)	35	38.877	22.2944			
		2(F)	85	41.844	17.9972			
		TOTAL	120	40.978	19.2997			
	2(PHOTO)	1(M)	35	38.657	23.0574			
		2(F)	85	42.253	18.2169			
		TOTAL	120	41.204	19.7191			
	TOTAL	1(M)	70	38.767	22.5145	1.399	.238	NS
		2(F)	170	42.048	18.0549			
		TOTAL	240	41.091	19.4700			
						.001	.973	NS



UPPER LIP PROTRUSION	1(CEPH)	1(M)	35	4.90	4.111			
		2(F)	85	5.57	3.769			
		TOTAL	120	5.37	3.867			
	2(PHOTO)	1(M)	35	5.04	5.352			
		2(F)	85	5.84	4.068			
		TOTAL	120	5.61	4.472			
	TOTAL	1(M)	70	4.97	4.737	1.541	.216	NS
		2(F)	170	5.71	3.912			
		TOTAL	240	5.49	4.173			
LOWER LIP PROTRUSION	1(CEPH)	1(M)	35	-5.297	6.0402			
		2(F)	85	-6.604	4.4032			
		TOTAL	120	-6.222	4.9462			
	2(PHOTO)	1(M)	35	-5.523	6.5759			
		2(F)	85	-7.116	4.4075			
		TOTAL	120	-6.652	5.1572			
	TOTAL	1(M)	70	-5.410	6.2689	4.120	.043	NS
		2(F)	170	-6.860	4.3998			
		TOTAL	240	-6.437	5.0468			
MENTOLABIAL SULCUS	1(CEPH)	1(M)	35	-4.180	3.3048			
		2(F)	85	-4.412	3.5259			
		TOTAL	120	-4.344	3.4507			
	2(PHOTO)	1(M)	35	-3.983	3.5924			
		2(F)	85	-4.701	3.4960			
		TOTAL	120	-4.492	3.5245			
	TOTAL	1(M)	70	-4.081	3.4279	.917	.339	NS
		2(F)	170	-4.556	3.5036			
		TOTAL	240	-4.418	3.4813			

## DISCUSSION

Diagnosis is the key for success in any therapeutic and clinical procedures of orthodontics. The skeletal discrepancies are viable through cephalometric radiographs. Cephalometric radiographs are the special and supplemental aids in clinical diagnosis. Cephalometric radiographs are considered as important tools in diagnosis which are relatively non-invasive but have their limitations.

If the radiation dose is low and it is delivered over a long period (e.g., decades), the risk is substantially lower because the body gets time to repair the structural and functional damage. However, even at low doses, there remains a risk of long-term effects such as cancer. The risk is higher for children and adolescents due to the growth potential hence are more sensitive to radiation exposure. Health advisory boards have advised the use of the ALARA principle (As Low As Reasonably Achievable) for all dental radiographs.

The concern on radioprotection made researchers to rediscover alternative methods to detect skeletal skull morphology without radiographs. The various alternative methods include a 3-D digital system based on sonic signals, three-dimensional anthropometry and infrared photogrammetry (computerized anthropometry). The alternative methods are unfeasible as their equipment's are not readily available in office for chair-side measurements.

The photogrammetric analysis is used to describe the soft-tissue profile of patients by using linear and angular measurements from profile photographs. Quantitative analyses of the soft-tissue profile showed the influence of the various classes of malocclusion and in particular, they were used to measure the influence of orthodontic treatment on facial

esthetics. Photographic profile analysis can be useful in orthodontic treatment planning.

Reidel [33] suggested the relationship between soft tissue profile and skeletal profile. Subtelny<sup>33</sup> in his longitudinal study of soft tissue profiles concluded that soft tissue profile directly follows the underlying skeletal structures to a great extent. Bennett's [33] study of variations in the soft tissue profile and their relevance to the clinical assessment of skeletal pattern added much more importance for the reliability of soft tissue over the underlying skeletal discrepancies.

### Reliability and validity of our procedure

In the present study evaluation of cephalometric analysis and measurements of the soft tissue parameters had been analyzed digitally. The software used for digital cephalometric analysis was Nemoceph software (Version - 10.4.2 software program for windows). This digital method of cephalometric evaluation can be correlated with the manual method. Chen *et al.* [34] proved the reliability of digital method over the conventional cephalometric analysis with standard deviation of less than 2 units (degree/mm). A similar result was obtained by Alok *et al.* [35] while assessing a reliability and accuracy of manual and digital lateral cephalometric tracing.

The standardized photographs in NHP were taken with 105mm macro lens with maximum intercuspation and relaxed lip position. The NHP was obtained with a protractor placed on the tip of the nose and the soft tissue pogonion, and a plumb line recorded the NHP angle. An additional measure was taken to attain a NHP by tilting their head up and down with decreasing amplitude until they felt relaxed, take a step forward, and keep looking straight ahead into the reflection of their eyes in the mirror. This procedure was followed to obtain NHP due to the possibility of

error in the photogrammetric values with a small deviation in the NHP. The guidelines for NHP followed are similar to the method described by Gomes *et al.* [32].

#### Discussion with clinical significance

All angular parameters showed statistically insignificant differences. The parameters which showed

the mean difference between cephalometric measurement and photogrammetric measurements which is  $>1^\circ$  are occlusal plane angle, nasolabial angle and facial angle. Hence clinical diagnosis of occlusal plane angle, nasolabial angle and facial angle only by photographic assessment can be inappropriate.

#### Difference in mean angular measurements –Male sample

**Table-7**

S.No	Parameter	Ceph	Photo	Difference
1.	Occlusal plane angle	12.837°	10.843°	1.99°
2.	Nasolabial angle	119.109°	120.466°	-1.33°
3.	Facial angle	89.171°	92.326°	-3.15°

All linear parameters showed statistically insignificant differences. Few parameters which showed the mean difference between cephalometric measurement and photogrammetric measurements

which is  $>1\text{mm}$  are maxillary incisor exposure and inter labial gap. Hence clinical diagnosis of maxillary incisor exposure and inter labial gap only by photographic assessment can be inappropriate.

#### Difference in mean linear measurements –Male sample

**Table-8**

S.No	Parameter	Ceph	Photo	Difference
1.	Maxillary incisor exposure	2.489	3.60	-1.1
2.	Interlabial gap	4.403	6.631	-2.228

All angular parameters showed statistically insignificant differences. The parameters which showed the mean difference between cephalometric measurement and photogrammetric measurements

which is  $>1^\circ$  are occlusal plane angle, nasolabial angle and facial angle. Hence clinical diagnosis of occlusal plane angle, nasolabial angle and facial angle only by photographic assessment can be inappropriate.

#### Difference in mean angular measurements –Female sample

**Table-9**

S. No	Parameter	Ceph	Photo	Difference
1.	Occlusal plane angle	16.421°	14.114°	2.30°
2.	Nasolabial angle	119.109°	120.466°	-1.33°
3.	Facial angle	87.292°	89.354°	-2.05°

All linear parameters showed statistically insignificant differences. The parameters which showed the mean difference between cephalometric measurement and photogrammetric measurements

which is  $>1\text{mm}$  are inter labial, wits and lower anterior facial height. Hence clinical diagnosis of inter labial gap, wits and lower anterior facial height only by photographic assessment can be inappropriate.

#### Difference in mean linear measurements –Female sample

**Table-10**

S.No	Parameter	Ceph	Photo	Difference
1.	Interlabial gap	6.796	5.825	0.971
2.	WITS	-5.085	-5.253	-0.971
3.	LAFH	65.784	67.327	-1.54

All parameters showed statistically insignificant differences. Few parameters which showed the mean difference between cephalometric measurement and photogrammetric measurements

which is  $>1^\circ$ . They are occlusal plane angle and facial angle. Clinical diagnosis of occlusal plane angle and facial angle only by photographic assessment can be inappropriate.

**Difference in mean angular measurements –Total sample****Table-11**

S.No	Parameter	Ceph	Photo	Difference
1.	Occlusal plane angle	15.376°	13.16°	2.26°
2.	Facial angle	87.84°	90.221°	-2.38°

All the linear parameters showed statistically insignificant differences. The parameters which showed the mean difference between cephalometric measurements and photogrammetric measurements >1mm are posterior facial height, interlabial gap, lower

anterior facial height and lower lip length. Hence clinical diagnosis of posterior facial height, interlabial gap, lower anterior facial height and lower lip length only by photographic assessment can be inappropriate.

**Difference in mean linear measurements –Total sample****Table-12**

S.No	Parameter	Ceph	Photo	Difference
1.	PFH	44.82	42.09	2.73
2.	Interlabial gap	7.476	-5.073	2.403
3.	LAFH	63.507	64.601	-1.09
4.	Lower lip length	40.978	42.253	-1.275

**Clinical significance of the study**

The reliability of the photographic method is excellent as the facial landmarks located consistently. Our results concur with all the previous articles referred in the review of literature where its mentioned that facial photography as reliable as cephalometric radiography. Caution is advised when landmarks with underlying excessive soft tissues measured. Hence as these variations in soft tissue and bony landmark locations have clinical implications, facial photography always considered as adjunct to cephalometric diagnosis rather than a replacement diagnostic tool. We also agree to the conclusion of other authors that the future application of photography could be in epidemiological surveys or studies involving large samples requiring reproducible methods of parametric evaluation.

**CONCLUSIONS**

The angular and linear measurements are clinically and statistically correlating between analogous photometric and cephalometric measurements.

The soft tissue measurements with excessive thickness, occlusal plane and facial angle and posterior facial height are showing considerable variations. Hence all the 19 parameters cannot be considered as reliable on photographic assessment.

Photogrammetric analysis can be used as a screening or adjunctive aid in clinical diagnosis. Photogrammetry can use as an excellent tool in large scale epidemiological surveys to assess skeletal and soft tissue malocclusion.

**REFERENCE**

1. Bishara, S. E., Jorgensen, G. J., & Jakobsen, J. R. (1995). Changes in facial dimensions assessed from lateral and frontal photographs. Part I–Methodology. *American Journal of Orthodontics and Dentofacial Orthopedics*, 108(4), 389-393.
2. Zhang, X., Hans, M. G., Graham, G., Kirchner, H. L., & Redline, S. (2007). Correlations between cephalometric and facial photographic measurements of craniofacial form. *American journal of orthodontics and dentofacial orthopedics*, 131(1), 67-71.
3. de Carvalho Rosas Gomes, L., Horta, K. O. C., Gandini Jr, L. G., Gonçalves, M., & Gonçalves, J. R. (2013). Photographic assessment of cephalometric measurements. *The Angle Orthodontist*, 83(6), 1049-1058.
4. Chadwick, R. G. (1992). Close range photogrammetry—a clinical dental research tool. *Journal of dentistry*, 20(4), 235-239.
5. Bishara, S. E., Cummins, D. M., Jorgensen, G. J., & Jakobsen, J. R. (1995). A computer assisted photogrammetric analysis of soft tissue changes after orthodontic treatment. Part I: methodology and reliability. *American Journal of Orthodontics and Dentofacial Orthopedics*, 107(6), 633-639.
6. Staudt, C. B., & Kiliaridis, S. (2009). A nonradiographic approach to detect Class III skeletal discrepancies. *American Journal of Orthodontics and Dentofacial Orthopedics*, 136(1), 52-58.
7. Stoner, M. M. (1955). A photometric analysis of the facial profile: A method of assessing facial change induced by orthodontic treatment. *American Journal of Orthodontics and Dentofacial Orthopedics*, 41(6), 453-469.

8. Peck H, Peck S. A concept of facial esthetics. *The Angle Orthodontist*. 1970 Oct;40(4):284-317.
9. Holdaway, R. A. (1983). A soft-tissue cephalometric analysis and its use in orthodontic treatment planning. Part I. *American journal of orthodontics*, 84(1), 1-28.
10. Arnett, G. W., & Bergman, R. T. (1993). Facial keys to orthodontic diagnosis and treatment planning. Part I. *American journal of orthodontics and dentofacial orthopedics*, 103(4), 299-312.
11. Peerlings, R. H., Kuijpers-Jagtman, A. M., & Hoeksma, J. B. (1995). A photographic scale to measure facial aesthetics. *European Journal of Orthodontics*, 17(2), 101-109.
12. Bishara, S. E., Jorgensen, G. J., & Jakobsen, J. R. (1995). Changes in facial dimensions assessed from lateral and frontal photographs. Part II—Results and conclusions. *American Journal of Orthodontics and Dentofacial Orthopedics*, 108(5), 489-499.
13. Cummins, D. M., Bishara, S. E., & Jakobsen, J. R. (1995). A computer assisted photogrammetric analysis of soft tissue changes after orthodontic treatment: Part II results. *American Journal of Orthodontics and Dentofacial Orthopedics*, 108(1), 38-47.
14. Bishara, S. E., Jakobsen, J. R., Hession, T. J., & Treder, J. E. (1998). Soft tissue profile changes from 5 to 45 years of age. *American Journal of Orthodontics and Dentofacial Orthopedics*, 114(6), 698-706.
15. Fernández-Riveiro, P., Suárez-Quintanilla, D., Smyth-Chamosa, E., & Suárez-Cunqueiro, M. (2002). Linear photogrammetric analysis of the soft tissue facial profile. *American journal of orthodontics and dentofacial orthopedics*, 122(1), 59-66.
16. Fernández-Riveiro, P., Smyth-Chamosa, E., Suárez-Quintanilla, D., & Suárez-Cunqueiro, M. (2003). Angular photogrammetric analysis of the soft tissue facial profile. *The European Journal of Orthodontics*, 25(4), 393-399.
17. Douglas, T. S. (2004). Image processing for craniofacial landmark identification and measurement: a review of photogrammetry and cephalometry. *Computerized Medical Imaging and Graphics*, 28(7), 401-409.
18. Dimaggio, F. R., Ciusa, V., Sforza, C., & Ferrario, V. F. (2007). Photographic soft-tissue profile analysis in children at 6 years of age. *American Journal of Orthodontics and Dentofacial Orthopedics*, 132(4), 475-480.
19. Zhang, X., Hans, M. G., Graham, G., Kirchner, H. L., & Redline, S. (2007). Correlations between cephalometric and facial photographic measurements of craniofacial form. *American journal of orthodontics and dentofacial orthopedics*, 131(1), 67-71.
20. Malkoç, S., Demir, A., Uysal, T., & Canbuldu, N. (2008). Angular photogrammetric analysis of the soft tissue facial profile of Turkish adults. *The European Journal of Orthodontics*, 31(2), 174-179.
21. Rhee, S. C., Dhong, E. S., & Yoon, E. S. (2009). Photogrammetric facial analysis of attractive Korean entertainers. *Aesthetic plastic surgery*, 33(2), 167.
22. Ozdemir, S. T., Sigirli, D., Ercan, I., & Cankur, N. S. (2009). Photographic facial soft tissue analysis of healthy Turkish young adults: anthropometric measurements. *Aesthetic plastic surgery*, 33(2), 175-184.
23. Aksu, M., Kaya, D., & Kocadereli, I. (2010). Reliability of reference distances used in photogrammetry. *The Angle Orthodontist*, 80(4), 670-677.
24. Anić-Milošević, S., Meštrović, S., Lapter-Varga, M., Dumančić, J., & Šljaj, M. (2010). Analysis of the soft tissue profile in Croats with normal occlusions and well-balanced faces. *The European Journal of Orthodontics*, 33(3), 305-310.
25. Reddy, M., Ahuja, N. K., Raghav, P., Kundu, V., & Mishra, V. (2011). A computer-assisted angular photogrammetric analysis of the soft tissue facial profile of North Indian adults. *Journal of Indian Orthodontic Society*, 45(3), 119-123.
26. Gode, S., Tiris, F. S., Akyildiz, S., & Apaydin, F. (2011). Photogrammetric analysis of soft tissue facial profile in Turkish rhinoplasty population. *Aesthetic plastic surgery*, 35(6), 1016-1021.
27. Ferdousi, M. A., Al Mamun, A., Banu, L. A., & Paul, S. (2013). Angular photogrammetric analysis of the facial profile of the adult Bangladeshi garo. *Advances in Anthropology*, 3(04), 188.
28. Patel, D. P., & Trivedi, R. (2013). Photography versus lateral cephalogram: Role in facial diagnosis. *Indian Journal of Dental Research*, 24(5), 587.
29. Asghari, A., Rajaeih, S., Hassannia, F., Tavakolifard, N., Neisyani, H. F., Kamrava, S. K., & Omidian, P. (2014). Photographic facial soft tissue analysis of healthy Iranian young adults: anthropometric and angular measurements. *Medical journal of the Islamic Republic of Iran*, 28, 49.
30. Diouf, J. S., Ngom, P. I., Fadiga, M. S., Badiane, A., Diop-Ba, K., Ndiaye, M., & Diagne, F. (2014). Vertical photogrammetric evaluation of the soft tissue profiles of two different racial groups: a comparative study. *International orthodontics*, 12(4), 443-457.
31. Duggal, S., Kapoor, D. N., Verma, S., Sagar, M., Lee, Y. S., Moon, H., & Rhee, S. C. (2016). Photogrammetric analysis of attractiveness in Indian faces. *Archives of plastic surgery*, 43(2), 160.
32. Dimaggio, F. R., Ciusa, V., Sforza, C., & Ferrario, V. F. (2007). Photographic soft-tissue profile analysis in children at 6 years of age. *American Journal of Orthodontics and Dentofacial Orthopedics*, 132(4), 475-480.

33. Barnett, D. P. (1975). Variations in the soft tissue profile and their relevance to the clinical assessment of skeletal pattern. *British journal of orthodontics*, 2(4), 235-238.
34. Chen, Y. J., Chen, S. K., Chung-Chen Yao, J., & Chang, H. F. (2004). The effects of differences in landmark identification on the cephalometric measurements in traditional versus digitized cephalometry. *The Angle orthodontist*, 74(2), 155-161.
35. Shah, A. R., Karandikar, G., Ravindranath, V., Sonawane, M., & Mhatre, A. (2016). A comparative study of reliability and accuracy of manual and digital lateral cephalometric tracing. *J Contemp Dent*, 6(1), 15-18.