

Case Report

A Case Report of Three Port Management of Zinner Syndrome

Dr. Morampudi Sarvani^{1*}, Dr. A Siva Sai Bharadwaja², Dr. Kalidindi Kalyan Chakravarthi³, Dr. Basa Maruti⁴, Dr. Morampudi Lokendra Venkata Prasad⁵

¹Consultant General Surgeon, Gastroenterology Unit, Andhra Hospital, Eluru, Andhra Pradesh, India

²Consultant Urologist, Andhra Hospital, Eluru, Andhra Pradesh, India

³Anaesthesiologist and Critical Care Specialist, Andhra Hospital, Eluru, Andhra Pradesh, India

⁴Consultant General Surgeon, Gastroenterology Unit, Andhra Hospital, Vijayawada, Andhra Pradesh, India

⁵Director and Chief Consultant General Surgeon, Gastroenterology Unit, Andhra Hospital Eluru, Andhra Pradesh, India

Article History

Received: 21.03.2022

Accepted: 25.04.2022

Published: N/A

Journal homepage:

<https://www.easpublisher.com>

Quick Response Code



Abstract: A peculiar case of ischuria secondary to Zinner syndrome. A complete excision via laparoscopic approach given a 100 percent symptomatic relief is a safe and effective. Symptomatic congenital cysts require an appropriate management.

Case Description: Case of 21 years male presented in urology unit with features of obstructive uropathy, acute urinary retention and severe lower abdominal pain on evaluation found to have left kidney agenesis and left seminal vesical cyst [1]. A Three port laparoscopic transperitoneal approach performed and left side seminal vesical cyst removal done. The peritoneum was incised between the bladder and the rectum to reveal the left seminal vesicle, which was resected from the surrounding tissue and removal of the cyst done.

Discussion: Aim of the study was to show the advancement and usefulness of the laparoscopic approach with short hospital stay and painless procedure, minimal blood loss. Procedure lasted for 60 mins. Unrecordable post intraoperative complications. Patient had been discharged after 36 hours after the procedure, on follow up patient is asymptomatic for 24 months of the procedure. Symptomatic Zinner syndrome with appropriate identification and laparoscopic approach and magnified view better than open and other invasive techniques should be a method of choice in treatment of the congenital seminal vesical cyst and currently a golden surgical standard.

Keywords: Zinner, Port Management, Congenital

Copyright © 2022 The Author(s): This is an open-access article distributed under the terms of the Creative Commons Attribution **4.0 International License (CC BY-NC 4.0)** which permits unrestricted use, distribution, and reproduction in any medium for non-commercial use provided the original author and source are credited.

INTRODUCTION

A rare congenital Zinner syndrome was first described in the year 1941 [2] representing the triad of renal agenesis associated with ipsilateral seminal vesicle cysts [1], an ectopic ureter opening into the seminal vesicle, and obstruction of the ejaculatory duct is a Wolffian duct anomaly known as the Zinner syndrome. Till date more than 300 cases have been reported in the literature estimated prevalence of 0.0001%. This syndrome is generally asymptomatic; it may cause symptoms like perineal pain, painful ejaculation, hematospermia, abnormal micturition, lower urinary tract symptoms and acute urinary dysuria.

CASE REPORT

A 21 year male patient who was recently married, was asymptomatic till 3 months ago. He later developed intermittent pain in the lower abdomen associated with difficult and scanty micturition urgency, fever and constipation. Observed acute ischuria since a day. On examination there was a mass palpable in the supra pubic region occupying till umbilical region. Digital rectal examination revealed a full bladder. External genitalia normal on both sides. Foley's catheterization was unsuccessful. Cystoscopy was performed under short general anaesthesia revealed a large cystic lesion of size 7 x 8 cms occupying from the left bladder. Ultrasound was done showing a right side solitary kidney with congenital agenesis left kidney. Abdominal and pelvis magnetic resonance imaging was then performed, which confirmed a left renal agenesis. Furthermore, epididymal enlargement in the body and tail was evident. The vas deferens

*Corresponding Author: Dr. Morampudi Sarvani

Consultant General Surgeon, Gastroenterology Unit, Andhra Hospital, Eluru, Andhra Pradesh, India

was also dilated up until the most cranial portion, where it was absent for 6 cms. It was again irregularly dilated in the pre-terminal portion, leading to a large cyst in the left seminal vesicle (5.8 cms in diameter).

In view of all the above findings, MRI Scan and clinical examination revealed Zinner syndrome. Hence a laparoscopic transperitoneal approach and excision of tumour was planned.

Surgery

This procedure was performed through minimally invasive laparoscopically transperitoneal approach. Patient was placed in Lithotomy Trendelenburg position (25 degree), and a catheter was placed into the bladder. Veress needle introduced at the level of umbilicus and pneumoperitoneum creation done later 5 mm port placed and telescope introduction done. Three trocars were placed. First 5mm port was placed at the level of umbilicus for the introduction of the camera using 30 degrees telescope. Another 5mm port was placed right side of abdomen in between right iliac crest and umbilical port. Other 5 mm port was placed mid-way between the left iliac crest and umbilical for checking on left side of abdomen.

Cystoscopy was introduced into the bladder and swelling was identified occupying left side of the bladder and also observed that neck was narrowed. Also detected that left side of ureter was dilated.

The first stage of treatment involved lifting the urinary bladder to reveal the vesicorectal recess. The peritoneum was then incised between the bladder and the rectum retroperitoneal space. Retrograde dissection was performed above the iliac vessels. Seminal vesicles were excised using bipolar. Simultaneously Cystoscopy was performed. Bulge was identified via laparoscopy and cystoscopy. Complete excision of cyst was performed and dark colour fluid was drained out. Base of the cyst was identified and sutured. Specimen was retrieved and drain was placed on left side. He had been discharged two days after the surgery. No other complications had been detected in the patient. Histopathological report stated that the cyst was seminal vesical origin.

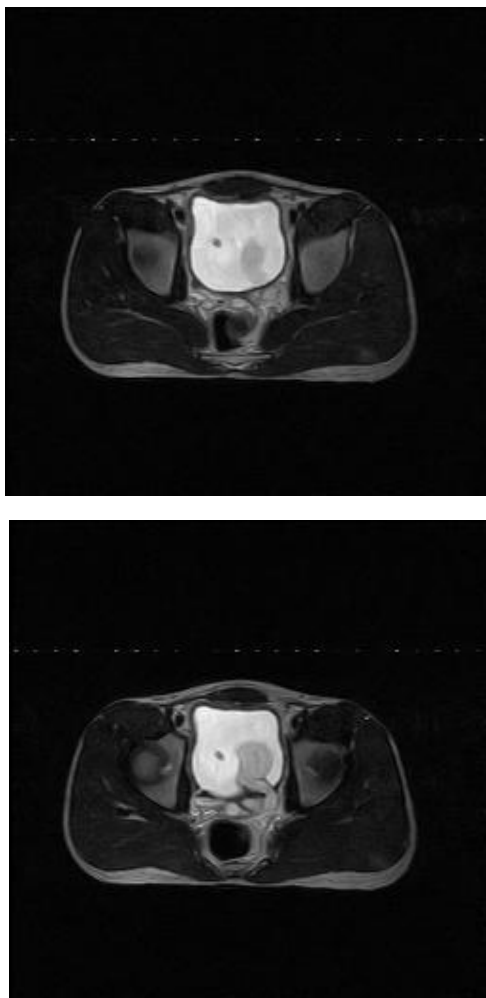


Figure 1 & 2: MRI imaging of left seminal vesical cyst

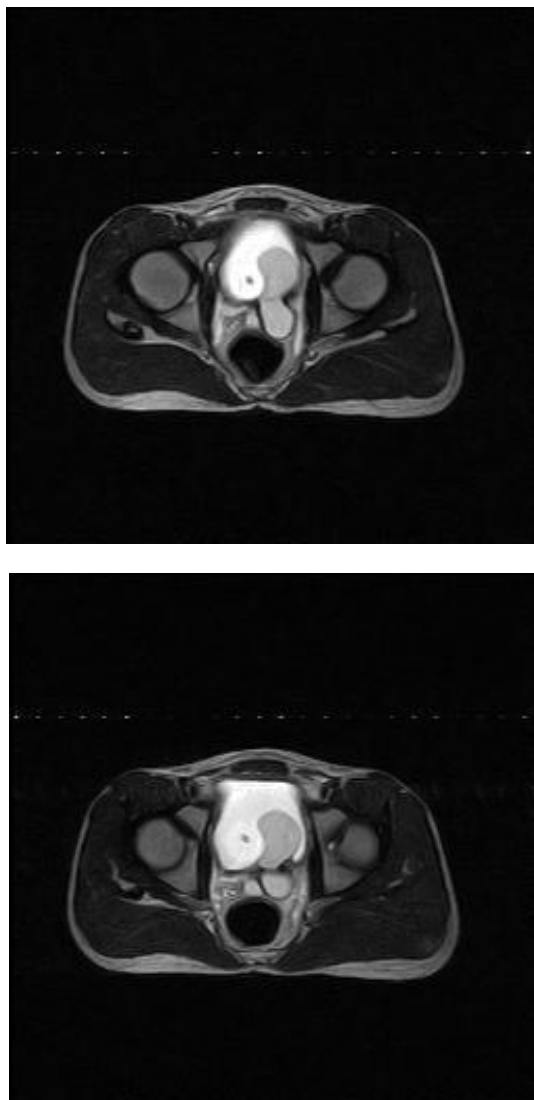


Figure 3 & 4: MRI imaging of left seminal vesical cyst obstructing the bladder neck

DISCUSSION

Zinner syndrome is a rare congenital malformation associated with seminal vesical cyst with ipsilateral renal agenesis and an ejaculatory duct obstruction. The ipsilateral ureter can be absent or incomplete or may have abnormal course towards seminal vesicle [1]. Seminal vesicle cysts were first identified in 1872 by Smith, first described by Zinner in 1914 [2].

It is usually diagnosed in 2nd and 3rd decade of life [3]. Symptoms of dysuria (37%), frequency (33 %), perineal pain in (29 %), epididymitis noted in 27%. In females it is considered as Mayer-Rokitansky-Kuster-Hausers. The frequency of this condition is reported to be 0.0046% according to Farooqui *et al*. Till now only 200 cases had been reported in the literature it's a rare congenital anomaly.

Mesonephric duct or wolffian duct plays an important role in the development of the urogenital system between 4-13 weeks of embryogenesis. Both mesonephros and mesonephric duct development occur during fourth week of fetal life, forming the primitive mesonephric renal corpuscle. In female this corpuscle involutes completely during the second month, whereas in males it persists partially, participating in the formation of the genital system. The most distal part of the duct forms an outgrowth called ureteric bud. This structure will finally form the metanephros, definitive kidney. Maldevelopment of the distal mesonephric duct absence of ureteric bud insufficient drainage causing cystic dilatation of seminal vesicles which is termed as Zinner syndrome.

The dilatation of the seminal vesicles may be small and asymptomatic in few cases. Cysts greater than 5 cms required surgical management.

Unilateral renal agenesis is observed in approximately 0.1% of population, bilateral renal agenesis occurs in 1 in 3000 to 4000 of new-borns. This syndrome is usually asymptomatic. A ureterocele or seminal vesical cyst can grow and induce inflammation and stimulate the surrounding viscera. It results in bladder-irritating symptoms, including urinary frequency, dysuria, suprapubic pain, hematospermia [4, 5], and painful ejaculation supra pubic pain. In our patient, the symptoms were perineal, acute urinary retention with supra pubic pain and distention, which had been reported as most common indication for surgery [6, 7].

Diagnostic methods like transrectal ultrasonography provide a high accuracy imaging in thin individuals. Both endorectal ultrasonography and abdominopelvic ultrasound can pick up large tumours in thin individuals. In obese patients CT and MRI are used for identification and conformation of the cystic lesion. MRI excludes other pelvic lesions. CT and MRI [8] are used to identify and assess characteristic feature and nature of the cyst.

One of the studies showed the introduction of the Vaso seminal vesiculography and transperineal puncture of the size of the cyst with septations is detected [9].

Treatment is decided according to the symptoms. Mild symptoms are percutaneous drainage, transurethral aspiration or transrectal aspiration of seminal vesical cyst. Poor therapeutic procedures which had an ineffective outcome with high chances of recurrence.

Open procedure was once up on a time gold standard. Open surgery performed through a transvesical, retrovesical, transperineal, or trans coccygeal route has been considered as the definitive treatment option because of the high success rate, but the related morbidity is also considerable. But difficult in accessibility due to location of the seminal vesicles beneath the bladder and there is possibility of damage to the bladder and rectum.

However, these approaches were reported to have poor therapeutic effects with a high probability of recurrence and the exposure of a young patient to the possible need to repeat the procedure. Laparoscopic surgery has advantages of direct access to the seminal vesicles and most advanced treatment. Carmignani *et al*. [10] had been described as the first laparoscopic excision of the seminal vesical cyst associated with the ipsilateral renal agenesis.

Approaching of the cyst through the vesico rectal recess was described by Kavoussi *et al*. in the year 1993 [11]. Seo *et al*. [12] described a 4-port technique in his study for laparoscopic removal of the seminal vesical cyst in his study. In our technique only three 5 mm ports have been placed for the removal of the cyst. The view of the surgical field was perfect and much better than the open approach. Till date only 20 cases have been reported in the literature. Laparoscopically the approach is very clearly visualised, and anatomy is magnified. Direct access to the seminal vesicles magnified view of retrovesicle field and haemostasis is secure properly with less hospital stay and minimal pain compared to open approach. Our technique of three ports transperitoneal approach with good skilful hands in laparoscopic and robotic surgery played an excellent outcome in treating this Zinner syndrome.

CONCLUSION

Zinner syndrome is a rare genitourinary disorder characterized by a triad of unilateral renal agenesis, ipsilateral seminal vesicle cyst, and ipsilateral ejaculatory duct obstruction. Asymptomatic patient with minimally invasive approach provides a satisfactory outcome can be considered as a golden standard [11].

REFERENCES

1. Ghonge, N. P., Aggarwal, B., & Sahu, A. K. (2010). Zinner syndrome: A unique triad of mesonephric duct abnormalities as an unusual cause of urinary symptoms in late adolescence. *Indian journal of urology: IJU: journal of the Urological Society of India*, 26(3), 444.
2. Zinner, A. (1914). Ein fall von intravesikaler Samenblasenzyste. *Wien Med Wochenschr*, 64(605), e9.
3. Mehra, S., Ranjan, R., & Garga, U. C. (2016). Zinner syndrome—a rare developmental anomaly of the mesonephric duct diagnosed on magnetic resonance imaging. *Radiology case reports*, 11(4), 313-317.
4. Cherullo, E. E., Meraney, A. M., Bernstein, L. H., Einstein, D. M., Thomas, A. J., & Gill, I. S. (2002). Laparoscopic management of congenital seminal vesicle cysts associated with ipsilateral renal agenesis. *The Journal of urology*, 167(3), 1263-1267.
5. Selli, C., Cavalleri, S., De Maria, M., Iafrate, M., & Giannarini, G. (2008). Robot-assisted removal of a large seminal vesicle cyst with ipsilateral renal agenesis associated with an ectopic ureter and a Müllerian cyst of the vas deferens. *Urology*, 71(6), 1226-e5.
6. Jang, K. D., Choi, K. H., Yang, S. C., Jang, W. S., Jang, J. Y., & Han, W. K. (2011). Laparoendoscopic single-site surgery (LESS) for excision of a seminal vesicle cyst associated with ipsilateral renal agenesis. *Korean Journal of Urology*, 52(6), 431-433.

7. Seo, I. Y., Kim, H. S., & Rim, J. S. (2009). Congenital seminal vesicle cyst associated with ipsilateral renal agenesis. *Yonsei Medical Journal*, 50(4), 560-563.
8. Ahallal, Y., Tazi, M. F., Khallouk, A., Elammari, J., Elfassi, M. J., & Farih, M. H. (2011). Conservative management of a congenital seminal vesicle cyst associated with ipsilateral renal agenesis revealed by cystitis: one case report. *Case Reports in Urology*, 2011.
9. Maehana, T., Fukuta, F., Kobayashi, K., Hirobe, M., Tanaka, T., & Masumori, N. (2018). Laparoscopic surgery for seminal vesicle cysts and ureterocele with urination disorder: a case report of Zinner syndrome. *Journal of Endourology Case Reports*, 4(1), 35-38.
10. Carmignani, G., Gallucci, M., Puppo, P., De Stefani, S., Simonato, A., & Maffezzini, M. (1995). Video laparoscopic excision of a seminal vesicle cyst associated with ipsilateral renal agenesis. *The Journal of urology*, 153(2), 437-439.
11. Selli, C., Cavalleri, S., De Maria, M., Iafrate, M., & Giannarini, G. (2008). Robot-assisted removal of a large seminal vesicle cyst with ipsilateral renal agenesis associated with an ectopic ureter and a Müllerian cyst of the vas deferens. *Urology*, 71(6), 1226-e5.
12. Seo, I. Y., Kim, H. S., & Rim, J. S. (2009). Congenital seminal vesicle cyst associated with ipsilateral renal agenesis. *Yonsei Medical Journal*, 50(4), 560-563.

Cite This Article: Dr. Morampudi Sarvani, Dr. A Siva Sai Bharadwaja, Dr. Kalidindi Kalyan Chakravarthi, Dr. Basa Maruti, Dr. Morampudi Lokendra Venkata Prasad (2022). A Case Report of Three Port Management of Zinner Syndrome. *East African Scholars J Med Surg*, 4(4), 92-96.