

## Original Research Article

## Evaluation of Placental Grading in 2<sup>nd</sup> and 3<sup>rd</sup> Trimester Using Gray Scale Ultrasound

Jannat Aslam<sup>1\*</sup>, Narjis Batool<sup>2,3</sup>, Abid Ali<sup>4</sup>, Akash John<sup>2,3</sup>, Huma Manzoor<sup>5</sup><sup>1</sup>Medical Imaging Doctor (MID), University Institute of Radiological Sciences and Medical Imaging Sciences, The University of Lahore, Gujrat Campus, The University of Chenab, G.T. Road, adjacent Chenab Bridge, Gujrat, Gujranwala, Punjab 50700, Pakistan<sup>2</sup>Lecturer, University Institute of Radiological Sciences and Medical Imaging Technology, The University of Lahore, Gujrat Campus, The University of Chenab, G.T. Road, adjacent Chenab Bridge, Gujrat, Gujranwala, Punjab 50700, Pakistan<sup>3</sup>Lecturer, The University of Chenab, Gujrat, The University of Chenab, G.T. Road, adjacent Chenab Bridge, Gujrat, Gujranwala, Punjab 50700, Pakistan<sup>4</sup>Associate Professor, Department of Allied Health Sciences, The University of Chenab Gujrat, The University of Chenab, G.T. Road, adjacent Chenab Bridge, Gujrat, Gujranwala, Punjab 50700, Pakistan<sup>5</sup>Master of Science in Diagnostic Ultrasound, UIRSMIT, University of Lahore, Pakistan**Article History**

Received: 14.05.2022

Accepted: 21.06.2022

Published: 02.07.2022

**Journal homepage:**<https://www.easpublisher.com>**Quick Response Code**

**Abstract: Background:** The use of ultrasound has a significant role in assessment of placental grading during antenatal treatment. With the help of ultrasound one can know about the gestational age, risk evaluation and it also describes about placental maturity, grading, fetal health, and prognosis. Any abnormality in placental maturity can lead towards poor pregnancy outcomes and fetus intrauterine growth restriction (IUGR). **Objective:** The objective of this study is to determine the evaluation of placental grading in 2<sup>nd</sup> and 3<sup>rd</sup> trimester using gray scale ultrasound for prediction of fetal outcomes. **Material and Method:** This study was conducted at gynecology and obstetrics department of two Hospitals (Sajida Khalil Hospital and Robina Sajid Hospital Gujrat) respectively. The duration of study was 4 months i.e. 14 January 2022 to 14 May 2022. Total number of participants was 200 pregnant ladies. These all were coming for their regular antenatal follow up in gynecology and obstetrics department of both hospitals. **Results:** Total 200 pregnant females with gestational age of 13 weeks and onward i.e. 2<sup>nd</sup> and 3<sup>rd</sup> trimester in order to see the placental grading in 2<sup>nd</sup> and 3<sup>rd</sup> trimester were taken as sample population for the present study. Out of the total 200, women 62 (31.0%) were of second trimester and 138 (69.0%) were of third trimester. The results for placental grading by statistical analysis showed out of 200, 74 (37.0%) showed Placenta with Grade-I, 75 (37.5%) showed placenta with Grade-II maturity and 51 (25.5%) showed placental maturity of Grade-III. **Conclusion:** Sonographic appearance of placental Grading gives us information about the well being and the information about placental appearance (hypoechoic, hyperechoic or echogenicity).

**Keywords:** Placenta, Grading, Trimester.

**Copyright © 2022 The Author(s):** This is an open-access article distributed under the terms of the Creative Commons Attribution 4.0 International License (CC BY-NC 4.0) which permits unrestricted use, distribution, and reproduction in any medium for non-commercial use provided the original author and source are credited.

## INTRODUCTION

The placenta is a part of fetus that creates a connection between mother and the developing fetus. It plays a crucial role for the nutritional requirements of fetus by mother, as fetus gets all its nutrients by mother with the help of placentagestation (Hassan, 2017; Nazir *et al.*, 2020). In humans the average placenta 22 cm (9inch) in length and 2-5.5 (.8-1 inch) in thickness, with the center being the thickest and the edges are the

thinnest. It typically weight approximately 500 grams. Its visibility on ultrasound starts by the end of 9<sup>th</sup> and 10<sup>th</sup> week of gestation (Abdelhaleem *et al.*).

The placenta provides exchange of oxygen and important nutrients to the developing fetus and also helps in excretion of wastes from the fetus (Ali, 2018). The morphological changes in placental grading, texture, and maturity can be visualized with the help of ultrasound. With the passage of time, placental maturity

\*Corresponding Author: Jannat Aslam

Medical Imaging Doctor (MID), University Institute of Radiological Sciences and Medical Imaging Sciences, The University of Lahore, Gujrat Campus, The University of Chenab, G.T. Road, adjacent Chenab Bridge, Gujrat, Gujranwala, Punjab 50700, Pakistan

increases during pregnancy. Placental maturity is a sign of fetal lungs maturity. The sonographic appearance of placenta is helpful in predicting fetal health and placental maturity (Begum *et al.*, 2020; Vidyarthi *et al.*, 2017).

The configuration of the placenta in relation to its development is examined by ultrasound. This has a significant impact on the degree of calcification. Grade 0: No major changes in placenta. The placenta examined as a secondary object when sonographers examine the fetus. There is no calcification within the body of placenta. The amnion Chorion plate is intact without fold. Grade I: One significant change in the placental body Echogenicity increases within the body of the placenta. The amnion chorion plate may show subtle folds. Approximately 37% of placenta showed grade I. Grade I placenta is very rare after 42 weeks of gestation. Grade II: Two major changes within the placenta. The basal calcification occurs in a linear fashion along the junction of placenta and deciduas. The chorionic plate shows obvious changes in placental parenchyma i.e. calcifications which does not touch the basal plate. 37.5% from total population showed placenta maturity of grade II maturity. Grade III The chorio amniotic plates grows many calcifications which outspread towards basal layer. The inter-cotyledonary septa calcify producing eclipsing or shadowing of returning "Echo information". It produces apparently an area with poor areas in the body of placenta. 25.5% showed placental maturity of grade III (Dutta *et al.*, 2017; Elnour, 2018; Naik *et al.*, 2021).

The study was conducted at two different Hospital of Gujrat, Punjab, Pakistan namely SAJIDA KHALIL HOSPITAL and ROBINA SAJID HOSPITAL, Gujrat. The sample of study was pregnant ladies of 2<sup>nd</sup> and 3<sup>rd</sup> trimester in order to see the placental maturity in these both trimesters respectively. The ultrasound machines used for this study were ALOKA and (TOSHIBA). Both machines were gray scaled. The convex transducer was used for ultrasound. Range of frequency of transducer was 4.6-6 MHz (El Khatim, 2016).

Ultrasound is a noninvasive technique for the evaluation of fetal gestational maturity. In 1979 Grannum and his colleagues studied a good relation between placental maturation variations with fetal lung maturity as determined by lecithin/sphingomyelin (L/S) ratio. The use of ultrasound to evaluate the placenta is routine among the majority of pregnant women. There are many complications during pregnancy which can result from abnormal placental development, which includes preeclampsia, intrauterine growth retardation 2 (IUGR) and abruption placenta previa, percreta or vasa previa, and may leads towards parental and fetal complications (Chen *et al.*, 2011; Mathai *et al.*, 2013).

## MATERIAL AND METHOD

### Selection and description of participants

This study conducted out in gynecology and obstetrics departments of two Hospitals (Sajida Khalil Hospital and Robina Sajid Hospital Gujrat) respectively. The duration of study was 4 months i.e. 14 January 2022 to 14 May 2022. Total number of participants was 200 pregnant ladies. These all were coming for their regular antenatal treatment in gynecology and obstetrics department of both hospitals (El Khatim, 2016).

### Inclusion Criteria

- The patient will be of second and third trimester with different gestational ages which include 13 to 38 weeks, Married women.

### Exclusion Criteria

- The patients from first trimester will not be part of this study, Unmarried women, Pregnancy without any other risk factor.

### Technical Information

The sample of study was pregnant ladies of 2<sup>nd</sup> and 3<sup>rd</sup> trimester in order to see the placental maturity in these both trimesters respectively. ALOKA and (TOSHIBA) were used for ultrasonography of patients. Both machines were gray scaled. Convex shaped probe used for ultrasound. Range of frequency of probe was 4.6-6 MHz.

Ultrasound is a noninvasive technique for the assessment of fetal gestational development. In 1979 Grannum and his colleagues studied a good relation between placental maturation variations with fetal lung maturity as determined by lecithin/sphingomyelin (L/S) ratio. The use of ultrasound to evaluate the placenta is routine among the majority of pregnant women. There are many complications during pregnancy which can result from abnormal placental development, which includes preeclampsia, intrauterine growth retardation 2 (IUGR) and abruption placenta previa, percreta or vasa previa, and may leads towards parental and fetal complications (Chen *et al.*, 2011; Mathai *et al.*, 2013).

### Statistics

Data was analysed with the help of computer generated software named SPSS-20 (Statistical package for social sciences). Data was presented in frequency and percentages.

## RESULTS

Total 200 pregnant females with gestational age of 13 weeks and onward i.e. 2<sup>nd</sup> and 3<sup>rd</sup> trimester in order to see the placental grading in 2<sup>nd</sup> and 3<sup>rd</sup> trimester were taken as sample population for the present study. All these were taking regular treatment from the Gynae and OBS departments of Sajida Khalil Hospital and Robina Sajid Hospital Gujrat, respectively. All the data

collected were analyzed statistically with the help of SPSS 20. Out of the total 200 women 62 (31.0%) were of second trimester and 138 (69.0%) were of third trimester. The results for placental grading by statistical

analysis showed out of 200, 74 (37.0%) showed Placenta with Grade-I, 75 (37.5%) showed placenta with Grade-II maturity and 51(25.5%) showed placental maturity of Grade-III.

**Table 1.1: Distribution of population**

		Trimester Group	Placental Grading
N	Valid	200	200
	Missing	0	0

Table 1.1 shows that total 200 pregnant ladies were taken as the sample population for this study.

**Table 1.2: Maternal age in year**

	N	Minimum	Maximum	Mean	Std. Deviation
Age in years	200	20.00	35.00	26.9000	3.35054
Valid N (listwise)	200				

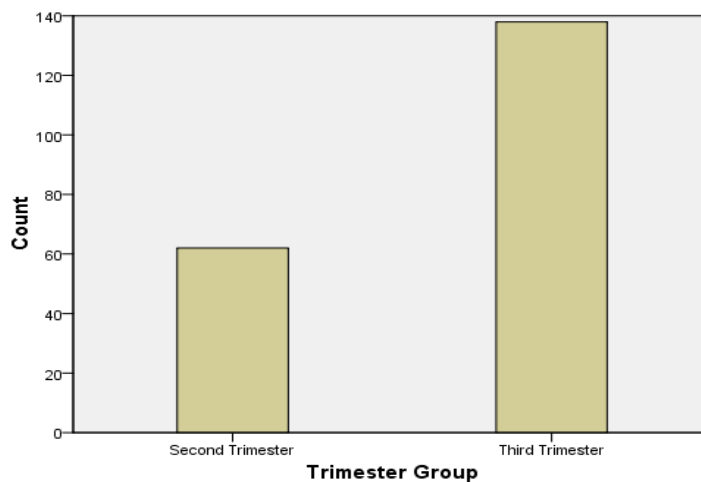
Table 1.2 shows that total 200 pregnant ladies were taken as the sample population for this study. The mean  $\pm$ S.D of maternal age was 26.9 $\pm$ 3.3 years with

minimum and maximum maternal age were 20 and 35 years respectively.

**Table 1.3: Number of participant**

		Frequency	Percent
Valid	Second Trimester	62	31.0
	Third Trimester	138	69.0
	Total	200	100.0

Table 1.3 shows total 200 patients were came in radiology department out of which 62 from second trimester and 138 from third trimester.



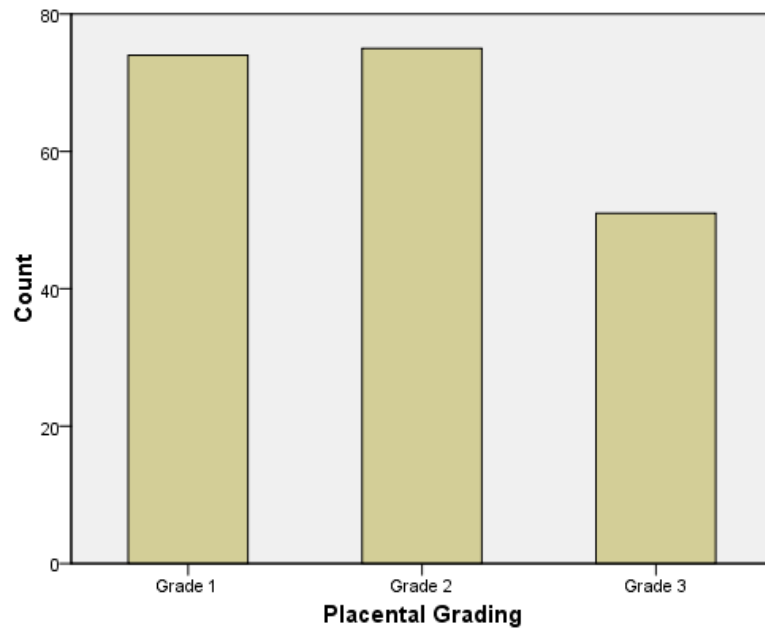
**Graphical representations of trimester group**

**Table 1.4: Placental grading by USG**

		Frequency	Percent
Valid	Grade 1	74	37.0
	Grade 2	75	37.5
	Grade 3	51	25.5
	Total	200	100.0

Table 1.4 shows that placental maturity percentage in Grade-I is 37%, Grade-II is of 37.5%,

Grade-III placental maturity is shown by 25% of the total population with the help of ultrasound.



Graphical representations of placental grading

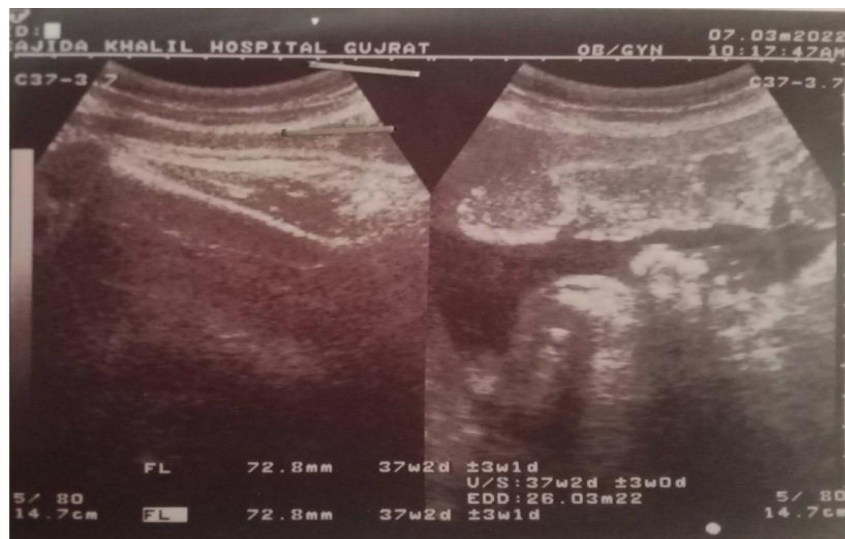

Figure 1: Grade III Anterior placenta at 37 Weeks

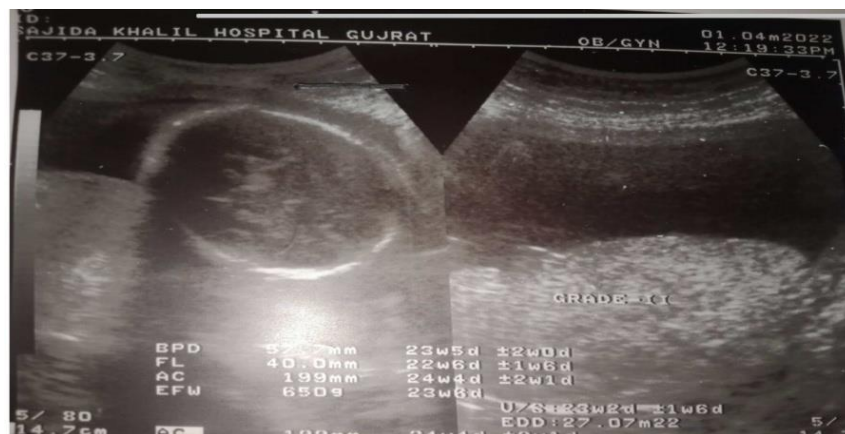

Figure 2: Grade II Posterior placenta at 23 weeks

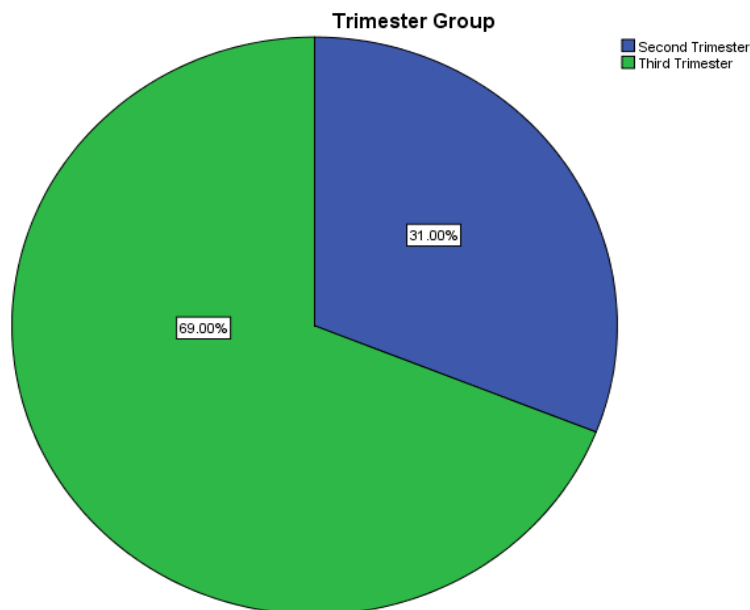


Figure 3: 31% presents population of 2nd trimester and 69% presents populations of 3rd trimester

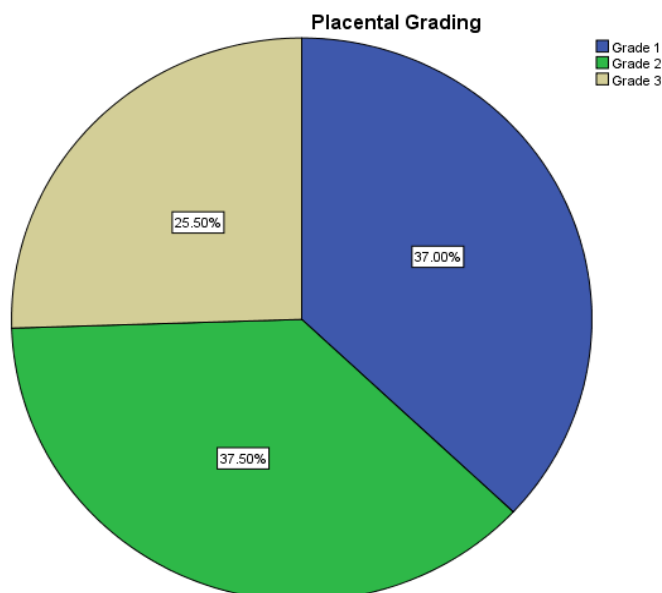


Figure 4: 37% shows Grade -I Placenta, 37.5% shows Grade-II Placenta and 25.5% Shows Grade-III placenta

## DISCUSSION

The use of ultrasound is increasing for the prenatal assessment of fetus and placental grading. It is one of the simple and reproducible methods. We examined placental grading by using ultrasonographic texture and features related to the gestational age (Mathai *et al.*, 2013). In 2011 CY Chen, HW Su, SH Pai and *et al* work on the Evaluation of placental maturity by the sonographic textures (Chen *et al.*, 2011; Mathai *et al.*, 2013).

Ultrasound is very helpful in the detection of tissue structures of placenta as it is a non-invasive technique. With the help of ultrasonography we can see the apparent changes in the texture of placenta

when there are some structural changes (Chen *et al.*, 2011). We can see the echogenicity of the placenta and any abnormal region in placenta too. For this reason our study guides us the placental echogenicity changes with gestational age. This cross-sectional study gave significant data about the importance of recognition about placental grading at gestational age of 2<sup>nd</sup> and 3<sup>rd</sup> trimester by ultrasonography. The study was conducted in order to observe placental grading in second and third trimester using gray scale ultrasound. Total 200 participants were taken in this study. Out of these 200 participants, 62 participants were of second trimester and 138 were of third trimester. 31% of the total participants in second trimester and 69% of total participants in third trimester. The placental maturity percentage in Grade-I is 37% , Grade-II is of 37.5%,



Grade-III placental maturity is shown by 25% of the total population with the help of ultrasound.

By collecting all the data and analysis of data by using SPSS 20 (Statistical Package for Social Sciences) the results showed different percentages to classify placenta in different grading in 2<sup>nd</sup> and 3<sup>rd</sup> trimester. Farzana Begum and et al Work on the third trimester placental grading by ultrasonography began in 2020. This study found that a sonographic diagnosis of a grade-III placenta is a good predictor of fetal lung maturity than amniocentesis, which is a time-consuming and possibly fatal invasive operation. Grade II placental maturity was found in 35% of the women, 33.5 percent at Grade III, 25% in Grade I, and 6.5 percent in Grade 0 placental maturity, according to ultrasonography. The overwhelming majority of women (75%) were in good health and had a healthy child (Begum et al., 2020).

## CONCLUSION

In conclusion, the sonographic appearance of placental grading was reproducible and effective for use in clinical practice. Our findings suggested the strong relation between the gestational age and placental grading. The result from all this data gave us a base for the use of placental grading with texture features, which can be used as one of the indication for antenatal treatment during pregnancy with the help of ultrasound.

The study was a cross sectional study. This study provided us the vital information about placental Grading with the help of ultrasonography. This study gave us complete picture of placental grading and maturity and how it affects fetal outcomes.

## REFERENCES

- Abdelhaleem, S. A., Ayad, C. E., Wahab, B. A., Allah, A., & Ahmed, M. E. Evaluation of diabetes effected on placenta (from 20weeks-38 weeks) using ultrasonography.
- Ali, R. K. E. (2018). *A Study of Relationship between Placental Thickness and Fetal Age In 3rd trimester in Sudanese Women* Sudan University of Science and Technology].
- Begum, F., Jesmin, S., Khatun, R., Parvin, S., & Rahman, A. (2020). Third Trimester Placental Grading by Ultrasonography and its Relationship

with Fetal Outcome. *TAJ: Journal of Teachers Association*, 33(2), 94-99.

- Chen, C. Y., Su, H. W., Pai, S. H., Hsieh, C. W., Jong, T. L., Hsu, C. S., & Chou, S. Y. (2011). Evaluation of placental maturity by the sonographic textures. *Archives of gynecology and obstetrics*, 284(1), 13-18.
- Dutta, A., Sahu, R. K., Chatterjee, K., Kothari, S., Rahaman, S. R., & Sen, S. (2017). Placental damages from ultrasonic changes to histopathological findings in maturing placenta in pregnancy complicated with hypertension: an observational clinical study. *International Journal of Reproduction, Contraception, Obstetrics and Gynecology*, 6(5), 1834-1842.
- El Khatim, M. B. (2016). *Evaluation of Placenta in Pregnant Ladies at Omdurman Maternity Hospital Using Ultrasound* Sudan University of Science and Technology].
- Elnour, A. E. A. (2018). *Study of effect of Diabetes and Hypertension on placental Grading In Second and Third Trimester Using Ultrasonography* Sudan University of Science and Technology].
- Hassan, H. M. A. (2017). *Estimation of fetal Age by Placenta Thickness in Second and Third Trimester using ultraSonography* Sudan University of Science and Technology].
- Mathai, B. M., Singla, S. C., Nittala, P. P., Chakravarti, R. J., & Toppo, J. N. (2013). Placental thickness: its correlation with ultrasonographic gestational age in normal and intrauterine growth-retarded pregnancies in the late second and third trimester. *The Journal of Obstetrics and Gynecology of India*, 63(4), 230-233.
- Naik, A., Khoiwal, S., Sharma, N., & Aarthy, P. (2021). Clinical significance of ultrasonic placental grading during third trimester in hypertensive disorders in pregnancy and its correlation with fetal outcome in tertiary care centre. *International Journal of Reproduction, Contraception, Obstetrics and Gynecology*, 10(9), 3325-3331.
- Nazir, S., Aamir, M., Malik, S. S., & Fatima, M. (2020). Sonographic Placental Grading in 3 Trimester of Hypertensive Patients. *Asian Journal of Allied Health Sciences (AJAHS)*, 37-41.
- Vidyarthi, D., Bharti, D., Toppo, D., & Kumari, D. (2017). Comparative Study of Ultrasonic Placental Grading in Hypertensive Disorder in Pregnancy with Normal Pregnancy. *IOSR J. Dental Med. Sci.*, 16(5), 25-30.

**Cite This Article:** Jannat Aslam, Narjis Batool, Abid Ali, Akash John, Huma Manzoor (2022). Evaluation of Placental Grading in 2<sup>nd</sup> and 3<sup>rd</sup> Trimester Using Gray Scale Ultrasound. *EAS J Radiol Imaging Technol*, 4(4), 68-73.