

Occlusive Syndrome Revealing Hirschsprung's Disease in Two Pediatric Cases Seen in Emergency in a Peripheral Hospital Department of Pediatric Surgery Fousseyni Daou Hospital in Kayes

Kouyate, M^{1*}, Mouistapha, M²¹Service De Chirurgie Pédiatrique De l'Hopital Fousseyni DAO²Service De Chirurgie Général

*Corresponding author: Kouyate, M

| Received: 01.06.2022 | Accepted: 06.07.2022 | Published: 13.07.2022 |

Abstract: Hirschsprung's disease is a congenital anomaly of the innervation of the distal intestine, usually limited to the rectum and colon, resulting in partial or total functional occlusion. It is one of the most common causes of obstruction in children. It is a rare pathology, but the diagnosis of which is becoming increasingly easy because of dill Omo pathology. We report two cases treated urgently in the pediatric surgery department of the Fousseyni Daou hospital in Kayes. Our objectives were to describe the clinical aspects and the management of an occlusive syndrome secondary to Hirschsprung's disease.

Keywords: Hirschsprung's disease, secondary occlusion, Swenson, Kayes.

INTRODUCTION

Hirschsprung's disease is caused by the absence of ganglion cells in the vegetative nerve plexuses of Meissner and Auer Bach (ganglia) in the intestinal wall. The frequency is 1 in 5000 live births [3]. It is usually limited to the distal part of the colon 75% of cases and to the rectum but can reach the entire colon 5% or even the entire colon and intestine hail. Males are more affected (male: female ratio 4:1) unless the whole colon is involved, in which case there is no gender difference. Symptoms are severe constipation, abdominal distention and often vomiting. Diagnosis is based on barium enema and rectal biopsy. Manometry can be useful in the evaluation and reveals the sphincter relaxation abnormality. In our study we relied on the result of the rectal biopsy to confirm the diagnosis. The treatment of Hirschsprung's disease is mainly surgical.

OBSERVATION

The two children aged 2 and 4, all male, had been referred to us by the pediatric service for occlusive syndrome. On questioning, we had revealed a cessation of materials and gas and vomiting for a few days and in the antecedents a delay in evacuation of meconium more than 48 hours after birth and almost regular constipation but often relieved by an evacuating washout. On physical examination, the general

condition was fair in both patients with temperatures of 38 degrees and 38 degrees 5 respectively, the conjunctivae were moderately stained, significant bloating of the abdomen. On digital rectal examination, the rectum was empty in both patients. The biological assessment had revealed a slight anemia in the two patients respectively at 11g/dl and 9g/dl. Given the significant bloating and the absence of stool emission, with vomiting, we performed a bypass stoma (colostomy) in both patients after correcting the hydro-electrolyte imbalance. During the operation we noticed a clear disparity between the distal part and the proximal part of the ascending colon. The distal, therefore rectal, part was thin and of small caliber and the proximal part of large caliber. This remark of difference in caliber led us to perform a rectal biopsy in the two patients for the anatomopathology, which confirmed Hirschsprung's disease in our two patients. In the first 2-year-old patient, one month after the stoma, we proceeded to restore continuity while resecting the diseased distal part and performing a colo-anal anastomosis while preserving the sphincter (stenosis) [1, 4, 5]. . The same technique was performed in the second 4-year-old patient, 2 months after his stoma. The postoperative course was simple in both cases after 10 days of hospitalization.

Quick Response Code



Journal homepage:

<https://www.easpublisher.com/>

Copyright © 2022 The Author(s): This is an open-access article distributed under the terms of the Creative Commons Attribution **4.0 International License (CC BY-NC 4.0)** which permits unrestricted use, distribution, and reproduction in any medium for non-commercial use provided the original author and source are credited.

Citation: Kouyate, M & Mouistapha, M (2022). Occlusive Syndrome Revealing Hirschsprung's Disease in Two Pediatric Cases Seen in Emergency in a Peripheral Hospital Department of Pediatric Surgery Fousseyni Daou Hospital in Kayes. *Cross Current Int J Med Biosci*, 4(3), 55-57.

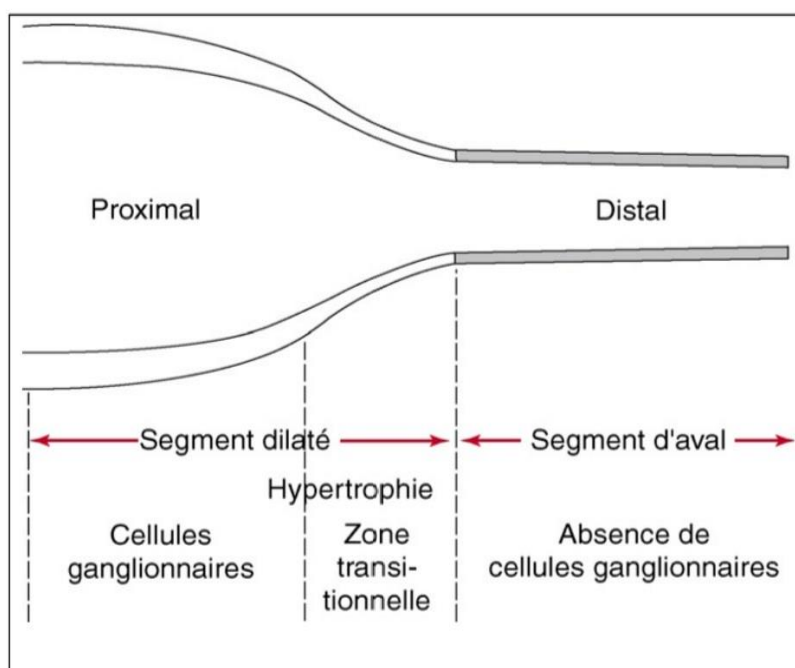
COMMENTS

Hirschsprung's disease is a congenital enteric agnesis of Auer Bach and Meissner's submucosa on a segment of intestine that extends from the anus to a variable distance from the colon [1]. The most common form is limited to the rectosigmoid [2], which is the case in our study. The classic term of megacolon refers to the dilated aspect that the healthy functional colon takes on above the obstruction, which leads us to differentiate the healthy part from the affected part of the intestine. The main complication in the neonatal period is acute enterocolitis which can be fatal and in fact all the gravity, this one can impose an intestinal diversion in urgency [7, 10], but in our two patients the diversion was imposed because occlusive syndrome which did not yield. Hirschsprung's disease is the most common occlusion in children [3]. Its frequency is estimated at 1/5000 live births [1]. The diagnosis of this pathology is both clinical, radiological and above all anatomopathological [1, 2, 4], during our study we

mainly relied on the clinic and the anatomopathology. In the literature, most studies have found a delay in the evacuation of meconium and chronic constipation in children suffering from Hirschsprung's disease [2, 3, 7-10].

Rectal biopsy is of great importance in the confirmation of Hirschsprung's disease [6], in our two patients it had been confirmed by the pathology of the rectal biopsy specimen. A new and more improved surgical technique is increasingly used in the correction of Hirschsprung's disease: SOAVE [4, 6]. In our two patients, we used the Stenos technique given the context in which they were admitted to the service. The postoperative course was simple up to 12 months after the interventions without sphincter disorders.

HIRSCHSPRUNG'S DISEASE IN CHILDREN - ABOUT 2 EMERGENCY CASES



First pathophysiological description of Hirschsprung's disease

REFERENCES

1. Carcassonne, M., Moisson Lacombe, G., Pau, C. *Maladie de Hirschsprung*. Encycl. Méd. Chir., Paris; Techniques Chirurgicales, Appareil Digestif, 40600, 4-10.
2. Bakayoko, M. H. (2011). *Maladie de hirschsprung : Aspect epidemiologique, diagnostique et thérapeutique*. (Thèse: Med); Bamako, faculté de médecine et d'odonto stomatologie.
3. Philippe-Chomette, P., Peuchmaur, M., & Aigrain, Y. (2008). *Maladie de Hirschsprung chez l'enfant: diagnostic et prise en charge*. *Journal de Pédiatrie et de Puériculture*, 21(1), 1-12.
4. Tamby, E., Fiquet, C., Belouadah, M., Lefevre, F., Zacchar, D., & Poli-Mérol, M. L. (2010). Abaissement transanal selon Soave dans la maladie de Hirschsprung: évaluation précoce des résultats. *e-mémoires de l'Académie Nationale de Chirurgie*, 9(4), 18-20.
5. Swenson, O., Fischer, J. H., & Gherardi, G. J. (1959). Rectal biopsy in the diagnosis of Hirschsprung's disease. *Surgery*, 45, 6908.
6. Podedvin, G., Philippe-Chomette, P., Peuchmaur, M., Aigrain, Y. (2009). *Maladie de Hirschsprung chez l'enfant diagnostic et prise en charge*. *Eur J Pediatr Surg*, 16, 1-33.
7. Langer, J. C., Minkes, R. K., Mazziotti, M. V., Skinner, M. A., & Winthrop, A. L. (1999). Transanal one-stage Soave procedure for infants

- with Hirschsprung's disease. *Journal of pediatric surgery*, 34(1), 148-152.
7. Nasir, A. A., Adeniran, J. O., & Abdur-Rahman, L. O. (2007). Hirschsprung's disease: 8 years experience in a Nigerian teaching hospital. *Journal of Indian Association of Pediatric Surgeons*, 12(2), 68.
 8. Bouamama, H. (2014). La maladie de Hirschsprung: Aspects épidémiologique diagnostique et thérapeutique (these: med); Fes, faculté de médecine et de pharmacie.
 9. Izadi, M., Mansour-Ghanaei, F., Jafarshad, R., Joukar, F., Bagherzadeh, A. H., & Tareh, F. (2009). Clinical Manifestations of Hirschsprung's Disease: A Six Year Course Review of Admitted Patients in Gilan, Northern Iran. *Middle East Journal of Digestive Diseases (MEJDD)*, 1(2), 68-73.
 10. Boukthir, S., Silimi, A., Mazigh, S., & Oubich, F. (2007). La constipation chronique du nourrisson et de l'enfant. Etude de 78 cas. *tunisie medicale CODEN TUMEAF*, 85(2), 109-115. ISSN 0041-4131