

## Peritoneal Tuberculosis in Children Revealed by Appendicular Syndrome in a Case in the Pediatric Surgery Department: Fousseyni Daou Hospital in Kayes (Mali)

Kouyaté, M<sup>1,2\*</sup>, Katilé, D<sup>2,4</sup>, Sangare, D<sup>2,4</sup>, Kane, M<sup>3</sup>, Haidara, M<sup>1</sup>

<sup>1</sup>Service De Chirurgie Pédiatrique De L'hôpital Fousseyni Daou, Kayes, Mali

<sup>2</sup>Centre National De Recherche Scientifique Et De Technologie (CNRST), Bamako, Mali

<sup>3</sup>Unité De Chirurgie Générale De L'hôpital Fousseyni Daou, Kayes, Mali

<sup>4</sup>Service De Médecine Interne De L'hôpital Fousseyni Daou, Kayes, Mali

\*Corresponding author: Kouyaté, M

| Received: 22.07.2022 | Accepted: 29.08.2022 | Published: 02.09.2022 |

**Abstract:** Peritoneal tuberculosis is a rare form of extra pulmonary tuberculosis in children. It represents 1 to 2% of all forms of tuberculosis. It is characterized above all by the occurrence of ascites, a progressive deterioration of the general condition, a fever. Its diagnosis can sometimes be very difficult; we report a case of peritoneal tuberculosis revealed by a surgical emergency.

**Keywords:** Peritoneal tuberculosis, surgery, child.

### INTRODUCTION

Peritoneal tuberculosis is a type of tuberculosis that affects the intestine, the peritoneum, the abdominal lymph nodes, more rarely, the solid organs of the abdomen (liver, pancreas and spleen). The clinical picture of digestive tuberculosis is generally unspecific, resulting in weight loss, fever, painful abdominal bloating, constipation or sometimes dysentery-like diarrhea, ascites. Biologically, the rate of adenosine deaminase is greater than 40UI / liter, the search for acid-alcohol bacilli resistant to direct examination and the cultures adapted to mycobacteria are not very sensitive, the serum level of CA-125 is often high [1, 3, 8]. Radiological examinations can contribute to the diagnosis of peritoneal tuberculosis, laparoscopy can describe the appearance of the intra-abdominal organs and deduce [7]. The culture on a biopsy specimen is only positive in 10% to 20% of cases. Treatment is based on standard anti-tuberculosis drugs with regular clinical monitoring for at least 6 months.

### PATIENT AND OBSERVATION

It was a 15-year-old girl who was referred to us for abdominal pain. The interrogation found vague abdominal pain, intermittent for 3 months associated with progressive weight loss and a feeling of fever, often relieved by unknown analgesics, antipyretics and antispasmodics. On clinical examination we found faintly colored conjunctivae, a temperature of 38.5 degrees, abdominal pain throughout the abdomen but especially accentuated in the right iliac fossa, no ascites, a few adenopathies in the two groins. The biological examination reported just anemia at 11g/dl and a high sedimentation rate of 40. Abdominopelvic ultrasound found an abdomen sensitive to the passage of the probe, appendicular inflammation with a decrease in peristalsis of the intestines. A laparotomy performed allowed us to discover a very inflammatory appendix, agglutinated intestines covered by whitish granulations Fig 1. We proceeded to an appendectomy, a biopsy at the level of the omentum for the pathology which revealed peritoneal tuberculosis. After the child was put on anti-tuberculosis for 6 months, with total recovery.

Quick Response Code

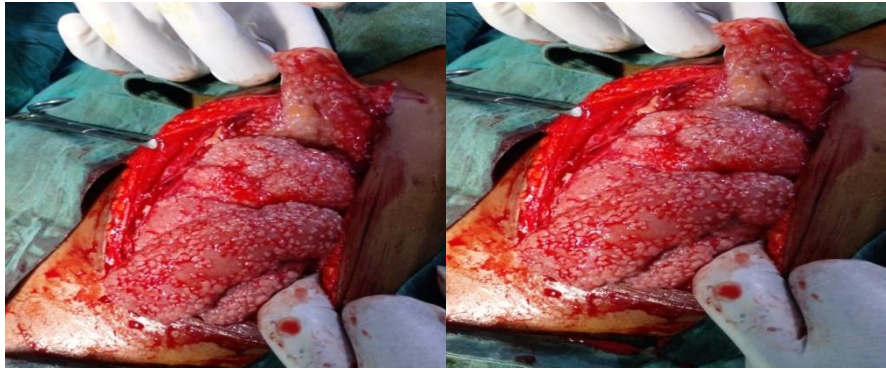


Journal homepage:

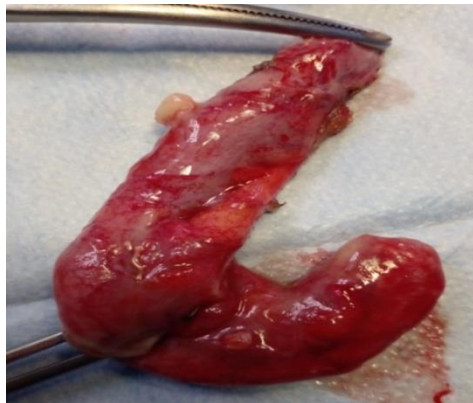<https://www.easpublisher.com/>

**Copyright © 2022 The Author(s):** This is an open-access article distributed under the terms of the Creative Commons Attribution **4.0 International License (CC BY-NC 4.0)** which permits unrestricted use, distribution, and reproduction in any medium for non-commercial use provided the original author and source are credited.

**Citation:** Kouyaté, M, Katilé, D, Sangare, D, Kane, M, Haidara, M (2022). Peritoneal Tuberculosis in Children Revealed by Appendicular Syndrome in A Case in the Pediatric Surgery Department: Fousseyni Daou Hospital In Kayes (Mali). *Cross Current Int J Med Biosci*, 4(4), 74-75.



**Figure 1: Granules covering the entire intestine, omentum and other organs**



**Figure 2: Removal of the appendix**

## DISCUSSION

Peritoneal tuberculosis is generally manifested by ascites associated with certain general signs such as: weight loss, fever, abdominal pain. In our patient, the dominant sign was diffuse abdominal pain localized in the right iliac fossa, which led us to perform a laparotomy.

Tuberculous peritonitis is a primary peritonitis, found during medical conditions. In these conditions, the seeding of the peritoneal cavity results from the passage of bacteria by the hematogenous route or by translocation to the peritoneal cavity. They are the consequence of an alteration of antibacterial defense mechanisms, mainly affecting the reticuloendothelial system, the function of neutrophils and the mechanisms of humoral and cellular immunity [2]. In the literature many authors have found ascites as a frequent clinical sign [1, 3, 5, 8]. The high level of adenosine deaminase in the ascites fluid confirms the diagnosis of peritoneal tuberculosis, but in our case there was no ascites which led us to do a biopsy of the omentum for the pathology, which confirmed the diagnosis. The histological study had concluded caseofollicular peritonitis of tuberculous origin. The rest of the treatment was provided at the tuberculosis treatment centre, with standard antituberculosis drugs, under clinical supervision.

## CONCLUSION

Peritoneal tuberculosis is a rare form of extraperitoneal tuberculosis in children. The diagnosis is quite difficult, the dosage of adenosine deaminase, laparoscopy are specific for the diagnosis, but it can be revealed by a surgical emergency especially peritonitis.

## REFERENCES

1. Maltezou, H. C. (2000). Tuberculose extra-pulmonaire chez l'enfant, *Arch Dis Infant*.
2. Demir, K. (2001). Péritonite tuberculeuse - rapports de 26 cas, détaillant les problèmes diagnostiques et thérapeutiques, *Eur J Gastroentérol Hépatol*.
3. Saczek, K. B. (2001). Dilemmes diagnostiques de la tuberculose abdominale chez l'enfant, *Pediatr Surg Int*.
4. Chavalittamrong, B. (1982). Péritonite tuberculeuse chez les enfants *Chirurgie pédiatrique prog*.
5. Fox, H. (1987). Tuberculose péritonéale. À propos d'une observation, *Ann Pédiatre*.
6. al-Fadel Saleh, M. (1997). Péritonite tuberculeuse de l'enfant : à propos de deux cas et revue de la littérature, *J Pediatr Gastroenterol Nutr*.
7. Apaydin, B. (1999). Intérêt de la laparoscopie diagnostique dans la péritonite tuberculeuse, *Eur J Surg*.
8. Sioson, P. B. (1992). Péritonite tuberculeuse chez un garçon de trois ans : à propos d'un cas et revue de la littérature *Pédiatre, Infect Dis J*.