

Case Report

Clinical Management of Internal Inflammatory Perforating and Non Perforating Root Resorption Associated With an Apical Resorption and a Cystic Lesion: A Case Report

Mkaddem Rania^{1*}, Mabrouk Rim¹, Frih Nadia¹¹Hospital of Charles Nicole, Bd du 9 Avril 1938, Tunis, Tunisia**Article History**

Received: 13.05.2022

Accepted: 09.06.2022

Published: 02.09.2022

Journal homepage:<https://www.easpublisher.com>**Quick Response Code**

Abstract: Root resorption has been defined as the loss of dental hard tissue dentin and cementum as a result of osteoclastic cell action according to the glossary American association, of endodontics. It can occur following dental trauma; orthodontic treatment or chronic infection of the pulp and periodontal structure. It can lead to the loss of the tooth if untreated. Post traumatic root resorption could be challenging. The cone beam computed tomography allows making a reliable differential diagnosis between internal and external resorption as well to assess the extent of the lesion and the thickness of the residual walls in a 3d space. Timely intervention is essential for an optimum management. The present case aim was to report the surgical management of internal inflammatory perforating root resorption (IRR) complicated with a periapical cystic lesion using 3d imaging CBCT.

Keywords: Inflammatory resorption, internal, external, diagnosis, management, cone beam computed tomography.

Copyright © 2022 The Author(s): This is an open-access article distributed under the terms of the Creative Commons Attribution **4.0 International License (CC BY-NC 4.0)** which permits unrestricted use, distribution, and reproduction in any medium for non-commercial use provided the original author and source are credited.

INTRODUCTION

Root resorption is the non bacterial destruction of the mineralized cementum or dentin due to the interaction of clastic cells and dental hard and soft tissues.

It is well established that CBCT has an important role in the diagnosis and management of internal inflammatory root resorption. It can provide precise information about the location, the size of the resorptive defect and the thickness of the residual dentinal walls.

Biodentine is appropriate to effectively seal the resorptive cavity due to its good handling, one step Obturation, its tightness and its biocompatibility.

Good prognosis depends on early detection, sufficient root structure remains.

CASE PRESENTATION

An 18-years-old male was referred to the department of conservative odontology in the hospital of Charles Nicolle Tunis with a discomfort in his upper buccal maxillary region. The patient history revealed a dental trauma 9 years ago and a previous dental

treatment of the concerned teeth. No episode of pain or swelling was reported. The patient's medical history was non contributory.

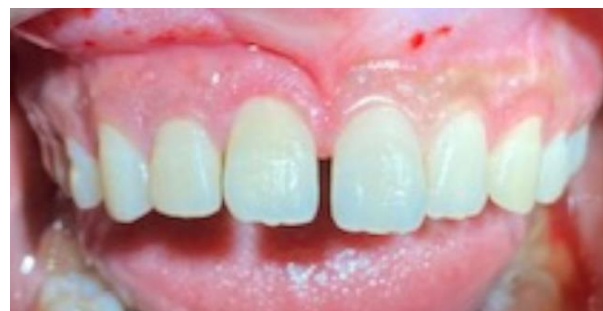

Figure 1: Initial clinical aspect of maxillary anterior teeth with presence of sinus tract appended on the attached gingiva of the tooth 12

Clinical examination revealed intact dental crown with a previously initiated endodontic therapy in tooth 11 and 12 (Figure 1).

The periodontal exam of tooth 11 was normal whereas tooth 12 presented mobility grade 2 and a sinus tract appended on the attached gingiva of the tooth 12 was noticed.

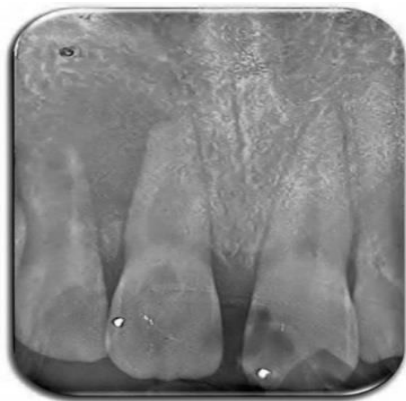

Figure 2: Preoperative radiograph with enlargement of the root canal space suggesting internal root resorption in tooth 11 and a periradicular lesion. Tooth 12 presented a wide canal and a short root with thin radicular dentin walls

Radiographic examination revealed a well-circumscribed, fairly oval radiolucent lesion in the middle third of the root canal of tooth 11 and apical inflammatory external resorption.

A 2cm*1,5cm apical lesion surrounded the tooth 12 and extended to the distal portion of the tooth 11. Apical radiolucency was detected at the radiographies appended to the apex of tooth 11 (Figure 2).

In order to acquire more information about the location and the dimensions of the resorptive area (and the cystic lesion) in all plans, a CBCT scan with small field of view was requested for the patient.

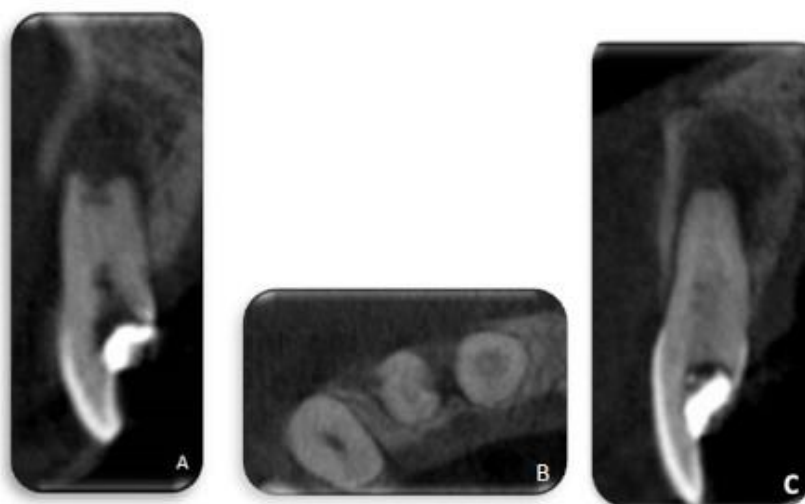


Figure 3: Cone beam computed tomography scans of the maxillary anterior teeth 11 and 12; (A): Sagittal cross section showing open apex in tooth 12 and the extensive involvement of the buccal cortical plate. (B): Axial CBCT scans shows that the resorptive defect has perforated the root canal walls of tooth 12 (the distal and mesial aspect). The radiolucent lesion has perforated the buccal cortical plate in relation with tooth 12. (C): Axial CBCT scans showing a radiolucent defect in the middle third of root canal of tooth 11 and an apical root resorption associated to a periapical radiolucent lesion

CBCT Sagittal slices, coronal, and axial were obtained with the i-Dixel One Data One Viewer Plus.

Sagittal and axial scans confirmed the presence of an internal non perforating inflammatory root resorption in the middle third of tooth 11 and periapical radiolucency. (Figure 3, B and C).

A severe internal perforating resorption in the tooth 12 which was extending to the mesial and distal surfaces were noticed in Axial cross sections (Figure 3, B). The tooth 12 had a large canal with thin radicular walls and huge apical foramen (Figure 3, A).

Basing on clinical and radiographic facts, the diagnosis of non perforating internal inflammatory resorption associated with apical inflammatory external resorption was retained for the tooth 11 and internal

inflammatory perforating resorption for the tooth 12 associated with a peri radicular radiolucency.

The therapeutic strategy was endodontic treatment of tooth 11 followed by an endodontic surgery to remove the peri apical lesion and to expose the root apex. Then a root end resection and an ultrasonic preparation were planned followed by the root end filling using Biodentine.

Since the prognosis of the tooth 12 was questionable, extraction was the treatment of choice, but the patient desired to save the tooth. The possibility of conserving tooth 12 was considered through a combination of treatments: non surgical root canal therapy to disinfect the root canal system and then to completely obdurate it using Biodentine, followed by surgical treatment to expose the resorptive defect and to completely remove the granulosomatous material.

The therapeutic strategy was discussed with the patient and the patient's consent was obtained. At the first appointment, the tooth was isolated with a rubber dam and the temporary sealer was removed.

Working length determination was performed electronically using the Locapex 6 (IONYX, France) for tooth 11 and was then confirmed radiographically. The root canal system was cleaned and shaped with Revo S up to SC2 rotary file (Micro Mega, France).

Working length determination using an apex locator was not possible because of the presence of the resorptive perforation in tooth 12. The working length was determined with a K-File (ISO 20) with a peri apical radiography. The root canal was instrumented with stainless steel hand files. Bleeding was present from the canal during instrumentation and diminished gradually.

Irrigation was performed with 2.5% sodium hypochlorite for both teeth. Calcium hydroxide was placed as an intracanal medication. The cavities were sealed with a temporary filling (MD-Temp, Meta Biomed, France.).

After 7 days, the dressing material was removed from tooth 11 and 12 and the root canals were dried using paper points. The root canal of tooth 12 was filled completely using Biodentine (Septodont, France).

A gutta-percha cone was used to fill the apical root canal of tooth 11 with a down pack motion using the System B Unit (FI-P, Woodpecker) and sealer cement (Zinc oxide eugenol root canal cement).

Then the resorptive defect and the rest of the canal were obturated using a thermoplasticized Gutta Percha (FI-G, Woodpecker) (Figure 4).

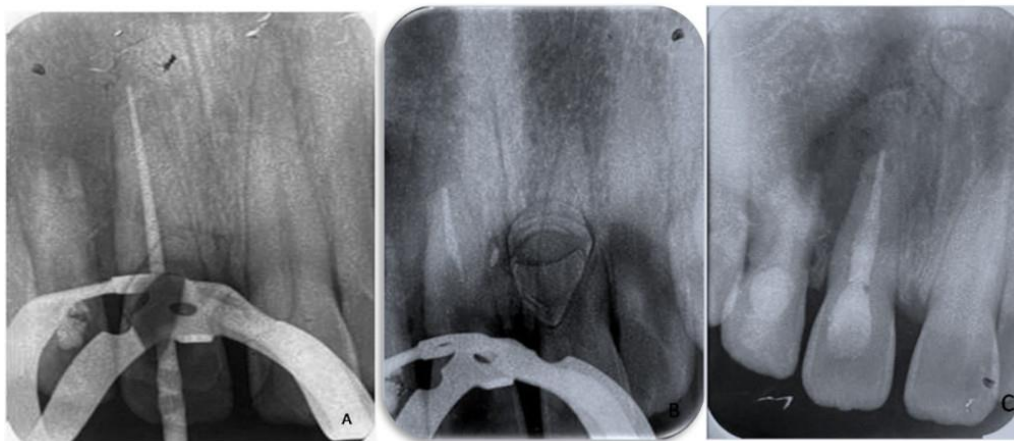


Figure 4: A: Master cone radiograph; B: Gutta-percha cone used to fill the apical root canal; C: Post operative radiograph: Obturation with thermoplasticized Gutta-percha

The access cavities were sealed using Cavit temporary filling material. (MD-Temp, Meta Biomed, France). After 3 days, the cavities were restored using

an anterior composite resin filling (Opallis, FGM, Bresil). The endodontic surgery was planned for the next meeting (Figure 5).

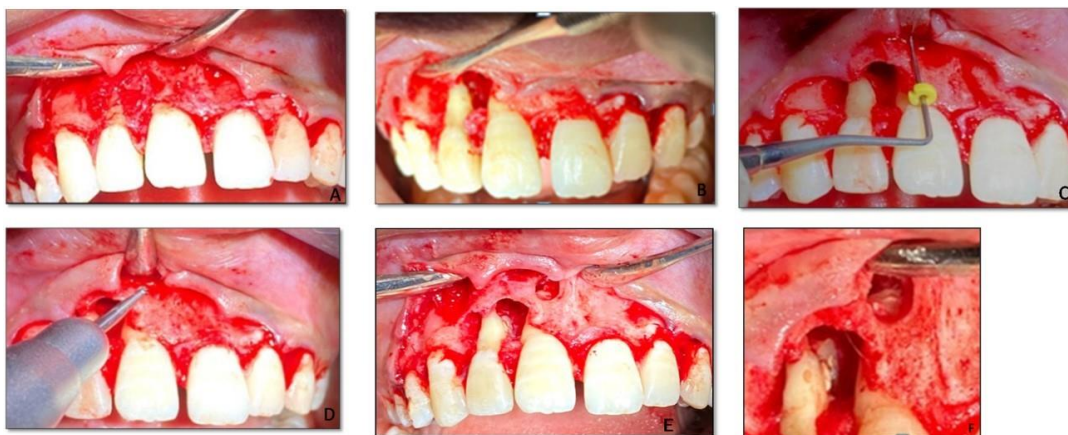


Figure 5: A: The mucogingival flap is raised, B: Excavation of the granulomatous tissue from the defect and appearance of the perforation defect; C: The periodontal probe is indicating the approximate location of the root apex previously measured on the CBCT Sagittal section; D and E: The high-speed bur is removing bone to have a better exposition of the root apex of tooth 11; F: after retro preparation and retro filling with Biodentine

First of all, a sub marginal full thickness flap (that exposed the granulation tissue and the bone destruction) was elevated (Figure 5). Then, the granulomatous lesion was completely removed and a direct contact with bone was ensured. No need to osteotomy regarding tooth 12 because the cortical bone has been fenestrated by the lesion.

The osteotomy was necessary to expose the root end of tooth 11. Once the granulation tissue was removed, the root apex was visible. One millimeter of the root end was resected and then prepared using an ultra sonic retro-tip (AS3D, Acteon Satelec, North America). Root end cavity was filled using Biodentine (Septodont, France).

Finally, the flap was repositioned and sutured and the patient was recalled one week later for suture removal (Figure 5).

DISCUSSION

Clinical and Radiographic Diagnosis

Internal resorption is usually asymptomatic and often is accidentally detected through routine OPT radiographs (Nilsson E *et al.*, 2013). However, clinical signs may occur according the pulpal condition or the presence of a periodontal lesion (Caliskan M. K *et al.*, 1997) and may vary according to the location of the IRR and its wideness.

The clinical aspect of “pink spot” can be observed in case of coronal location of the internal resorption. This color turns grey when the pulp becomes necrotic (Siolveria *et al.*, 2009).

The inflamed connective tissue filling the IRR defects degenerates, undergoes necrosis, and triggers an apical periodontitis. Perforation of the root is usually followed by the development of a sinus tract (Nilsson E *et al.*, 2013).

In case of absence of clinical manifestation, radiographic signs might be the only indication of a resorptive lesion.

Intraoral X-ray of internal root resorption is often characterized by the radiographic appearance of an oval shape enlargement within the pulp chamber or the root canal with smooth, well-demarcated margins (tooth 11).

Also, the root canal outline is continuous with that of the resorptive defect (Patel S *et al.*, 2018).

When two parallel radiographs are taken, and the lesion maintaining its position relative to the root canal space then the lesion is an internal root resorption.

However, with external root resorption, the lesion alters its position relative to the root canal space when the X-ray beam is shifted (Bhuva B *et al.*, 2011).

With the two dimensions technique, information obtained are limited because of the superimposition of anatomical structures and image distortion. The conventional radiographic techniques are unable to reveal the thickness of the remaining root canal dentine, particularly in the bucco-lingual plane and the exact location of a resorptive defect.

Using CBCT, accurate assessment of periapical lesions is achievable at the earliest stages. The size, shape, dimensions and location of the resorptive lesion, presence of root perforations, root wall thickness can be established in the cross-sectional views.

Therapeutic Decision

Once the diagnosis of internal root resorption has been made, the decision-making must take into consideration several criteria: patient’s age, tooth location, resorption location, resorption wideness, presence or not of root perforations and their size, resistance of the remaining root hard tissues, periodontal status and ability to realize a restorative treatment on the concerned tooth (Nilsson E *et al.*, 2013).

If the tooth is restorable and has a good prognosis, root canal treatment is the therapeutic option as it eliminates the granulation tissue, the necrotic pulp and blood supply of the resorbing cells (Komabayashi T *et al.*, 2012).

Internal resorption presents specific difficulties in shaping and filling of the affected tooth. In teeth with actively resorbing lesions, bleeding from the granulation tissues might impair visibility during instrumentation.

Because of its shape, the resorption defect is usually inaccessible to mechanical instrumentation (Subay R *et al.*, 2018).

Activation of irrigation using the ultrasonic devices facilitates the penetration of sodium hypochlorite to all the areas of the root canal system (Fuss Z *et al.*, 2003). However, even with the use of ultrasonic instruments, bacteria are not completely eliminated from the confined areas.

Thus, Calcium hydroxide, as an inter-appointment dressing should be used to maximize the effect of disinfection procedures. Besides, this intra canal medicament helps to control the bleeding.

After clinical and radiographic examination, several options may be considered depending on the absence or presence of perforation of the radicular wall:

- A. If the lesion is non perforating, the root canal can be completely filled with Gutta Percha. In this case, the defect can be difficult to obturate adequately. Thus, the root canal filling needs to be flowable (thermoplasticized Gutta Percha).
- B. In case of apical perforated lesions in short teeth, the root canal can be completely filled with a bioactive cements as MTA or Biodentine
- C. In situations when the root wall has been perforated giving a communication between the root canal system and the periapical tissue, another treatment approach is the removal of resorptive inflammatory tissue with the surgery and filling of root defect with MTA.

In fact, surgical approach allows to get direct access to the lesion and to perform a mechanical cleaning of the resorption defect.

MTA is biocompatible, bioactive and well tolerated by periradicular tissues. In addition, MTA has superior sealing properties when compared with other materials.

The non conservative treatment is indicated when internal resorption has rendered the tooth untreatable or unrestorable.

CONCLUSION

Endodontic treatment of teeth with perforating internal root resorption is challenging. Selection of the appropriate treatment approach of these cases is essential for successful treatment outcome.

REFERENCES

- Patel, S., & Saberi, N. (2018). The ins and outs of root resorption. *British dental journal*, 224(9), 691-699.
- Nilsson, E., Bonte, E., Bayet, F., & Lasfargues, J. J. (2013). Management of internal root resorption on permanent teeth. *International journal of dentistry*, 2013.
- Calışkan, M. K., & Türkün, M. (1997). Prognosis of permanent teeth with internal resorption: a clinical review. *Dental Traumatology*, 13(2), 75-81.
- Silveira, F. F., Nunes, E., Soares, J. A., Ferreira, C. L., & Rotstein, I. (2009). Double 'pink tooth' associated with extensive internal root resorption after orthodontic treatment: a case report. *Dental Traumatology*, 25(3), e43-e47.
- Bhuvu, B., Barnes, J. J., & Patel, S. (2011). The use of limited cone beam computed tomography in the diagnosis and management of a case of perforating internal root resorption. *International endodontic journal*, 44(8), 777-786.
- Komabayashi, T., & Zhu, Q. (2012). Internal and external resorption in a lower molar with an associated endodontic-periodontic lesion: A case report. *Australian Endodontic Journal*, 38(2), 80-84.
- Subay, R. K., Subay, M. O., & Tuzcu, S. B. (2018). Endodontic management of root perforating internal replacement resorption. *European Journal of Dentistry*, 12(03), 450-453.
- Fuss, Z., Tsisis, I., & Lin, S. (2003). Root resorption—diagnosis, classification and treatment choices based on stimulation factors. *Dental traumatology*, 19(4), 175-182.

Cite This Article: Mkaddem Rania, Mabrouk Rim, Frih Nadia (2022). Clinical Management of Internal Inflammatory Perforating and Non Perforating Root Resorption Associated With an Apical Resorption and a Cystic Lesion: A Case Report. *EAS J Dent Oral Med*, 4(5), 118-122.