

## Case Report

## Coccygectomy: Is it Necessary for Coccydynia? About A Case and Review of the Literature

Youness Mokhchani<sup>1, 2\*</sup>, Abderrafia Rachdi<sup>1, 2</sup>, Abdelhay Rabbah<sup>1, 2</sup>, Jalal Boukhriss<sup>1, 2</sup>, Bouchaib Chafry<sup>1, 2</sup>, Mustapha Boussouga<sup>1, 2</sup>

<sup>1</sup>Department of Orthopedic Surgery and Traumatology II, Mohammed V Military Teaching Hospital, Morocco

<sup>2</sup>Faculty of Medicine and Pharmacy - Mohammed V University -Rabat- 10000, Morocco

### Article History

Received: 28.03.2022

Accepted: 06.05.2022

Published: 28.09.2022

### Journal homepage:

<https://www.easpublisher.com>

### Quick Response Code



**Abstract:** Coccydynia is localized pain in the coccyx, exacerbated when sitting and getting up. The diagnosis is essentially clinical, the interrogation must always seek the notion of trauma in the history. Digital rectal examination is painful when mobilizing the coccyx. Standard X-rays, dynamic X-rays, and Magnetic Resonance Imaging (MRI) are quite important for both positive diagnosis and differential diagnosis. Therapeutic management is multidisciplinary, starting with hygiene measures, medical treatment and manipulation and massage techniques. Coccygectomy is proposed after failure of conservative treatments. Its results are generally good. Its main complication is infection.

**Keywords:** Coccygodynie, coccygectomie, infiltration, radiographies dynamiques.

Copyright © 2022 The Author(s): This is an open-access article distributed under the terms of the Creative Commons Attribution 4.0 International License (CC BY-NC 4.0) which permits unrestricted use, distribution, and reproduction in any medium for non-commercial use provided the original author and source are credited.

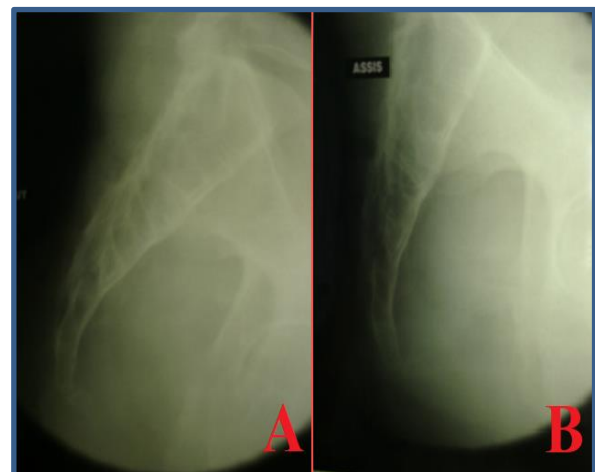
## INTRODUCTION

Coccydynia is a relatively rare condition, the etiology of which is difficult to understand. The traumatic origin is the first to be sought, but the idiopathic form is possible. We report the case of a patient who underwent surgery in our department, after several attempts at topical treatment.

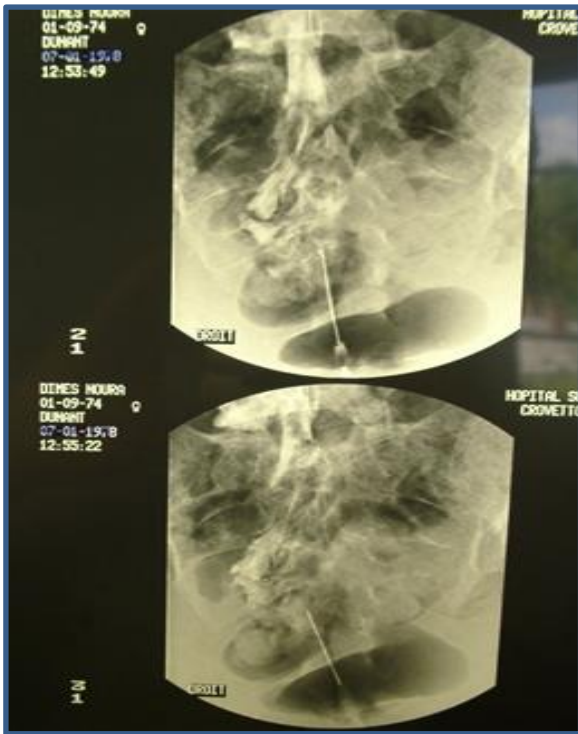## CASE PRESENTATION

A 30-year-old woman, office secretary, otherwise healthy and active without any notion of obesity, and who has suffered for 5 years from atraumatic, disabling, disabling and progressive coccygodynia. These pains are diffuse in nature and increase when sitting and lying down, and have worsened for 3 months after vaginal delivery. After inspection showing no abnormalities other than external hemorrhoids, perianal palpation on the dorsal side causes pain on pressure. During digital rectal examination, which shows normal sphincter tone without palpable resistance, palpation of the coccyx causes pronounced pain. The patient has already benefited from 3 infiltrations of corticosteroids under fluoroscopy, as well as several manipulation sessions by a physiotherapist, but the results were random and transient. After informing the patient and obtaining her consent for the operation, a coccygectomy was

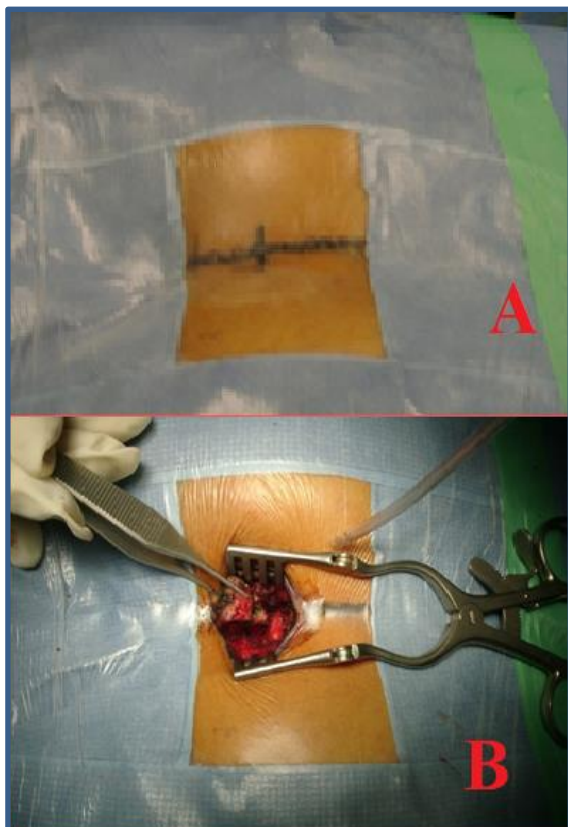
performed under general anesthesia. The evolution was favorable despite sepsis which was controlled by twice-daily local care and antibiotic therapy. The patient is very satisfied after 1 year.



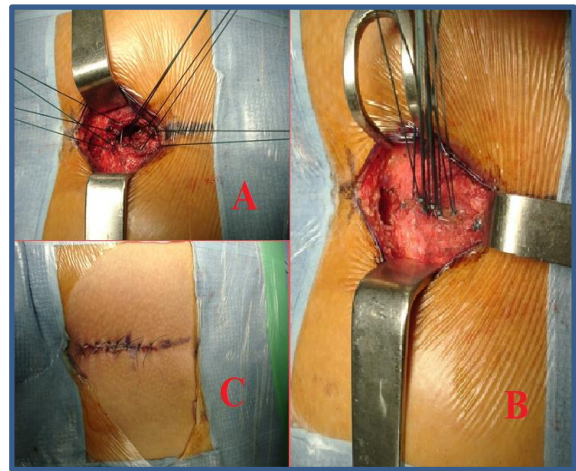
**Figure 1: Standard radiographs: A: Standing profile of the sacrum, B: Sitting profile**



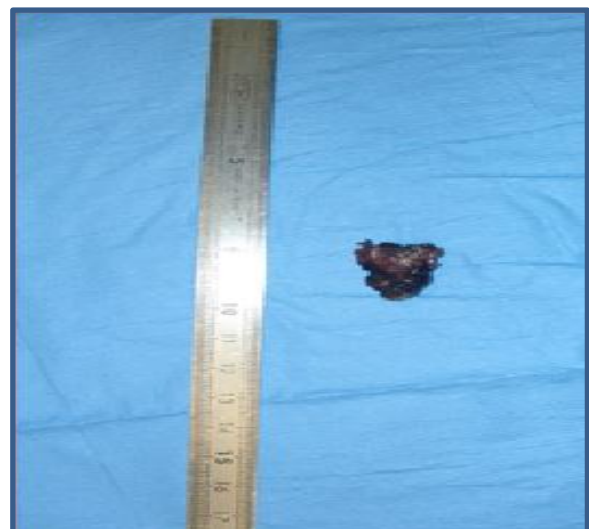**Figure 2: Image intensifier-guided corticosteroid infiltration**




**Figure 3: Intraoperative images: A: Way first, B: Meticulous excision to avoid visceral opening**



**Figure 4: Intraoperative images: A and B: Overcoat closure, C: Surgical scar**



**Figure 5: Intraoperative image showing the excised coccyx**



**Figure 6: Standard X-ray of the excised coccyx**

## DISCUSSION

Coccyx pain, or coccydynia, is pain felt in the tailbone area. This pain may be continuous, and it is worse when sitting and standing up, as well as when

extending the hip joint from a sitting position (bending back). It also intensifies when touched, whether by external or internal touch (rectal examination). A distinction is generally made between acute coccydynia (lasting for less than 8 weeks) and chronic, persistent coccydynia. The physical examination is performed in the prone position. It looks for the presence of a pilonidal sinus (indirect sign of a coccygeal spine) in the gluteal fold [4]. The examiner's index finger follows the gluteal fold until about 0.5cm behind the anus, prints a slight flexion upwards and backwards, if the coccyx is injured, the patient will feel an exquisite and sharp pain. Palpation of a mass may suggest a bony spicule or a causal tumor. Digital rectal examination can be painful when mobilizing the coccyx [5]. The examination must be completed by an examination of the lumbar spine, pelvis and lower limbs [6].

A simple standing lateral X-ray centered on the coccyx may be sufficient in cases of hyperalgesic acute coccydynia secondary to a fracture or microcrystalline arthritis. It can also be fractures of the sacrum, which cause pain in the same area. These fractures heal within weeks, without treatment. Dynamic radiographs measure the sagittal rotation of the pelvis and the coccygeal angle of incidence. The normal angle of mobility in flexion is between 0 and 25°, in one third of cases, the coccyx moves in extension with an angle of 15° maximum. At the end of this examination, the responsible lesions encountered are essentially:

**Posterior coccygeal dislocation:** This accounts for 20 to 25% of coccyx pain cases. hyper mobility: defined as abnormal flexion of the coccyx in a seated position (angle of more than 25 to 30°).

**The coccygeal spine:** 15% of cases of coccydynia). The thorn can be seen on palpation.

MRI can demonstrate inflammation of the sacrococcygeal region, soft tissues or nerve damage (compression of the pudendal nerve, schwannomas) [5]. It can also eliminate some underlying pathologies such as chordomas, and highlight the local consequences of a possible dislocation.

The primary cause of coccydynia is trauma. It can be caused by a fall on the buttocks, childbirth (the coccyx is moved by the passage of the baby), or even repeated microtraumas (for example in motorcyclists or cyclists who suffer shocks while sitting). Other causes include:

Overweight or obesity: which may be responsible for the posterior dislocation. The very anatomy of the coccyx (some forms are more often associated with pain).

More rarely, symptoms are due to a tumour, infection or inflammation of the sacrococcygeal joint.

The management of coccydynia is generally multidisciplinary, and begins with rest for at least 8 weeks, and advice concerning posture in a seated position (modify the supports to avoid pain, even use a hollow cushion to relieve pressure, especially after a fall). Long trips by car, the practice of some sports (cycling, horse riding, etc.) are not recommended. Applying heat or cold to the painful area may also be beneficial. Laxatives should be prescribed to avoid constipation which can make the pain worse. Nonsteroidal anti-inflammatory drugs can be effective in the case of the acute attack, this effectiveness directs the diagnosis towards a thorn of the coccyx with an inflammation of the surrounding soft tissues. The use of intranasal calcitonin (TBS) for the treatment of coccyx fractures has been described recently [7, 8]. These studies have reported satisfactory results, with improvement in pain and good tolerance. Several authors have described manipulation techniques based on the stretching of the levators and the external sphincter with or without mobilization of the coccyx by external rectal maneuver [2, 9-11]. These are effective in cases of levator ani spasms [12], however the results are mediocre in the context of severe pudendal nerve syndrome [13]. Neurostimulation also gives encouraging results, it can be used either externally or internally (cutaneous probe and intrapelvic probe).

Pericoccygeal and intradiscal infiltrations are known for their effectiveness [3, 12, 14, 15], they are radioguided, using 2.5% prednisolone acetate as a reference product, associated or not with anesthetics local. Additionally, there are several publications that have demonstrated the effectiveness of Impar node infiltration. It is also important to note that despite the risk of rectal perforation which appears obvious due to the anatomical situation of this lymph node, no complication has been reported in the literature.

Coccygectomy is a possible procedure for coccydynia resistant to conservative treatment [1]. In the literature, several studies have reported good results [16, 17]. It has been shown that the association of secondary low back pain with disc degeneration limits the indication for coccygectomy. The latter is intended exclusively for disabling instabilities (dislocations and hypermobility) not relieved by other means. It brings good and excellent results in more than 90% of cases. Improvement after coccygectomy appears in the second or third month, sometimes only after six to ten months. In some rare cases, it takes one to two years before the final cure. This long delay could be attributed to the presence of deafferentation pain (phantom limb syndrome). Wound infection is the most common postoperative complication due to the anatomical location of the coccyx. It is for this reason that the surgical procedure requires colonic preparation by



residue-free diet for 48 hours, rectal lavage, antibiotic prophylaxis for 48 hours, and finally rigorous asepsis by perineal preparation. The intervention consists of resecting the unstable portion of the coccyx. In the case of a spicule, its distal end is resected at the same time as the associated pilonidal sinus is removed. The procedure is performed under general anesthesia through a small incision in the intergluteal fold. The posterior surface of the coccyx is exposed and the dissection is done in contact with the bone. Despite pre- and postoperative aseptic precautions and antibiotic prophylaxis for 48 hours, infection can complicate 2 to 3% of procedures. In addition, it should know that the way of sitting is fundamental. It has to choose the least uncomfortable seat, avoid sitting for a long time, knows how to sit on his buttocks, on his thighs, or in front of the seat. The buoy can help in case of resistant pain. Tricyclics are sometimes useful in case of idiopathic coccydynia unresponsive to injections or manual treatment or in case of surgical failure [18].

## CONCLUSION

Coccydynia is a fairly rare pathology, knowledge of the anatomy and biomechanics of the coccyx makes it possible to better understand the mechanism of the lesions responsible, the diagnosis is essentially clinical and the therapeutic management is multidisciplinary, coccygectomy is indicated after failure of the conservative treatments.

## REFERENCES

- Cheng, S. W., Chen, Q. Y., Lin, Z. Q., Wang, W., Zhang, W., Kou, D. Q., ... & Peng, L. (2011). Coccygectomy for stubborn coccydynia. *Chinese journal of traumatology*, 14(01), 25-28.
- Maigne, J. Y., & Chatellier, G. (2001). Comparison of three manual coccydynia treatments: a pilot study. *Spine*, 26(20), E479-E483.
- Fogel, G., Cunningham, P., & Coccygodynia, S. (2004). Esses: évaluation et gestion. *J Am Acad Orthop Surg*, 12, 49-54.
- Maigne, J. Y. (2014). Entretien, coccygodynie: questions posées au docteur Jean Yves Maigne. *Douleurs évaluation – diagnostic–traitement*, 15, 24-26.
- Trouvin, A. P., Goeb, V., Vandhuick, T., Michelin, P., Lequerré, T., & Vittecoq, O. (2013). Intérêt de l'IRM dans les coccygodynies sur luxations sacro-coccygiennes. *Revue du rhumatisme*, 80(2), 176-178.
- Buttaravoli, P. (2012). Coccyx fracture: (tail bone fracture) minor emergencies, Third Edition, 410–1 [Chapter106].
- Maigne, J. Y., Pigeau, I., & Roger, B. (2012). Magnetic resonance imaging findings in the painful adult coccyx. *European Spine Journal*, 21(10), 2097-2104.
- Visser, E. J., & Kwei, P. L. (2006). Salmon calcitonin in the treatment of post herpetic neuralgia. *Anaesthesia and intensive care*, 34(5), 668-671.
- Lyrithis, G. P., & Trovas, G. (2002). Analgesic effects of calcitonin. *Bone*, 30(5), 71-74.
- Wray, C. C., Easom, S., & Hoskinson, J. (1991). Coccydynia. Aetiology and treatment. *The Journal of Bone and Joint Surgery. British volume*, 73(2), 335-338.
- Maigne, R. (1961). Expansion scientifique française. Les manipulations vertébrales, 3rd ed., Paris; 180.
- Segura, J. W., Opitz, J. L., & Greene, L. F. (1979). Prostatitis, prostatitis or pelvic floor tension myalgia?. *The Journal of Urology*, 122(2), 168-169.
- Amarenco, G., Bensignor, M., Guerineau, M., Labat, J. J., & Robert, R. (1999). Algies pelvi-périnéales: physiopathologie diagnostic prise en charge thérapeutique, no 385. KS; p. 21–40.
- Evans, P. J. D., Lloyd, J. W., & Jack, T. M. (1981). Cryoanalgesia for intractable perineal pain. *Journal of the Royal Society of Medicine*, 74(11), 804-809.
- Gupta, D., Mishra, S., Thulkar, S., & Bhatnagar, S. (2009). Ultrasonographic-assisted ganglion impar neurolysis. *Anesthesia & Analgesia*, 108(6), 1995-1996.
- Bayne, O. M. A. R., Bateman, J. E., & Cameron, H. U. (1984). The influence of etiology on the results of coccygectomy. *Clinical orthopaedics and related research*, (190), 266-272.
- Traub, S., Glaser, J., & Manino, B. (2009). Coccygectomy for the treatment of therapy-resistant coccygodynia. *Journal of surgical orthopaedic advances*, 18(3), 147-149.
- Maigne, J. Y., Lagauche, D., & Doursounian, L. (2000). Instability of the coccyx in coccydynia. *The Journal of Bone and Joint Surgery. British volume*, 82(7), 1038-1041.

**Cite This Article:** Youness Mokhchani, Abderrafia Rachdi, Abdelhay Rabbah, Jalal Boukhriss, Bouchaib Chafry, Mustapha Boussouga (2022). Coccygectomy: Is It Necessary for Coccydynia? About A Case and Review of the Literature. *East African Scholars J Med Surg*, 4(9), 189-192