

Case Report

Arthrodesis of the Ankle by Retrograde Nail Associated with an Iliac Corticocancellous Bone Graft and a Femoral Head Allograft after Failure of a Total Ankle Prosthesis: A Case Report

Aba'a Nguema Davy Gaël^{1*}, Bah Thierno Souleymane¹, Kabwe Chipalo¹, Lahrach Kamal¹, Marzouki Amine¹, Boutayeb Fawzi¹

¹Department of Traumatology and Orthopedics of CHU Hassan II of Fez, Morocco

Article History

Received: 18.10.2022

Accepted: 27.11.2022

Published: 14.12.2022

Journal homepage:

<https://www.easpublisher.com>

Quick Response Code

Abstract: For several years, the surgical treatment of post-traumatic osteoarthritis of the ankle was essentially based on arthrodesis. Currently, ankle arthroplasty has become a reliable alternative with the development of new prostheses. However, the total ankle prosthesis cannot be offered to all patients and it is often a source of medium and long-term complications. The management of these complications, in particular that of the loosening of the prosthesis, is generally done by a definitive treatment by arthrodesis after removal of the prosthesis. It is necessary to combine it with a bone graft in order to fill the gaps left after the removal of the prosthesis and thus allow consolidation with fixation of the joint.

Keywords: post-traumatic osteoarthritis, ankle arthroplasty, prosthesis.

Copyright © 2022 The Author(s): This is an open-access article distributed under the terms of the Creative Commons Attribution **4.0 International License (CC BY-NC 4.0)** which permits unrestricted use, distribution, and reproduction in any medium for non-commercial use provided the original author and source are credited.

INTRODUCTION

Arthrodesis and total prosthesis of the ankle are indicated in the surgical treatment of osteoarthritis of the ankle, of post-traumatic origin in the majority of cases [1].

Arthrodesis is a surgical procedure that consists of the fusion of a joint in the correct position and permanently. In the case of the ankle; it involves fusion of the talocrural joint [1]. It is the oldest and remains the most widespread of the two treatment options [2]. It applies to all patients and is often associated with good results in the medium and long term despite its irreversible nature and all the constraints associated with it [3, 5].

Ankle arthroplasty, performed since the 1970s, has a bad reputation due to numerous failures encountered in the implantation of the first prostheses [1, 4-6]. This trend is increasingly reversing since the development of second and third generation ankle prostheses [1]. Nowadays, ankle arthroplasty is now considered a reliable alternative to arthrodesis [1, 5]. But its indications are limited and patients are selected on a case-by-case basis [6-9]. In the event of complications from an ankle prosthesis, conversion of the latter into arthrodesis is always possible [10].

We report the case of an ankle arthrodesis associated with a bone graft indicated in front of a loosening of total ankle prosthesis.

OBSERVATION

66-year-old female patient, single without children, undergoing treatment for hepatic steatosis, with a history of right bimalleolar closed fracture which occurred in 2013 following a RTA. She underwent ORIF using a one third (1/3) 6-hole tubular plate for the lateral malleolus and screwing associated with pinning of the internal malleolus. The evolution was marked by chronic disabling ankle pain with significant limitation of walking distance. Faced with the persistence and worsening of these symptoms, the decision to perform arthroplasty by total ankle prosthesis was taken. Beforehand, the screw and pin were removed from the malleolus. A year later, in 2014, via an anteromedial approach, she received a non-cemented total ankle prosthesis of the Salto type, size 1 tibial component, size 1 talar component and mobile polyethylene spacer of size 5, with a calcaneal tendon lengthening tenotomy. In the postoperative period, there was persistent residual ankle pain associated with joint instability causing functional impotence. Weight bearing and walking was impossible. Then the stiffness set in. The patient was

never able to use her prosthesis. This symptomatology motivated the patient to consult again in our service.

On admission, the clinical examination found walking with the help of a cane, impossible monopodal support, an ankle without deformation with good skin condition. We noted the presence of three scars specific to the old approaches of previous surgical procedures (figure 1). There were no tender points on palpation. All joint amplitudes were blocked, namely dorsiflexion, plantar flexion, eversion and inversion. Flexion and extension of the toes were well preserved. Neurovascular examination was normal. The standard x-ray of the ankle performed showed a radiolucent periprosthetic line around the tibial implant of the prosthesis with a distal tibiofibular synostosis. The one third (1/3) 6- hole tubular plate was in place on the lateral malleolus (Figure 2). In view of these images, the diagnosis of loosening of the prosthesis was made, hence the indication for definitive treatment by arthrodesis after removal of the prosthesis. The preoperative assessment was normal.

The patient was admitted to the operating room, under general anesthesia, in the supine position

on an ordinary table, with a pneumatic tourniquet at the root of the limb. Initially, by reworking the old anteromedial approach centered on the ankle (figure 3), after resection of the anterior edge of the tibial pilon using a bone chisel, removal of the three components of the prosthesis was made (figures 4 and 5) in this order: polyethylene, tibial implant and talar implant. We noted the presence of a large bone defect (Figure 6) after curettage. In a second approach, via a plantar approach centered on the calcaneus, after identifying the point of introduction of the nail and progressive reaming of the route, we placed a retrograde centro-medullary nail of size 10/200, locked distally and proximally (Figure 7). Then via a postero-external approach centered on the iliac crest (figure 8), a corticocancellous bone graft intended to fill the gap was removed. Finally, a corticocancellous bone graft associated with a femoral head allograft (figure 9) was performed to fill the bone defect around the nail. Final closure was made in layers and an aspirative drain was added. Immobilisation with a boot splint was performed after dressing. Postoperative control radiographs showed a well-centered nail (figure 10). The immediate post-operative follow-up was without incident.

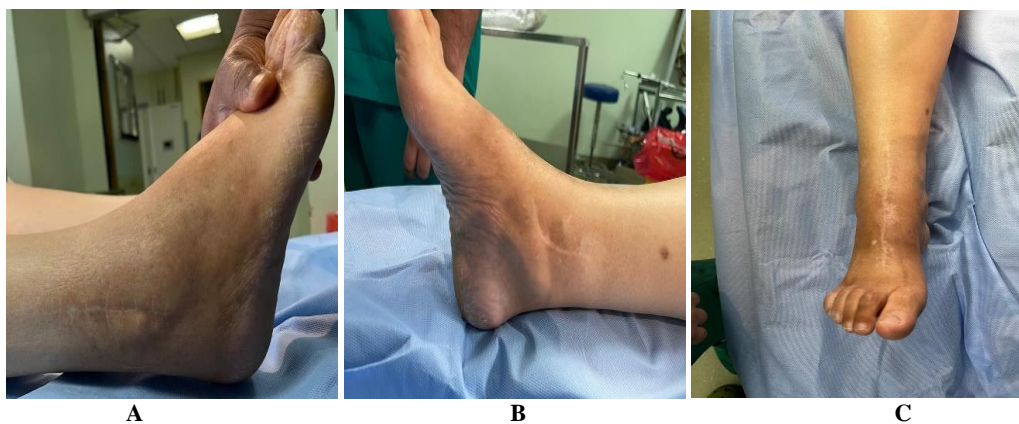


Figure 1: Skin condition and scars from old approaches

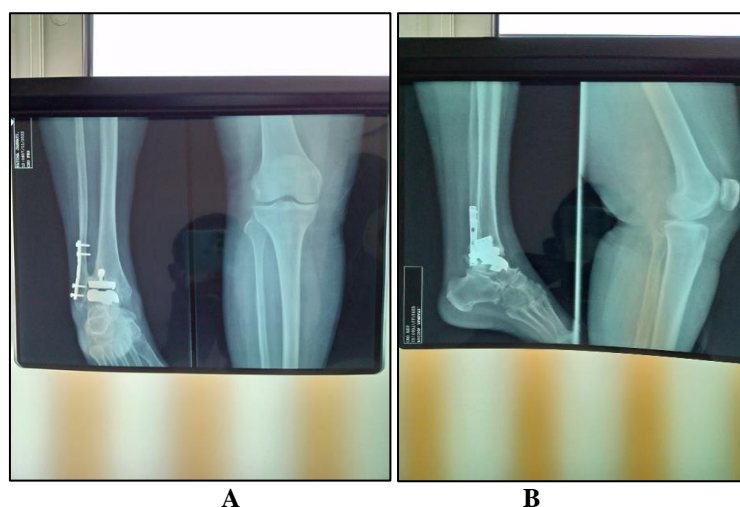


Figure 2: Standard preoperative X-rays showing the one third (1/3) tubular plate in place and the loosening of the tibial implant from the prosthesis

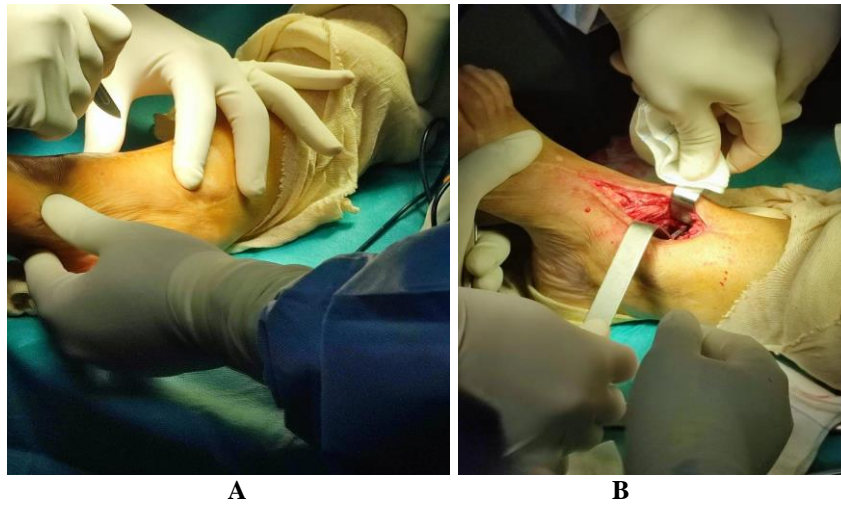


Figure 3: Revision of the old anteromedial approach and exposure of the prosthesis

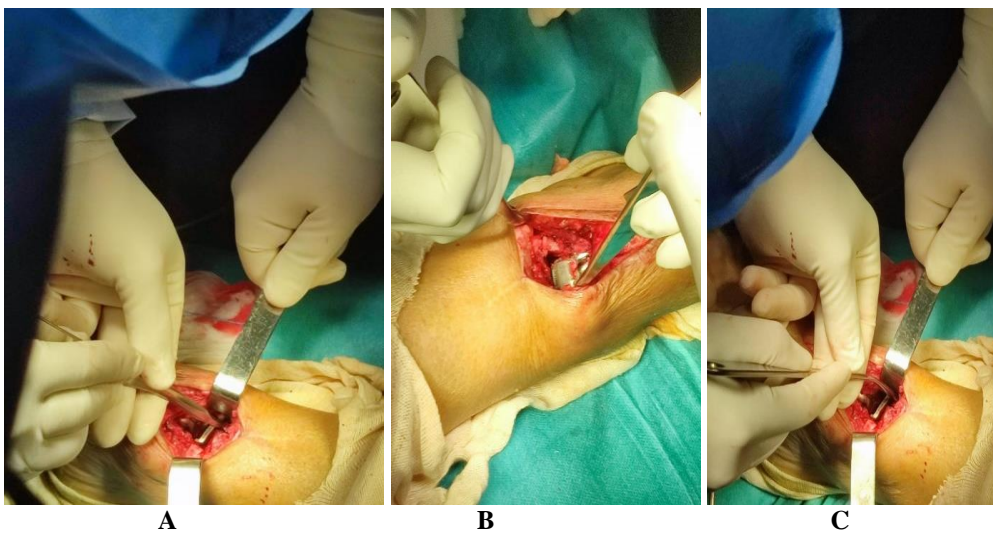


Figure 4: Removal of the various prosthetic implants

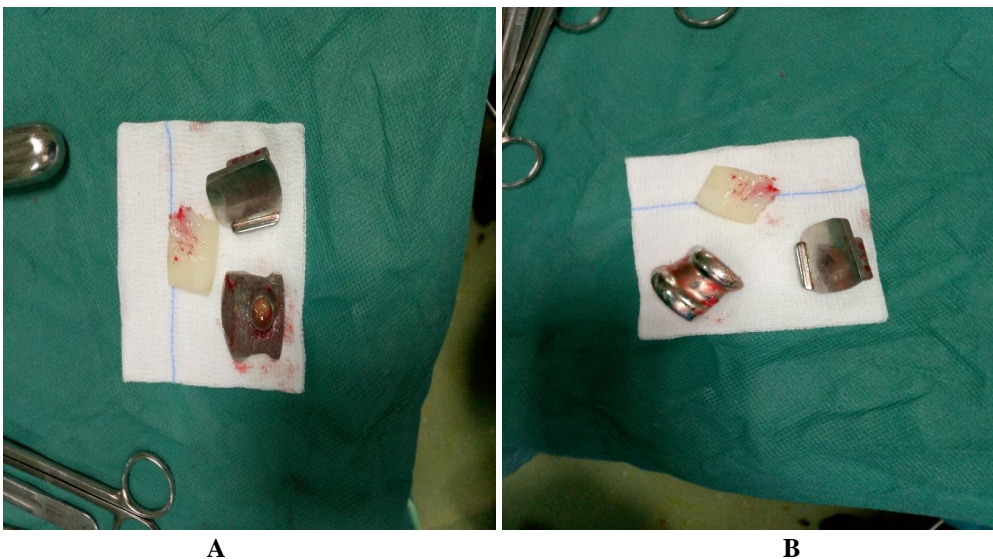

Figure 5: The different prosthetic implants removed

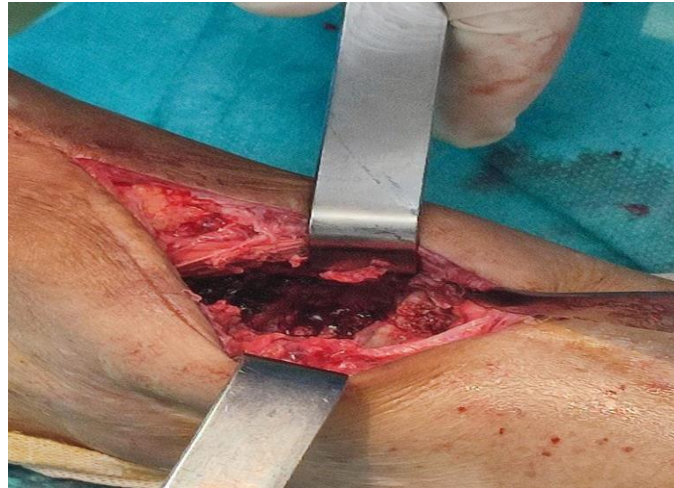


Figure 6: Bone gap after removal of the prosthesis

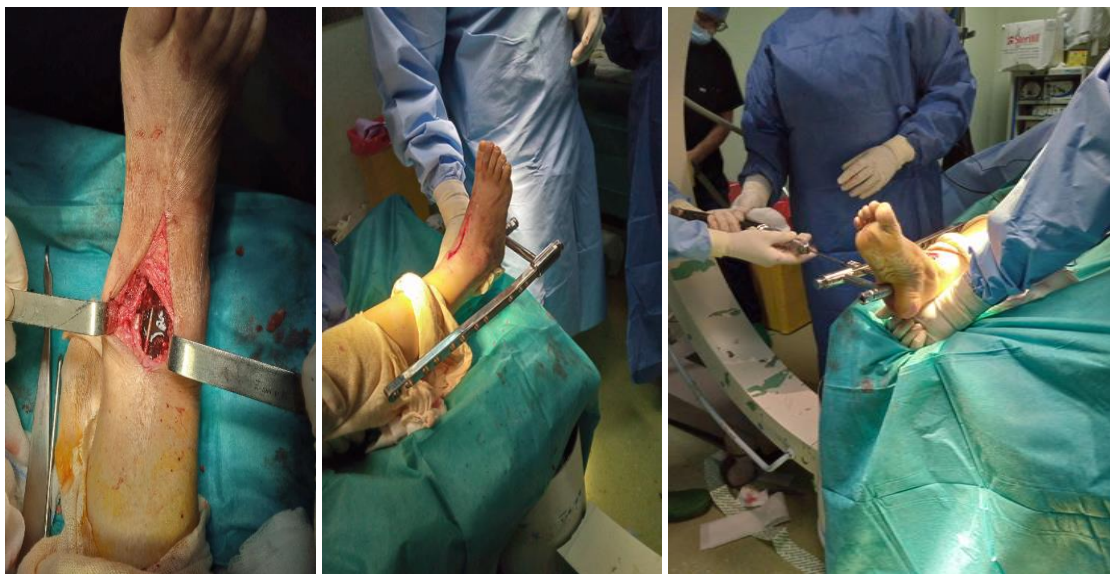


Figure 7: Implantation of the retrograde nail by transplantar approach

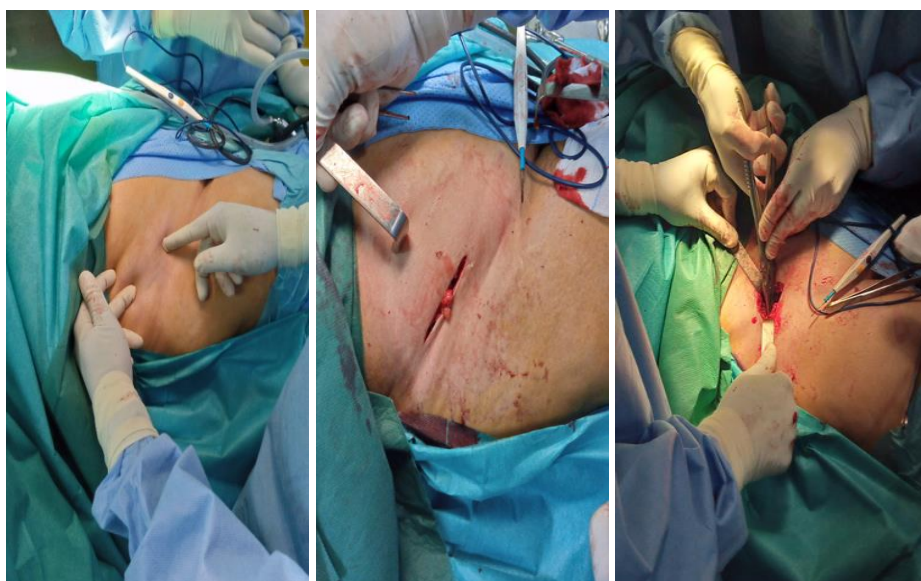


Figure 8: Harvesting of iliac corticocancellous bone graft

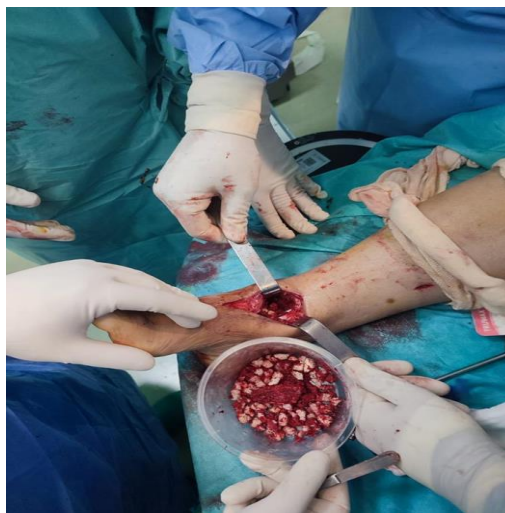

Figure 9: Femoral head allograft

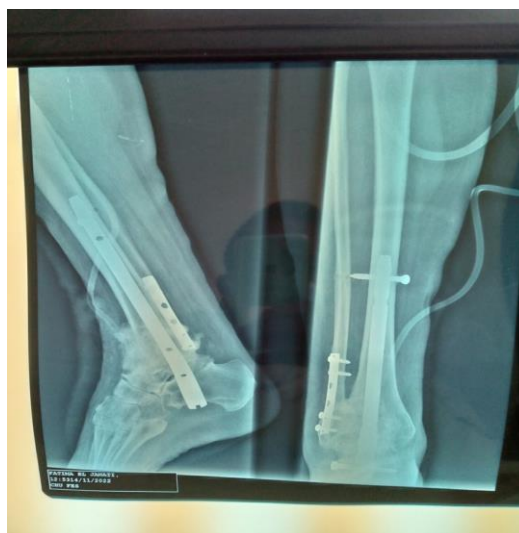

Figure 10: Standard post-operative control radiographs showing the retrograde nail

DISCUSSION

Arthrodesis is still considered the "gold standard" of surgical treatment for ankle osteoarthritis. It is indicated in all advanced degenerative diseases of the ankle joint [2-4]. The sequelae of trauma are the most frequent causes [11, 12]. In the case of our patient, the osteoarthritis was post-traumatic; following a bimalleolar fracture. Other aetiologies like inflammatory arthropathies may also be responsible. The goal of arthrodesis in the treatment of osteoarthritis is to effectively relieve pain and maintain the joint in a functional position. But in the long term, it has unfavorable repercussions on the surrounding joints. These are due to a compensatory mechanism which leads to a greater solicitation which will expose them early to degeneration, with the consequence of a progressive limitation of the efficiency of walking [13, 14]. This development may partly justify the growing popularity of ankle arthroplasty. It is increasingly proposed by surgeons in the treatment of osteoarthritis. Nowadays, new ankle prostheses give better results [15, 16]. They have the advantage of offering joint mobility

unlike arthrodesis. They thus preserve the underlying joints, which is a significant factor, especially for active people. In short and medium term evaluations, 60-90% of patients are satisfied and the survival rate of the prosthesis varies from 70-90% between 5 and 10 years [15, 17-19]. However, the fitting of the ankle prosthesis must first meet many criteria: the absence of extra-articular axial deformation, the existence of satisfactory mobility and good tibial and talar bone stock, etc. There are also absolute contraindications to ankle prosthesis [6-9]. In short, it is a difficult procedure that requires learning and an experienced ankle surgeon. In the long term, we can have a number of complications. The most common are malleolar fractures and loosening [14, 18]. Some of them can be treated by keeping the prosthesis in place. But for loosening, as was the case for our patient, revision or conversion to arthrodesis is indicated after removal of the prosthesis [10, 20]. Several techniques can be applied [21], but in all cases it is necessary to perform a bone graft in order to fill the large bone defects left after the removal of the prosthesis [10, 20]. In our case, we performed

arthrodesis by a retrograde centromedullary nail with an iliac corticocancellous graft associated with a femoral head allograft. Despite this additional difficulty, the outcome is often favourable, marked by consolidation in 80-90% of cases [10].

CONCLUSION

Arthrodesis still occupies a place of choice in the management of post-traumatic osteoarthritis of the ankle, despite the development and the encouraging results of total ankle prosthesis. Indeed, when it is not offered as first intention because of its irreversible nature, it is probably the best option in the event of failure or complications of the prosthesis.

REFERENCES

1. Norvell, D. C., Ledoux, W. R., Shofer, J. B., Hansen, S. T., Davitt, J., Anderson, J. G., ... & Sangeorzan, B. J. (2019). Effectiveness and safety of ankle arthrodesis versus arthroplasty: a prospective multicenter study. *The Journal of Bone and Joint surgery. American Volume*, 101(16), 1485-1494.
2. Trouillier, H., Hänsel, L., Schaff, P., Rosemeyer, B., & Refior, H. J. (2002). Long-term results after ankle arthrodesis: clinical, radiological, gait analytical aspects. *Foot & ankle international*, 23(12), 1081-1090.
3. Bertrand, M., CHARISSOUX, J. L., Mabit, C., & ARNAUD, J. P. (2001). Etude de la tolérance à long terme de l'arthrodèse talo-crurale. *Revue de chirurgie orthopédique et réparatrice de l'appareil moteur*, 87(7), 677-684.
4. Lord, G., & Marotte, J. H. (1980). L'arthroplastie totale de cheville. Expérience sur 10 ans, à propos de 25 observations personnelles [Total ankle replacement (author's transl)]. *Rev Chir Orthop Réparatrice Appar Mot*, 66(8), 527-30.
5. Henne, T. D., & Anderson, J. G. (2002). Total ankle arthroplasty: a historical perspective. *Foot and ankle clinics*, 7(4), 695-702.
6. Gould, J. S., Alvine, F. G., Mann, R. A., Sanders, R. W., & Walling, A. K. (2000). Total ankle replacement: a surgical discussion. Part I. Replacement systems, indications, and contraindications. *American journal of orthopedics (Belle Mead, NJ)*, 29(8), 604-609.
7. Crevoisier, X., & Assal, M. (2005). Les prothèses de cheville. La motivation d'une collaboration interuniversitaire [Ankle arthroplasty. Rationale for interfaculty collaboration]. *Rev Med Suisse*, 1(46), 2973-7.
8. Saltzman, C. L. (2000). Perspective on total ankle replacement. *Foot Ankle Clin*, 5(4), 761-75.
9. Hayes, B. J., Gonzalez, T., Smith, J. T., Chiodo, C. P., & Bluman, E. M. (2016). Ankle arthritis: you can't always replace it. *JAAOS-Journal of the American Academy of Orthopaedic Surgeons*, 24(2), e29-e38.
10. Carlsson, Å. S., Montgomery, F., & Besjakov, J. (1998). Arthrodesis of the ankle secondary to replacement. *Foot & ankle international*, 19(4), 240-245.
11. Lindsjö, U. L. F. (1985). Operative treatment of ankle fracture-dislocations: a follow-up study of 306/321 consecutive cases. *Clinical Orthopaedics and Related Research®*, 199, 28-38.
12. Thomas, R. H., & Daniels, T. R. (2003). Ankle arthritis. *JBJS*, 85(5), 923-936.
13. Coester, L. M., Saltzman, C. L., Leupold, J., & Pontarelli, W. (2001). Long-term results following ankle arthrodesis for post-traumatic arthritis. *JBJS*, 83(2), 219-28.
14. Wu, W. L., Su, F. C., Cheng, Y. M., Huang, P. J., Chou, Y. L., & Chou, C. K. (2000). Gait analysis after ankle arthrodesis. *Gait & posture*, 11(1), 54-61.
15. Buechel Sr, F. F., Buechel Jr, F. F., & Pappas Jr, M. J. (2003). Ten-year evaluation of cementless Buechel-Pappas meniscal bearing total ankle replacement. *Foot & ankle international*, 24(6), 462-472.
16. Wood, P. L. R., & Deakin, S. (2003). Total ankle replacement: the results in 200 ankles. *The Journal of bone and joint surgery. British volume*, 85(3), 334-341.
17. Kofoed, H., & Lundberg-Jensen, A. (1999). Ankle arthroplasty in patients younger and older than 50 years: a prospective series with long-term follow-up. *Foot & ankle international*, 20(8), 501-506.
18. Anderson, T., Montgomery, F., & Carlsson, Å. (2003). Uncemented STAR total ankle prostheses: three to eight-year follow-up of fifty-one consecutive ankles. *JBJS*, 85(7), 1321-1329.
19. Wood, P. L. R., & Deakin, S. (2003). Total ankle replacement: the results in 200 ankles. *The Journal of bone and joint surgery. British volume*, 85(3), 334-341.
20. Gross, C. E., Lewis, J. S., Adams, S. B., Easley, M., DeOrio, J. K., & Nunley, J. A. (2016). Secondary arthrodesis after total ankle arthroplasty. *Foot & Ankle International*, 37(7), 709-714.
21. Yasui, Y., Hannon, C. P., Seow, D., & Kennedy, J. G. (2016). Ankle arthrodesis: A systematic approach and review of the literature. *World journal of orthopedics*, 7(11), 700-708.

Cite This Article: Aba'a Nguema Davy Gael, Bah Thierno Souleymane, Kabwe Chipalo, Lahrach Kamal, Marzouki Amine, Boutayeb Fawzi (2022). Arthrodesis of the Ankle by Retrograde Nail Associated with an Iliac Corticocancellous Bone Graft and a Femoral Head Allograft after Failure of a Total Ankle Prosthesis: A Case Report. *East African Scholars J Med Surg*, 4(11), 245-250