

## Case Report

## Management of a Type I and Type II of Dens Invaginatus on Maxillary Teeth: A Case Report

Elleuch Oumaima<sup>1,2\*</sup>, Kallel Ines<sup>1,2</sup>, Douki Nabihah<sup>1,2</sup><sup>1</sup>Department of Conservative Dentistry and Endodontics, Department of Dental Medicine, EPS Sahloul, Sousse, Tunisia<sup>2</sup>Faculty of Dental Medicine, Oral Health and Oro-Facial Rehabilitation Laboratory Research (LR12ES11), University of Monastir, 5019 Monastir, Tunisia**Article History**

Received: 10.12.2022

Accepted: 19.01.2023

Published: 27.01.2023

**Journal homepage:**<https://www.easpublisher.com>**Quick Response Code**

**Abstract:** Dens invaginatus is a tooth anomaly described by a development of an infolding structure into the root canal. Its treatment is challenging because of the difficulties observed in different types of this malformation. An early diagnosis face to crown morphologic abnormalities is the most effective mean of treatment. This paper focuses on importance of the clinical and radiological examination of Dens invagination and describes different therapeutic approach through several cases.

**Keywords:** Dens in dent, invagination, CBCT, endodontic treatment, preventive therapeutic, malformation.

**Copyright © 2023 The Author(s):** This is an open-access article distributed under the terms of the Creative Commons Attribution **4.0 International License (CC BY-NC 4.0)** which permits unrestricted use, distribution, and reproduction in any medium for non-commercial use provided the original author and source are credited.

### INTRODUCTION

Dens invaginatus is a malformation frequently observed in the superior lateral incisors [1]. It consists of an infolding of a tooth enamel into the inner portion of dentin during tissue development [2]. Its main characteristic is an unusual crown invagination morphology and the occurrence of deep pit or a prominent cingulum at the palatal surface [3].

The classification proposed by Oehlers is the most used in which 3 types of dens invagination were proposed according to the depth of the defect relative to the cemento-enamel Junction and communication with periodontal ligament [4]. In fact, the type I invagination is generally confined to the crown without exceeding the cemento-enamel junction, the type II is an extension of the invagination into the root canal but do not penetrate the periodontal ligament and finally the type III is an extension of the invagination structure into the root canal with no communication with the pulp and exit laterally or apically [5].

This anomaly is unfortunately underdiagnosed so an early detection should be established due to the high risk of pulpal and periapical latent complications [1].

The treatment of Dens invagination considered difficult due the complexity of the tooth anatomy and depends on the depth of this structure into the root canal. It can be a simple prophylactic treatment by sealing the invagination an endodontic approach or surgical procedure [6].

The purpose of this paper is to describe the management of type I and Type II of dens invaginatus in maxillary lateral incisors and canines.

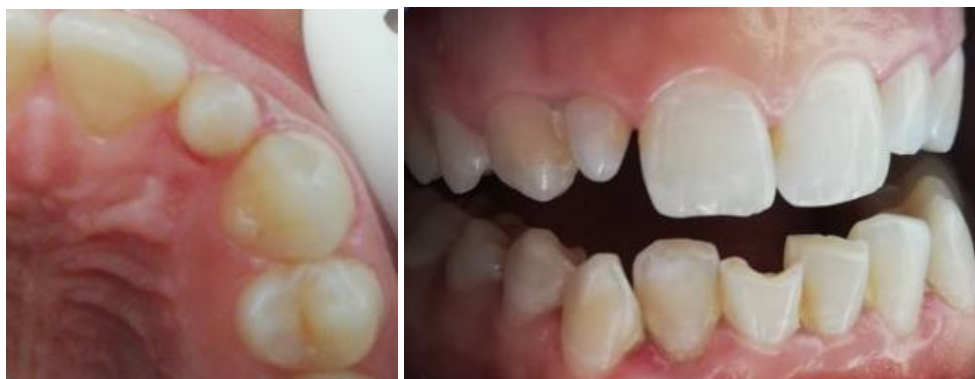### CASE REPORT

Her dentist for evaluation and management of an emergency referred a female patient of 22 years of age without a history of compromising systemic diseases to our clinical hospital. The patient reported acute pain for the previous 24 hours, localized in the upper right lateral incisor [12]. Extra oral clinical examination revealed no facial asymmetry.

The intraoral examination revealed an intact tooth with a fusiform crown (Figure 1 and 2), the Horizontal and vertical percussion tests revealed a highly sensitive tooth. The tooth did not respond to cold test, heat and electric pulp testing.

\*Corresponding Author: Elleuch Oumaima

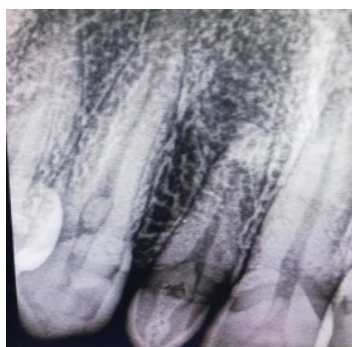Department of Conservative Dentistry and Endodontics, Department of Dental Medicine, EPS Sahloul, Sousse, Tunisia



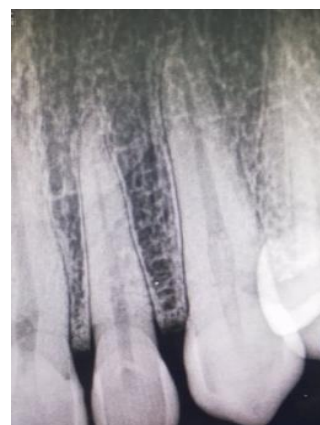**Figure 1 and 2: Preoperative photography of the clinical case, fusiform crown of the right lateral upper incisor [12]**

A periapical radiograph from revealed the presence of enamel opacity structures invaginated exceeding the enamel cement junction and a periapical radiolucency associated with this tooth (figure 3). Based on this evaluation, the diagnosis for tooth was an acute apical periodontitis and a type II of dens invaginatus.

Considering this atypical form of the cingulum, a dental invagination was suspected. A retro alveolar radiograph showed enamel opacity structure which suspect a type I of dens invaginatus on the lateral incisor and type II on the both canines [18, 13] (figure 5).



**Figure 3: Retroalveolar radiograph showing an invagination structure exceeding the enamel cement junction on the 12 and opacity structure on the canine exceeding the enamel cement junction**



**Figure 5: A tiny invagination which does not overextend the cement enamel junction**

In order to deepen our clinical observation, we noticed an alteration of the morphology of the buccal aspect with a prominent cingulum a deep pit which was limited to the enamel on the contralateral lateral incisor [18] (figure 4) and both on the two upper canines. They were asymptomatic with no painful vertical and horizontal percussion.

A Cone beam computed tomography was carried out as a complementary examination and to establish an appropriate care plan. It revealed on sagittal and coronal sections an abnormal crown and root canal morphology simulating a tooth inside the root canal of the 12 as well as a periapical radiolucency with a buccal cortex perforation apically of this lateral incisor.



**Figure 4: A deep pit which was limited to the enamel on the contralateral lateral incisor [18]**

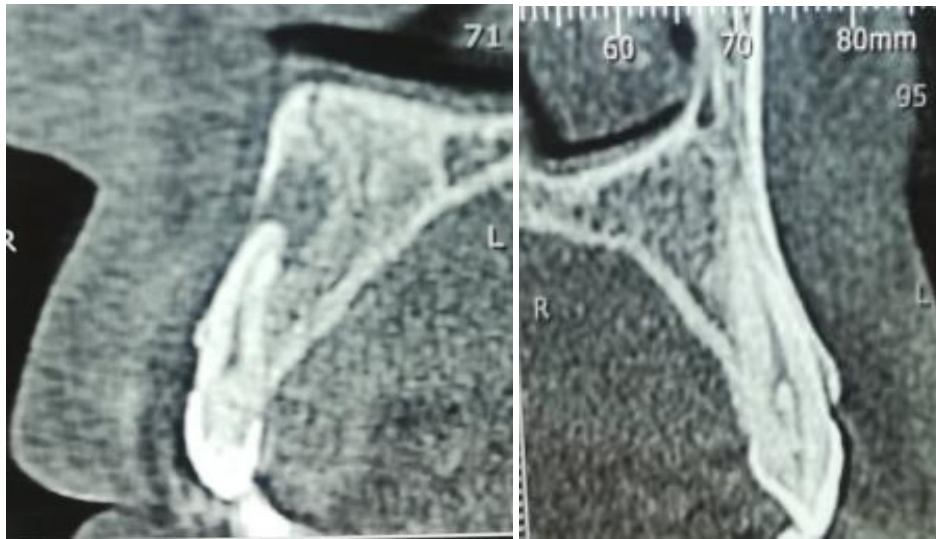
The path of this invagination exceeding the cement enamel junction and above the half of the root canal was detected on sagittal section .the axial section showed a single root apex at the end of the main root canal. It confirmed the type II of dens invaginatus.

For the contralateral lateral incisor, the radiological examination showed a tiny invagination which does not overextend the cement enamel junction. So according to the OEHLERS classification, it is diagnosed with a type I of dens invaginatus (figure 6).

For the two upper canines, a radiopaque infolding of enamel with a continuity of the pulp

chamber and exceeding the cement enamel junction was discerned but without any periapical lesions. So we

confirm the diagnosis of the type II OF dens invaginatus (Figure 7).



**Figure 6 and 7:** The CBCT showed a type II of the invagination which extended the cemento enamel junction in the root canal of the 12, periapical lesion with a rupture of the vestibular cortical bone , the invagination type II on the canine with no periapical complication

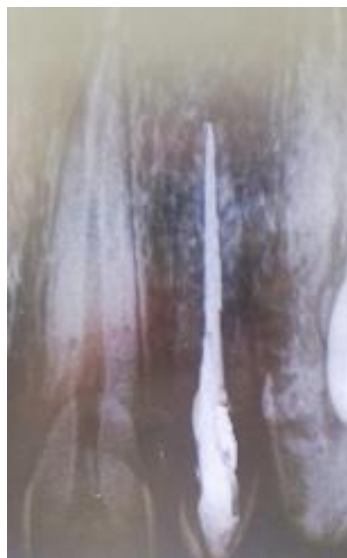#### Treatment Plan

For the right upper lateral incisor, the results of clinical and radiological investigations confirmed the diagnosis of type II of dens invaginatus complicated by an acute periapical lesion so an endodontic treatment was planned. The treatment was challenging because of the deep of the invagination, it seems to be difficult to treat separately the invaginated part, so it was unavoidable to remove it for a better cleaning and a filling of the canal system.

After an isolation with a rubber dam, the access cavity was realised using a fast hand peace round diamond bear. Under magnification using an operating microscope, the invaginated portion was removed using

ultrasonic tips ET 25. So we obtained a unique, a tapered large canal. Next, 2 shape file served alternately with a copious irrigation using a 5.25 % sodium chloride solution to achieve the mechanical and chemical debridement of the root canal. Then this canal was filled with calcium hydroxide paste and the access cavity temporary sealed with cavite.

On the second visit, after the removal of the provisional restoration and calcium hydroxide endodontic dressing, the canal was dried with sterile paper points and obturated with gutta percha and the adseal as a sealer (epoxy resin and calcium phosphate based sealer) (figure 8).



**Figure 8:** Root canal filling by gutta percha points and the adseal on the 12

For the contralateral lateral incisor as it is diagnosed with type I of dens invaginatus, a prophylactic treatment was adopted for fissure sealing

using a fluid resin (reflectys flow itena universal) (figure 9 and 10).

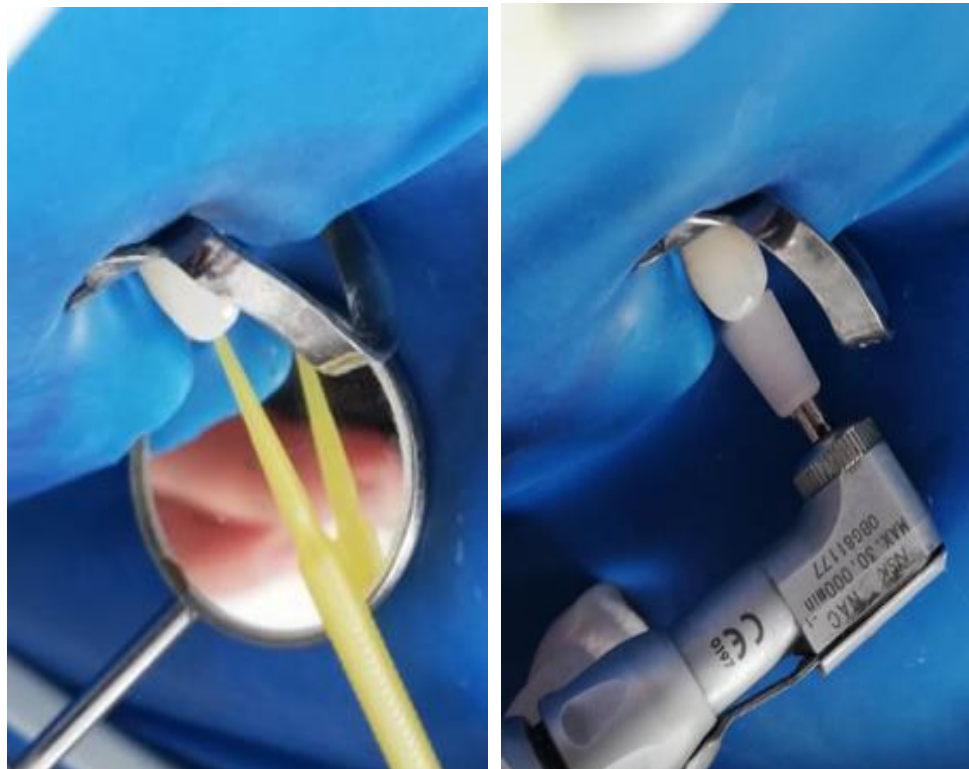


Figure 9 and 10: The prophylactic treatment on the 22 by sealing the palatal pit with fluid resin

For the two canines, although they were diagnosed with type II of dens invaginatus, only a prophylactic treatment was established because they were asymptomatic with no complications. So, the deep pit was sealed with fluid resin.

## DISCUSSION

The Dens invaginatus (DI) is frequently detected in maxillary lateral teeth and it is rarely observed in canines [7].

Generally, this anomaly is underdiagnosed and it constitutes a high risk of pulpal and periapical pathosis [8]. In fact, the invagination and the deep pit on the palatal surface is considered as a privileged zone for plaque formation and promotes a communication with oral cavity which may cause silent necrosis and so pulpal and perapical complications [9].

DI is more commonly discovered by chance in perapical radiographs, so we should be aware of an early diagnosis of DI especially when assessing upper lateral incisors [5]. Indeed, Face to an alteration of the morphology of the crown, we should suspect a tooth invagination and we should deepen our clinical and radiological examination [1].

The CBCT evaluation is necessary to determinate the extension of these structures into the root canal, to identify the type of this invagination and the presence or not of any complication to adapt the appropriate treatment [6].

In our case, the CBCT showed an invagination, which extended the cemento-enamel junction in the root canal of the right lateral upper incisor, which was categorized as Oehelr's Type II. Also, an acute periapical lesion was diagnosed in the current case.

The treatment of type II may present a complex challenge. In fact, the invagination is generally surrounded by pulp tissue, which may complicate the cleaning of the main root canal. Some authors recommend the fact that we maintain the original anatomy of both the main root canal and the invagination in order to minimize dentin elimination. This conservative option may be a valid successful treatment only with ultrasonic tip and especially under magnification [5].

In the current case, we opted for an elimination of the invagination and its infected dentin because it seemed to be difficult to ensure a successful debridement of the root canal [5]. Indeed, the communication of the necrotic root canal system and



the invagination was evident through the cone beam [8]. Some studies recommend that we simplify the root canal treatment with an elimination of the invagination in order to have a better cleaning and filling of the root canal system [7].

However, some authors proved that when there is not a communication between the main root canal and the invaginated canal, which does not impede full access to the apical portion, both canals might be treated separately thoroughly disinfected and obturated [9].

So, it well documented that to promote the healing of periapical tissues in cases of type II dens invaginatus, a complete disinfecting of the root canal system is mandatory with 5.25% sodium hypochlorite as irrigation and calcium hydroxide as intracanal medication [10].

An early diagnosis of dens invagination ensures a prophylactic treatment to prevent pulpal and perapical complications [11].

Restorative procedures using adhesive materials such as resin composite and glass ionomer can be proceeded to seal the palatal pit .also ,when the fissure is deep we can use calcium hydroxide to stimulate formation of secondary dentin and caries inhibition [7].

In our case, we opted to a preventive treatment of the deep fissure in the palatal surface of the 22 presenting type I of dens invaginatus by using resin fluid on the two upper canines. The CBCT shows that they present type II of dens invaginatus but they were asymptomatic with no periapical complication so only a preventive sealing was used. But, a periodic evaluation and regular follow up are necessary after a prophylactic treatment of type II invagination to detect any pulpal necrosis [3].

## CONCLUSION

Dens invaginatus is a rare developmental malformation, which includes a bacterial contamination, and their discovery is usually associated with necrotic pulp and periapical complications. Their anatomy makes endodontic management challenging .Various treatment procedures has been reported in the literature including or not invaginated tissue removal, apexification, pulp revascularisation. It depends on the type and the path of the invagination structure and the pulp diagnosis.

## REFERENCES

1. Lejri, W., Kallel, I., Marwen, O., & Douki, N. (2016). Diagnostic and therapeutic approach in dens in dente. *Endodontology*, 28(2), 192-198.

2. Hasna, A. A., de Toledo Ungaro, D. M., de Melo, A. A. P., Yui, K. C. K., da Silva, E. G., Martinho, F. C., & Gomes, A. P. M. (2019). Nonsurgical endodontic management of dens invaginatus: a report of two cases. *F1000Research*, 8, 2039.
3. Bolhari, B., Noori, F., & Assadian, H. (2021). Endodontic Management of a Maxillary Lateral Incisor with Dens Invagination and Periapical Lesion: A Case Report and Mini Review of the Literature. *Frontiers in Dentistry*, 18, 42. doi: 10.18502/fid.v18i42.8014. PMID: 35965704; PMCID: PMC9355846
4. Alani, A., & Bishop, K. (2008). Dens invaginatus. Part 1: classification, prevalence and aetiology. *International endodontic journal*, 41(12), 1123-1136.
5. Dembinskaite, A., Veberiene, R., & Machiulskiene, V. (2018). Successful treatment of dens invaginatus type 3 with infected invagination, vital pulp, and cystic lesion: A case report. *Clinical case reports*, 6(8), 1565.
6. Bougatef, H., Ouni, M., Kallel, I., Moussaoui, E., Elleuch, O., & Douki, N. (2021). Management of a Type II Dens Invaginatus with Regenerative Endodontic Therapy. *J Pediatr*, 7(2), 83-92.
7. Hegde, V., Morawala, A., Gupta, A., & Khandwawala, N. (2016). Dens in dente: A minimally invasive nonsurgical approach!. *Journal of Conservative Dentistry: JCD*, 19(5), 487-9.
8. Mabrouk, N. A. (2018). Successful management of a type II Dens invaginatus with an open apex and a large periapical lesion. A case report of a permanent maxillary canine. *Dent Oral Craniofac Res*, 4. DOI: 10.15761/DOCR.1000276
9. Zhang, P., & Wei, X. (2017). Combined Therapy for a Rare Case of Type III Dens Invaginatus in a Mandibular Central Incisor with a Periapical Lesion: A Case Report. *J Endod.*, 43(8), 1378-138.
10. Azzahim, L., Bassim, N., & Abdallaoui, F. (2022). CBCT Evaluation and Conservative Management of a Large Periapical Lesion Associated with Dens Invaginatus Type II. *Case Reports in Dentistry*, 2022, 1529835.
11. Bolhari, B., Noori, F., & Assadian, H. (2021). Endodontic Management of a Maxillary Lateral Incisor with Dens Invagination and Periapical Lesion: A Case Report and Mini Review of the Literature. *Frontiers in Dentistry*, 18, 42. doi: 10.18502/fid.v18i42.8014. PMID: 35965704; PMCID: PMC9355846
12. Lejri, W., Kallel, I., Marwen, O., & Douki, N. (2016). Diagnostic and therapeutic approach in dens in dente. *Endodontology*, 28(2), 192.
13. Lejri, W., Kallel, I., Marwen, O., & Douki, N. (2016). Diagnostic and therapeutic approach in dens in dente. *Endodontology*, 28(2), 192.
14. Lejri, W., Kallel, I., Marwen, O., & Douki, N. (2016). Diagnostic and therapeutic approach in dens in dente. *Endodontology*, 28(2), 192.

15. Lejri, W., Kallel, I., Marwen, O., & Douki, N. (2016). Diagnostic and therapeutic approach in dens in dente. *Endodontology*, 28(2), 192.
16. Lejri, W., Kallel, I., Marwen, O., & Douki, N. (2016). Diagnostic and therapeutic approach in dens in dente. *Endodontology*, 28(2), 192.
17. Lejri, W., Kallel, I., Marwen, O., & Douki, N. (2016). Diagnostic and therapeutic approach in dens in dente. *Endodontology*, 28(2), 192.
18. Lejri, W., Kallel, I., Marwen, O., & Douki, N. (2016). Diagnostic and therapeutic approach in dens in dente. *Endodontology*, 28(2), 192.

---

**Cite This Article:** Elleuch Oumaima, Kallel Ines, Douki Nabiha (2023). Management of a Type I and Type II of Dens Invaginatus on Maxillary Teeth: A Case Report. *EAS J Dent Oral Med*, 5(1), 7-12.

---