

## Case Report

## Endocrown Restorations: A Conservative Approach to Restore Extensively Damaged Endodontically Treated Teeth

Naima Ayari<sup>1\*</sup>, Ibtissem Grira<sup>2</sup>, Nabiha Douki<sup>3</sup>

<sup>1</sup>Resident, Department of Dental Medicine, Sahloul Hospital, Dental Faculty of Monastir, Laboratory of Research in Oral Health and Maxillo Facial Rehabilitation (LR12ES11), University of Monastir, Tunisia

<sup>2</sup>Assistante Professor, Department of Dental Medicine, Sahloul Hospital, Dental Faculty of Monastir, Laboratory of Research in Oral Health and Maxillo Facial Rehabilitation (LR12ES11), University of Monastir, Tunisia

<sup>3</sup>Professor, Head of the Department of Dental Medicine, Sahloul Hospital, Dental Faculty of Monastir, Laboratory of Research in Oral Health and Maxillo Facial Rehabilitation (LR12ES11), University of Monastir, Tunisia

### Article History

Received: 04.03.2023

Accepted: 11.04.2023

Published: 16.04.2023

### Journal homepage:

<https://www.easpublisher.com>

### Quick Response Code



**Abstract:** Rehabilitation of endodontically treated molar still remains a controversial issue. Over the years, the use of post-retained restorations has been questioned because of potential tooth weakening. Nowadays, endocrowns are considered as a reliable alternative technique to restore endodontically treated teeth with extensive coronal damage. This partial restoration requires specific preparation design and rigorous adhesion protocol. The present paper aimed to describe the preparation technique for endocrowns, indications, contraindications, and best material adapted for fabrication. This was illustrated through a clinical case to restore the first right mandibular molar by an endocrown fabricated from lithium disilicate-ceramic (IPS e-max CAD).

**Keywords:** Endocrown, Monolithic restoration, endodontically treated teeth, cementation, ceramic, molar.

**Copyright © 2023 The Author(s):** This is an open-access article distributed under the terms of the Creative Commons Attribution **4.0 International License (CC BY-NC 4.0)** which permits unrestricted use, distribution, and reproduction in any medium for non-commercial use provided the original author and source are credited.

## INTRODUCTION

Restoring endodontically treated teeth with extensive coronal destruction is still a clinical challenge for dentists, especially due to the loss of strength characteristics associated to the removal of pulp and surrounding dentin tissue [1].

A long time ago, rehabilitation of extremely damaged teeth was achieved with a crown supported by a cast metal core because coronal retention of the restoration is usually compromised [1].

Despite all clinical success achieved with the use of intraradicular posts, some disadvantages of this system are the additional removal of sound tissue needed for fitting the post into the root canal and clinical limitations (calcified root canals, narrow canals, or a fractured instrument).

Alternatively, a more conservative approach was proposed in 1999 by Bindl and Mörmann as a substitute to the full post-and-core-supported crown: endocrown, a one-piece ceramic construction [2].

Endocrowns represent monoblock restorations [3], making the intraradicular post, the core, and the crown a one component [4, 5]. Different from conventional prosthetic restorations using intraradicular posts, endocrowns are anchored to the internal portion of the pulp chamber and on the cavity margins, thereby resulting in both macro- and micro-mechanical retention, provided by the pulpal walls and adhesive cementation, respectively [6, 7].

This paper aimed to describe through a clinical case, the technique of preparation, the indications, and the use of endocrowns in order to restore endodontically treated teeth.

## CASE REPORT

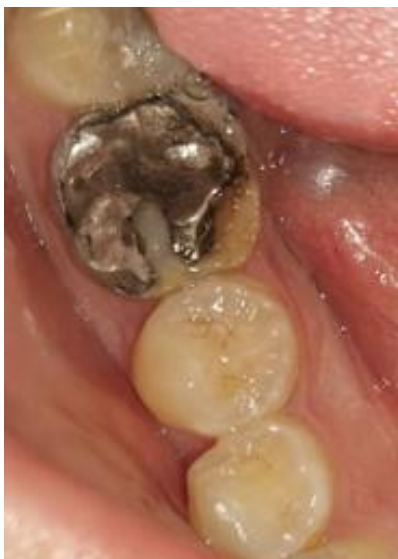A 24-year-old girl was referred to the dental medicine department at Sahloul Hospital, Sousse, to replace a defective amalgam restoration located in the first right mandibular molar. Clinical and radiographic examinations were performed initially (Figure 1 and 2). The patient had an acceptable oral hygiene and a favorable occlusion. The tooth was symptomatic, the vitality and the percussion tests were positive, and the

\*Corresponding Author: Naima Ayari

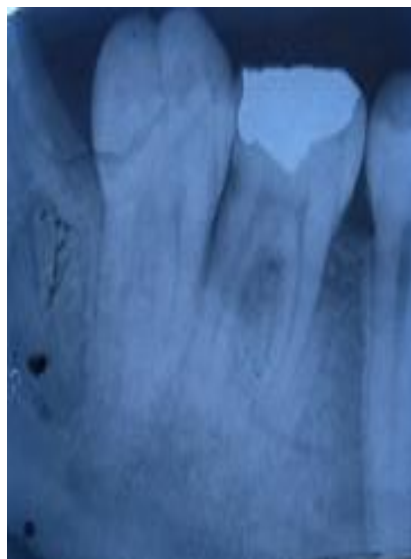
Resident, Department of Dental Medicine, Sahloul Hospital, Dental Faculty of Monastir, Laboratory of Research in Oral Health and Maxillo Facial Rehabilitation (LR12ES11), University of Monastir, Tunisia

palpation test was negative. X-ray examination revealed a proximal secondary caries. No apical translucency

was observed.



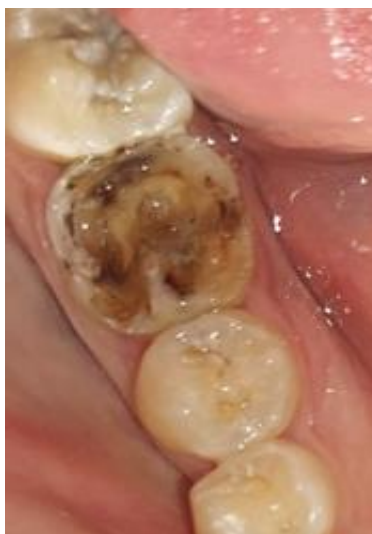**Figure 1: Initial situation of the right mandibular molar**



**Figure 2: Pre-operative radiograph before the endodontic treatment**

In this case, it was decided to remove the amalgam coronal restoration and to perform an endodontic treatment due to the deep carious lesion

(Figure 3). Then, all currently tooth restoration options were discussed: a direct restoration, an indirect partial restoration, a crown or a post retained restoration.



**Figure 3: Occlusal view after removal of the amalgam restoration**

After performing the pre-prosthetic treatment, the remaining tooth structure was in a supragingival situation, and the thickness of the walls was over 2 mm with an enamel margin. Regarding this clinical situation, a lithium-disilicate glass-ceramic endocrown was indicated.

The preparation consisted in reducing the occlusal surface height at least 2 mm in the axial direction. The wheel bur was oriented along the major axis of the tooth to get a cervical margin in the form of a butt joint. Then, differences in level between the various parts of the cervical margin must be linked by a

slope of no more than 60° to avoid a staircase effect. Enamel walls less than 2 mm thick should be removed [8].

The axial preparation involves eliminating undercuts in the access cavity. A cylindrical-conical green diamond bur with a total occlusal convergence of 7° is used to make the coronal pulp chamber and endodontic access cavity continuous. The depth of the cavity should be at least 3 mm [8].

The cavity floor preparation consisted in removing the Gutta-percha to a depth not exceeding 2

mm to take advantage of the saddle-like anatomy of the cavity floor. A nonabrasive instrument was used to

maintain the integrity of the canals' entrance (Figure 4).

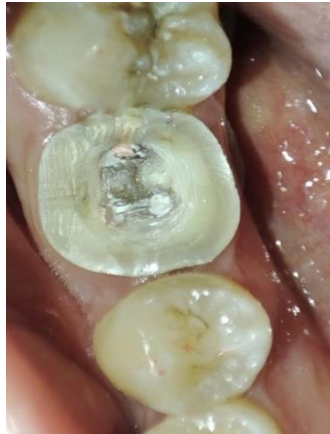

Figure 4: Occlusal view after the preparation

Finally, the cervical band was polished. The bur used in this step is a larger diameter and a finer particle size than used in axial preparation. It should be guided around the entire surface of the cervical band to remove micro-irregularities and produce a flat, polished surface. The margin line should appear as a regular line with a sharp edge [8].

Polyvinyl siloxane silicone (Protesil, VANNINI, Italie) of light and heavy consistency was used with a simultaneous molding technique to take the impression, together with dual retractor cord 00 and 0 (Figure 5). The impression of the antagonist arch was taken with alginate. The upper and lower impressions were sent to the prosthesis laboratory.



Figure 5: Mandibular impression with polyvinyl siloxane silicone

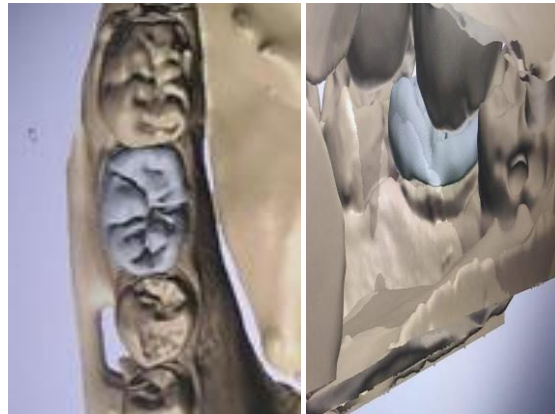


Figure 6: Computer aided design of the partial restoration

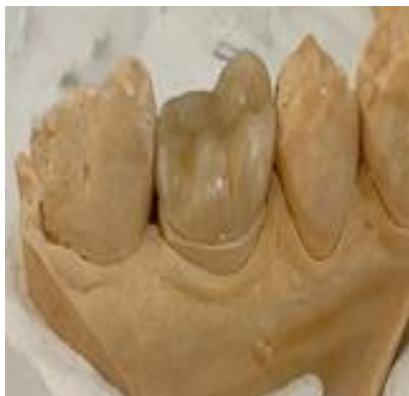

Figure 7: Vestibular view of the Endocrown in the master cast

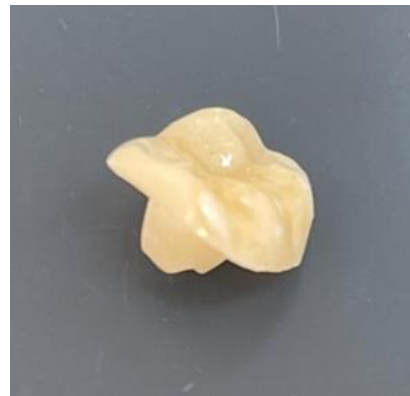
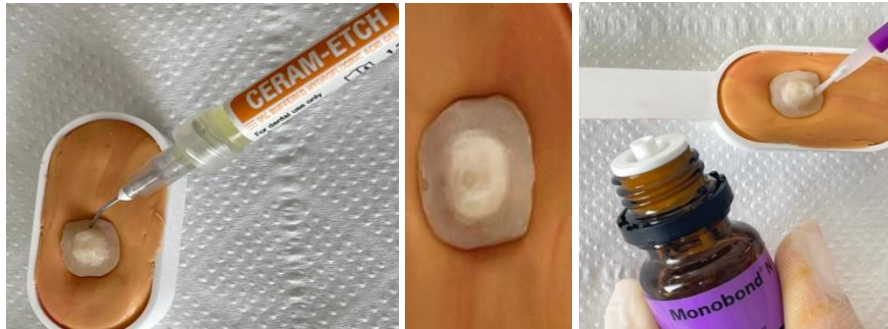
Figure 8: Endocrown fabricated from lithium disilicate-based ceramic (IPS e max CAD)

The temporary restoration was performed with self-polymerizing acrylic resin (DentoCrown, ITENA, France), in shade A1, with adequately adapted gingival margins to ensure healthy gingival tissue.

In the cementation appointment, the provisional restoration was removed, and the cavity was

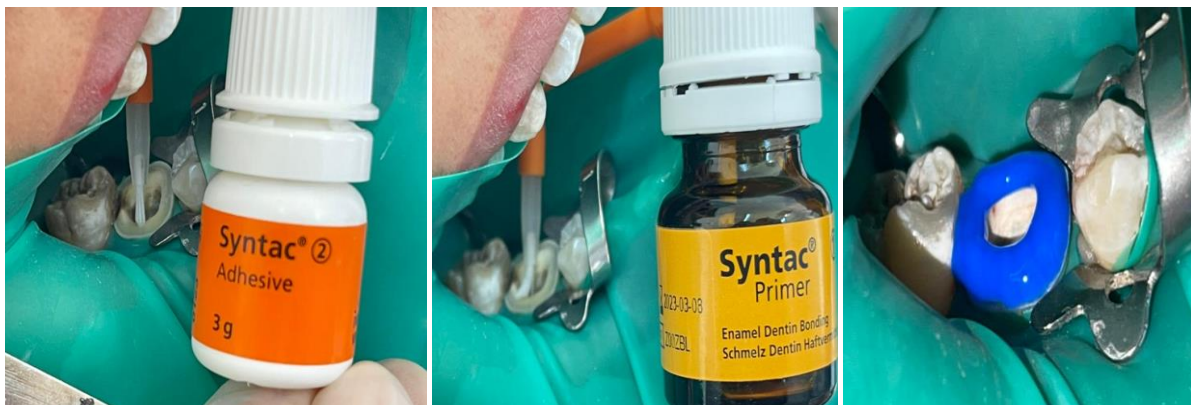cleaned. The endocrown was tried in. The operative field was isolated. The internal surface of the prosthetic piece was treated with 9% hydrofluoric acid for 40s, washed with abundant water and dried, a coat of a silane coupling agent was applied for 1 minute and dried (Figure 9).



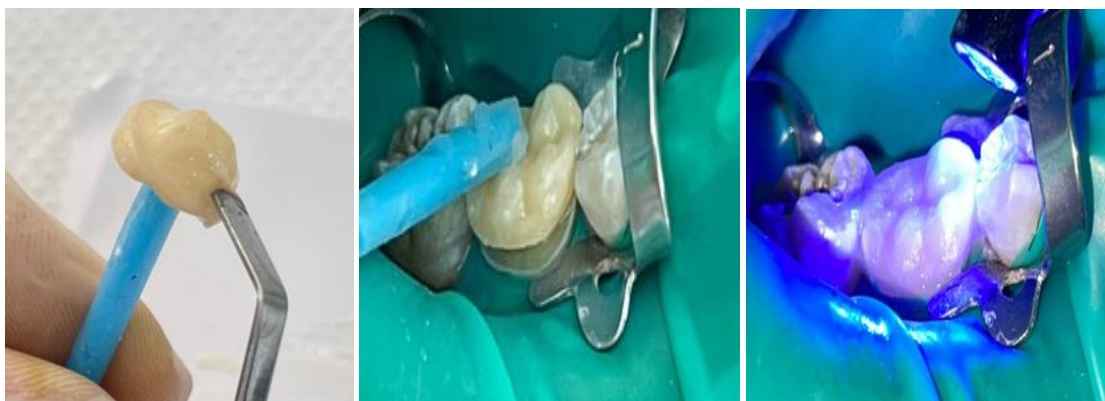**Figure 9: Conditioning of the ceramic endocrown: Etching using hydro fluoride acid and silane application on the prosthetic inner side**

The tooth was etched with 37% orthophosphoric acid for 30s for the enamel tissue and 15s for the dentin tissue. The tooth was washed with abundant water for 20s and then dried. A thin coat of adhesive was applied and light- activated for 20s (Figure 10). A dual polymerizing resin (Variolink N, Ivoclar Vivadent) was applied to the prosthetic piece,

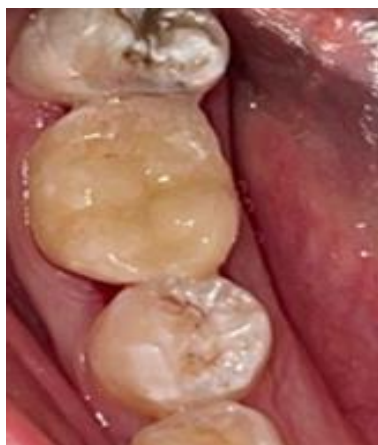inserted in position on the preparation, and polymerized at intervals of 5 seconds so that it is easy to remove cement excesses (Figure 11). The light activation was performed for 60s for each face. Some occlusal adjustments were necessary after cementation. The final result is shown in figure 12 and 13.



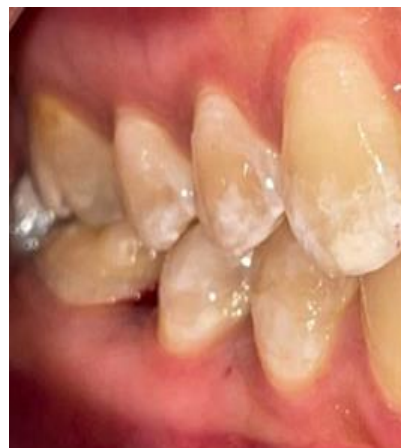**Figure 10: Conditioning of the prepared teeth: Selective enamel etching using phosphoric acid e and application of the bonding agent**



**Figure 11: Application of the resin cement on the inner side of the prosthetic piece, positioning of the endocrown and photopolymerization**



**Figure 12: Occlusal view after the cementation of the endocrown**



**Figure 13: Final view arches in occlusion**

## DISCUSSION

Endocrowns are considered as an alternative approach to restore endodontically treated posterior teeth [8]. They are considered less complicated, more practical, and easier to perform than conventional crowns with cores or posts. Bernhart *et al.*, [9] concluded that endocrowns “represent a very promising treatment alternative for endodontically treated molars.”

Studies have shown that endocrowns should be restricted to the functional and esthetic recovery of posterior teeth, especially molars, since their performance in premolars against the action of masticatory forces has not been the same as that achieved in molars [8]. The smaller dental structure area of the pulp chamber and, consequently, of the adhesive surface of premolars, limits the bond strength of adhesive systems and resin cements [10]. Biacchi and Basting [11] concluded that endocrowns were more resistant to compressive forces than conventional crowns.

The endocrown is suitable for all molars, particularly those with clinically low crowns, calcified root canals, or roots with fractured instruments. The endocrown is contraindicated if adhesion cannot be assured, if the pulpal chamber is less than 3 mm deep or if the cervical margin is less than 2 mm wide for most of its circumference [8].

Bindl and Mörmann [2] initially proposed the preparation of the circular cervical butt margin of a width of 1.0 to 1.2 mm. More recently, the cervical sidewalk of the restorative piece, which is the base of the restoration with a band of peripheral enamel that optimizes bonding is left without axial preparation. The goal is to achieve a wide, even, stable surface that resists the compressive stresses that are most common on molars [9].

Thus, these stresses are reduced, being distributed over the cervical butt joint and the walls of the pulp chamber [12-15].

The prepared surface, parallel to the occlusal plane, ensures stress resistance. The pulpal chamber cavity design ensures stability and retention [8].

Sometimes a coat of resin composite is used to fill irregularities in the pulp chamber to remove the retentive area [8].

The internal portion of the endocrown, projected toward the inside of the pulp chamber, is responsible for the mechanical micro retention [8]. By dispensing with the use of an intraradicular post and maintaining the seal provided by the endodontic filling material, an endocrown allows minimal tooth wear, and thus strengthening the tooth, since it helps preserve sound dental tissue and root canal structures [16-18]. Thus, they are not fragilized by the drilling, and they will not receive the stresses associated with the use of post [19].

Also, the development of the adhesive cementation systems facilitates the bonding procedure of these type of prosthetic pieces. The bonding agent presents an important modulus of elasticity as it must be able to absorb pressure, just as the dentin enamel junction (DEJ) does [20].

On another hand, the use of ceramic has the advantages of biocompatibility, and biomimicry, and its wear coefficient is close to that of the natural tooth. The single interface of a 1-piece restoration makes cohesion look better [21, 22]. It must be an acid etchable ceramic to obtain the bond to tooth preparation through an adhesive cementation system, and, consequently, ensure the stability of the piece in the preparation [23]. The lithium disilicate ceramic used to make the restorations has high mechanical strength and provides restorations with an esthetic appearance very similar to that of tooth enamel [24].

The limitation of this technique is patrician-dependent. The bonding procedure should be performed in a strict manner in order to avoid failure (sensitivity, decohesion...).

## CONCLUSION

Endocrowns represent an alternative approach for restoring extensively damaged endodontically treated molars. The procedure is simple, easy, and less time consuming. This type of all-ceramic monolithic-type restorations preserves the remaining tooth structure and respect the minimally invasive dentistry concept. Fabricated from lithium-disilicate glass-ceramic, endocrowns yielded highly successful results in esthetic aspects and ensured mechanical strength. Endocrown fits perfectly with the concept of biointegration and belongs among the restorative options for posterior teeth.

## REFERENCES

1. Sedrez-Porto, J. A., da Rosa, W. L. D. O., da Silva, A. F., Münchow, E. A., & Pereira-Cenci, T. (2016). Endocrown restorations: A systematic review and meta-analysis. *Journal of dentistry*, 52, 8-14.
2. Biacchi, G. R., & Basting, R. T. (2012). Comparison of fracture strength of endocrowns and glass fiber post-retained conventional crowns. *Operative dentistry*, 37(2), 130-136.
3. Tay, F. R., & Pashley, D. H. (2007). Monoblocks in root canals: a hypothetical or a tangible goal. *Journal of endodontics*, 33(4), 391-398.
4. Otto, T. (2004). Computer-aided direct all-ceramic crowns: preliminary 1-year results of a prospective clinical study. *International Journal of Periodontics & Restorative Dentistry*, 24(5).
5. Zarone, F., Sorrentino, R., Apicella, D., Valentino, B., Ferrari, M., Aversa, R., & Apicella, A. (2006). Evaluation of the biomechanical behavior of maxillary central incisors restored by means of endocrowns compared to a natural tooth: a 3D static linear finite elements analysis. *Dental materials*, 22(11), 1035-1044.
6. Biacchi, G. R., Mello, B., & Basting, R. T. (2013). The endocrown: an alternative approach for restoring extensively damaged molars. *Journal of Esthetic and Restorative Dentistry*, 25(6), 383-390.
7. El-Damanhoury, H. M., Haj-Ali, R. N., & Platt, J. A. (2015). Fracture resistance and microleakage of endocrowns utilizing three CAD-CAM blocks. *Operative dentistry*, 40(2), 201-210.
8. Fages, M., & Bennasar, B. (2013). The endocrown: a different type of all-ceramic reconstruction for molars. *J Can Dent Assoc*, 79, d140.
9. Bernharta, J., Bräuningb, A., Altenburgerc, M., & Wrbasd, K. (2010). Cerec® 3D Endocrowns—Two-year Clinical Examination of CAD/CAM Crowns for Restoring Endodontically Treated Molars Cerec® 3D-Endokronen—Untersuchung der klinischen Bewährung von CAD/CAM-Kronen. *International journal of computerized dentistry*, 13, 141-154.
10. Bindl, A., Richter, B., & Mörmann, W. H. (2005). Survival of ceramic computer-aided design/manufacturing crowns bonded to preparations with reduced macroretention geometry. *International Journal of Prosthodontics*, 18(3).
11. Biacchi, G. R., & Basting, R. T. (2012). Comparison of fracture strength of endocrowns and glass fiber post-retained conventional crowns. *Operative dentistry*, 37(2), 130-136.
12. Menezes-Silva, R., Espinoza, C. A. V., Atta, M. T., de Lima Navarro, M. F., Ishikiriyama, S. K., & Mondelli, R. F. L. (2016). Endocrown: a conservative approach. *Brazilian Dental Science*, 19(2), 121-131.
13. Fages, M., & Bennasar, B. (2013). The endocrown: a different type of all-ceramic reconstruction for molars. *J Can Dent Assoc*, 79, d140.
14. Rocca, G. T., Daher, R., Saratti, C. M., Sedlacek, R., Suchy, T., Feilzer, A. J., & Krejci, I. (2018). Restoration of severely damaged endodontically treated premolars: The influence of the endo-core length on marginal integrity and fatigue resistance of lithium disilicate CAD-CAM ceramic endocrowns. *Journal of dentistry*, 68, 41-50.
15. da Cunha, L. F., Mondelli, J., Auersvald, C. M., Gonzaga, C. C., Mondelli, R. F. L., Correr, G. M., & Furuse, A. Y. (2015). Endocrown with leucite-reinforced ceramic: case of restoration of endodontically treated teeth. *Case reports in dentistry*, 2015.
16. Asmussen, E., Peutzfeldt, A., & Sahafi, A. (2005). Finite element analysis of stresses in endodontically treated, dowel-restored teeth. *The Journal of prosthetic dentistry*, 94(4), 321-329.
17. Dietschi, D., Duc, O., Krejci, I., & Sadan, A. (2008). Biomechanical considerations for the restoration of endodontically treated teeth: a systematic review of the literature, Part II (Evaluation of fatigue behavior, interfaces, and in vivo studies). *Quintessence international*, 39(2).
18. Zarow, M., Devoto, W., & Saracinelli, M. (2009). Reconstruction of endodontically treated posterior teeth—with or without post? Guidelines for the dental practitioner. *European Journal of Esthetic Dentistry*, 4(4).
19. Fernandes, A. S., & Dessai, G. S. (2001). Factors affecting the fracture resistance of post-core reconstructed teeth: a review. *International Journal of Prosthodontics*, 14(4).
20. Bindl, A., Richter, B., & Mörmann, W. H. (2005). Survival of ceramic computer-aided design/manufacturing crowns bonded to preparations with reduced macroretention geometry. *International Journal of Prosthodontics*, 18(3).

21. Lin, C. L., Chang, Y. H., Chang, C. Y., Pai, C. A., & Huang, S. F. (2010). Finite element and Weibull analyses to estimate failure risks in the ceramic endocrown and classical crown for endodontically treated maxillary premolar. *European journal of oral sciences*, 118(1), 87-93.
22. Zarone, F., Sorrentino, R., Apicella, D., Valentino, B., Ferrari, M., Aversa, R., & Apicella, A. (2006). Evaluation of the biomechanical behavior of maxillary central incisors restored by means of endocrowns compared to a natural tooth: a 3D static linear finite elements analysis. *Dental materials*, 22(11), 1035-1044.
23. Tysowsky, G. W. (2009). The science behind lithium disilicate: a metal-free alternative. *Dentistry today*, 28(3), 112-113.
24. Pissis, P. (1995). Fabrication of a metal-free ceramic restoration utilizing the monobloc technique. *Practical periodontics and aesthetic dentistry: PPAD*, 7(5), 83-94.

---

**Cite This Article:** Naima Ayari, Ibtissem Grira, Nabiha Douki (2023). Endocrown Restorations: A Conservative Approach to Restore Extensively Damaged Endodontically Treated Teeth. *EAS J Dent Oral Med*, 5(2), 53-59.

---