

Case Report

Hairpin Ingestion, an Unusual Cause of Epigastralgia

Dr. Meriem Boui^{1*}, Zakaria Zouaki¹, Nabil Hammoune¹, Badr Slioui¹, Rachid Akka², Mehdi Atmane¹, Abdelilah Mouhsine¹

¹Department of Radiology, Avicenne Military Hospital, Marrakech, Morocco

²Department of Gastroenterology, Avicenne Military Hospital, Marrakech, Morocco

Article History

Received: 09.03.2023

Accepted: 25.04.2023

Published: 30.04.2023

Journal homepage:

<https://www.easpublisher.com>

Quick Response Code

Abstract: The ingestion of foreign bodies is relatively frequent. It can be voluntary, but it is most often accidental. Ingested objects can be dangerous due to their sharp nature and their location in the digestive tract. The scarf pin is a particular foreign body that is increasingly common among women who wear the veil. Imaging plays a key role in the diagnosis, particularly chest x-rays or an abdomen without preparation, which can locate the area of projection of radiopaque objects. More rarely, CT is used in the event of complications. We report two cases of two patients wearing the veil who accidentally ingested pins that they were holding between their lips while arranging the veil. In the first case, endoscopic extraction of the pin was successfully performed, and in the second case, the pin migrated along the digestive tract with close radiological monitoring until it was expelled in the stool. Considering the complications of needle ingestion, it is advisable to avoid holding needles between the lips when securing the veil with pins.

Key words: Foreign body, Hairpin, Endoscopic extraction, Prevention.

Copyright © 2023 The Author(s): This is an open-access article distributed under the terms of the Creative Commons Attribution **4.0 International License (CC BY-NC 4.0)** which permits unrestricted use, distribution, and reproduction in any medium for non-commercial use provided the original author and source are credited.

INTRODUCTION

Foreign body (FB) ingestion is quite frequent phenomenon in paediatric population but less common in teenagers and adults. It especially occurs in case of psychiatric disorders or suicidal behaviour. The scarf pin is a particular FB that is increasingly common among women who wear the veil. Two types of scarves pins are the most frequently found, one is a classic metal safety pin and the second is similar to a metal needle about 3cm long which has two ends, one pointed and the other features a plastic ball. Women who hold the pins between their lips or teeth when putting on their scarf [1, 2] primarily report accidental ingestion of scarf pins. Given the morphology of these pins, their ingestion is dangerous and may be complicated by perforation, aspiration and bleeding; [3, 4]. However, their early diagnosis and prompt management can reduce the risk of complications. We report two cases of ingestion of a scarf pin; one in a teenager with a classic

safety pin and the second case in an elderly woman with unrecognized ingestion of a sharp pin by the patient.

Case 1

Fortuitous discovery of a metallic object in front of trailing epigastralgia with normal biology in a 57-year-old woman, wearing the veil, with a history of cholecystectomy 10 years ago without any other notable medical history, who consults for intense and intermittent epigastralgia evolving for two months. The clinical examination was unremarkable and the blood test was normal. Faced with the lingering symptoms, the patient underwent abdominal CT that objectified an object of metallic density, measuring 3.2cm pointed at the level of the wall of the gastric antrum opposite the head of the pancreas (Fig 1). The patient then underwent fibroscopy, which revealed a scarf pin whose pointed edge was intra- parietal and had not migrated extra-digestively thanks to its plastic tip (Fig 2). Endoscopic extraction was successfully performed (Fig 3).

*Corresponding Author: Dr. Boui Meriem

Department of Radiology, Avicenne Military Hospital, Marrakech, Morocco

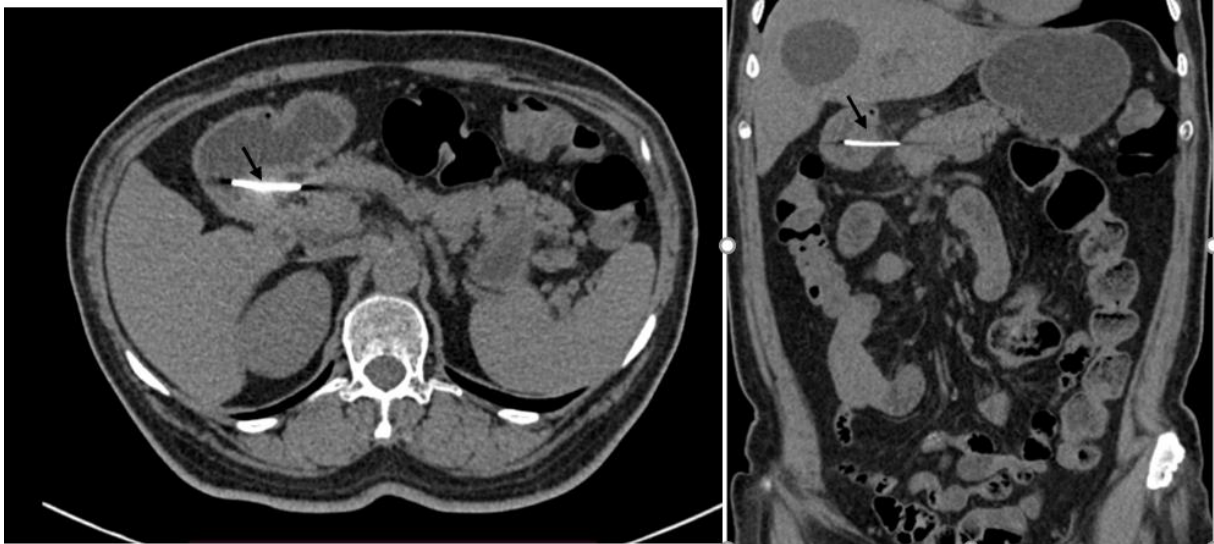


Figure 1: Computed tomography abdomen shows the hairpin (black arrow) in gastric wall with intimate contact of the pancreas head

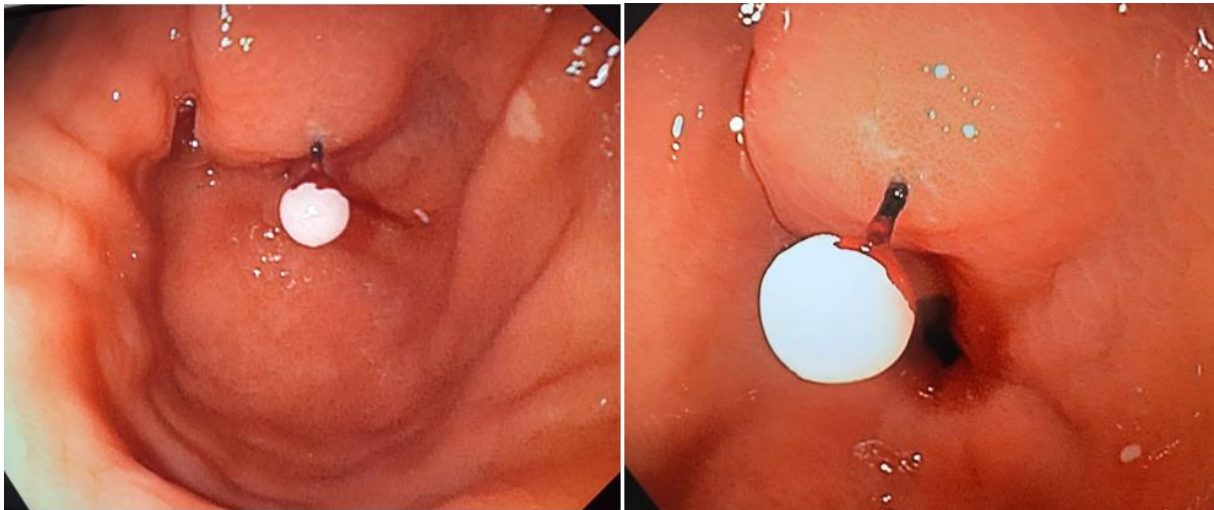


Figure 2: Endoscopic pictures showing the hairpin in the gastric mucosa

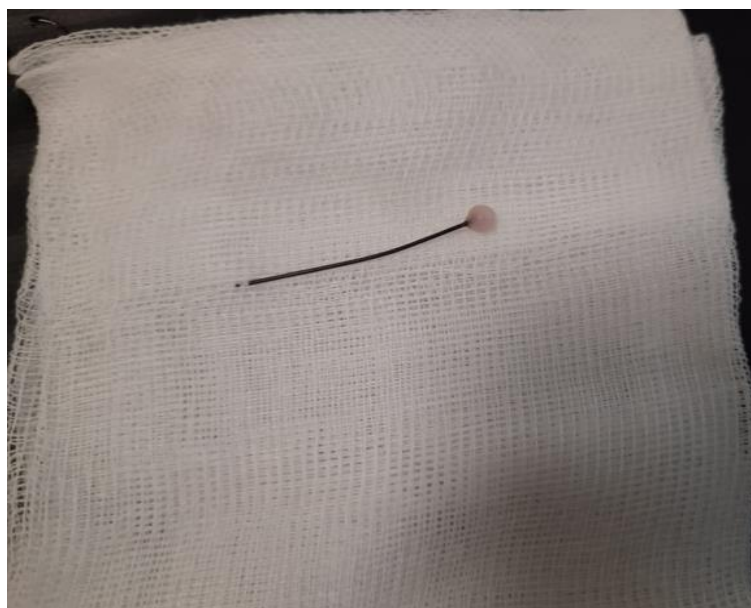

Figure 3: Extracted hairpin

Case 2

A 16-year-old patient wearing the veil, with no history, who consults for accidental ingestion of a safety pin from a scarf, with discomfort when swallowing and chest pain. The chest X-ray and the unprepared abdomen found a pin ,first in the esophageal

level (Fig 4) and then at the digestive level, before migrating along the digestive tract (Fig 5) under close clinic and radiological monitoring until its expulsion in the stools. The control thoracic and abdominal X-ray showed the absence of the radiopaque pin.

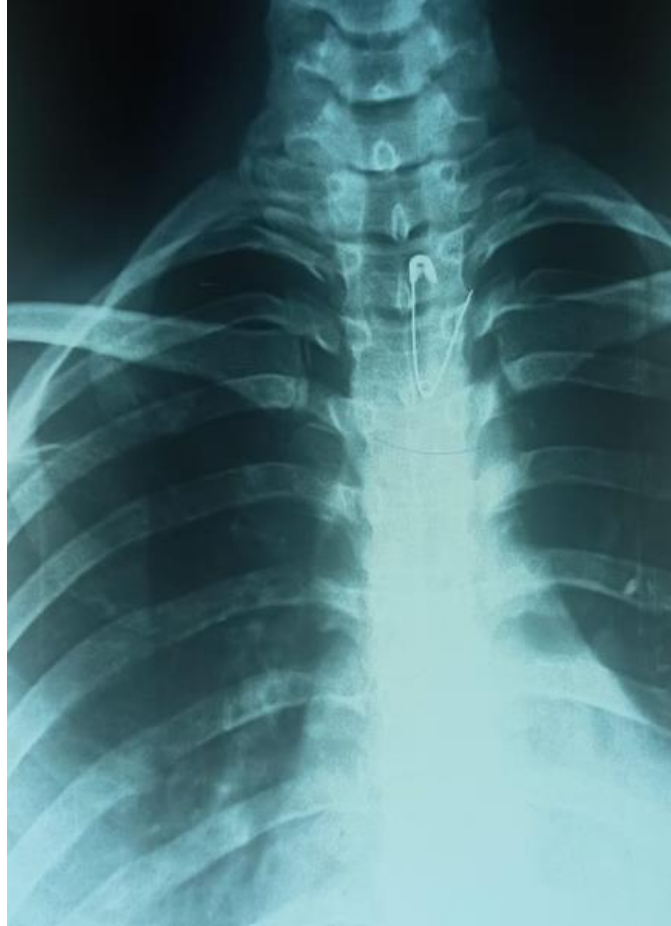

Figure 4: Antero-posterior chest X rays showing the hair pin in the oesophagus (white arrow)

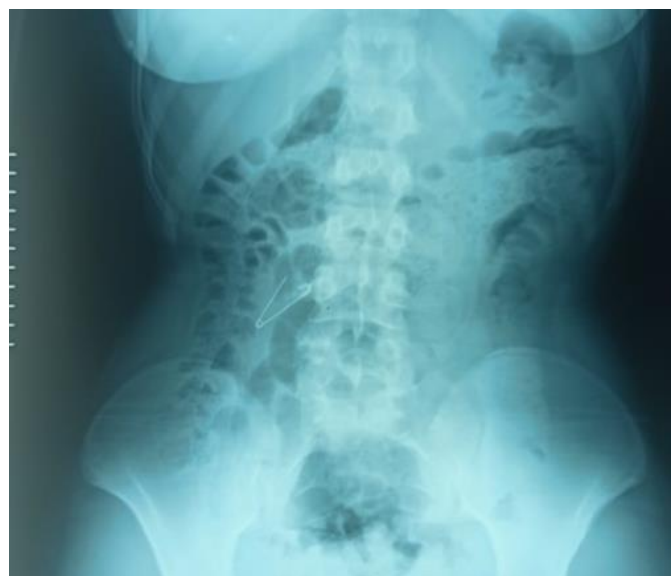

Figure 5: Abdominal plain film the pin projected to the right digestive area (white arrow)

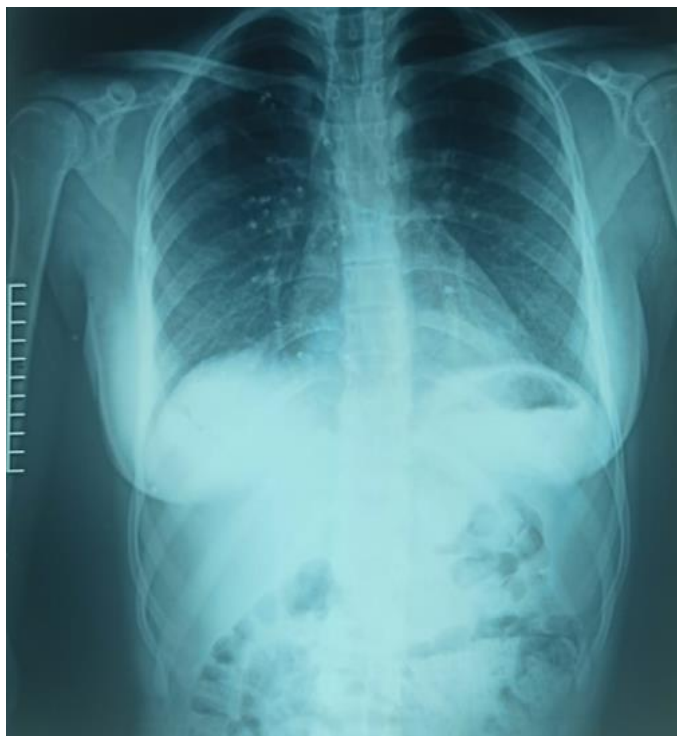

Figure 6: Thoraco-abdominal plain showing no hairpin

DISCUSSION

The ingestion of foreign bodies can be voluntary, but in 52 to 97% it is accidental [5]. In 80% of cases, it concerns children with a peak frequency between six months and three years [6, 7]. Prisoners, psychotic or alcoholic patients are patients at risk as well as those with a history of malformations. The same is true for elderly and toothless subjects [8, 9]. The special case of scarf pin is a rarer accident that occurs in teenage girls and older women, who sometimes hold these pins between their teeth or lips while putting on their scarf. This incident usually occurs in Muslim countries.

A study by N. Elleuch *et al.*, reports 29 observations of young women wearing the veil who accidentally ingested the scarf pins they held between their lips during the arrangement of the veil [10]. Only one have had a CT, endoscopic extraction was performed in 26 women and 3 have had radiological monitoring until expulsion in the stool.

In another study by Mir *et al.*, [11] of 75 young adolescent females of 11-20 years of age wearing the veil who accidentally ingested a scarf pin, recovery by upper gastrointestinal endoscopy was successful in 48% of these patients, while the other patients were managed conservatively; with 2.6% of patients developed peritonitis and one patient died. In other cases in the literature, pin ingestion has caused perforations [3] or a duodeno-cecal fistula [12]. Diagnosis of radiopaque foreign bodies is in principle easy on standard X-rays, but may be difficult to interpret for small objects in adults. It is necessary to

perform AP and lateral incidence radiographs of the cervical, thoracic and abdominal regions. In addition to their diagnostic value, X-rays can detect complications and ensure monitoring [13]. In case of doubt or of a radiolucent foreign body, performing radiological opacification with a water-soluble product is controversial, even contraindicated, because it can delay and hinder the performance of an upper endoscopy, which constitutes a diagnostic and therapeutic means [14]. It is noted that generally the scanner has no place in the investigations of these ingestions except for the search for complications. In addition, in most cases standard chest or abdominal X-rays are sufficient to locate these foreign bodies. The American Society for Gastrointestinal Endoscopy guidelines for the management of ingested foreign bodies and the 2015 North American Society for Pediatric Gastroenterology, Hepatology and Nutrition guidelines recommend endoscopic removal of sharp objects that have passed through the stomach or the proximal duodenum. They recommend doing successive simple abdominal X-rays and conservative management of these objects that have passed into the small intestine. However, surgery should be the option if there is no gradual passage within 3 days or if alarming symptoms (intense abdominal pain, gastrointestinal bleeding, nausea, vomiting, etc.) develop [15, 16]. In our case, the pin was within the gastric wall and therefore required endoscopic removal. On the other hand, the second patient evacuated the pin under radiological monitoring and without complication.

CONCLUSION

Ingestion of scarf pins is considered as a dangerous emergency among women who use these pins to secure the scarf. In addition, these incidents are becoming more common and affecting different age groups, hence the need for greater public awareness of the potential dangers associated with holding scarf pins between teeth or lips.

CONFLICTS OF INTEREST

The authors declare no conflicts of interest.

Author Contributions

All authors have contributed to this study from conception, reading, and approving the latest version.

REFERENCES

1. Akbulut, S., Cakabay, B., Sezgin, A., Ozhasenekler, A., & Senol, A. (2009). Careless use of turban pins: a possible problem for turbaned patients. *Journal of Gastrointestinal Surgery*, 13(10), 1859-1863.
2. Goh, J., Patel, N., & Boulton, R. (2014). Accidental hijab pin ingestion in Muslim women: an emerging endoscopic emergency?. *Case Reports*, 2014, bcr2013202336.
3. Stricker, T., Kellenberger, C., Neuhaus, T., Schwoebel, M., & Braegger, C. (2001). Ingested pins causing perforation. *Archives of disease in childhood*, 84(2), 165.
4. Hong, K. H., Kim, Y. J., Kim, J. H., Chun, S. W., Kim, H. M., & Cho, J. H. (2015). Risk factors for complications associated with upper gastrointestinal foreign bodies. *World Journal of Gastroenterology: WJG*, 21(26), 8125.
5. Nicksa, G. A., Pigula, F. A., Giuffrida, M. J., & Buchmiller, T. L. (2009). Removal of a sewing needle from an occult esophageal ingestion in a 9-month-old. *Journal of pediatric surgery*, 44(7), 1450-1453.
6. Bocquet, N., Guillot, L., Mougenot, J. F., Ruemmele, F. M., & Cheron, G. (2005). Hematemesis in an 11-month-old child: an unusual symptom revealing a foreign body in the stomach. *Archives de Pediatrie: Organe Officiel de la Societe Francaise de Pediatrie*, 12(4), 424-426.
7. Palta, R., Sahota, A., Bemarki, A., Salama, P., Simpson, N., & Laine, L. (2009). Foreign-body ingestion: characteristics and outcomes in a lower socioeconomic population with predominantly intentional ingestion. *Gastrointestinal endoscopy*, 69(3), 426-433.
8. Sockeel, P., Massoure, M. P., Fixot, K., Chatelain, E., De Saint Roman, C., & Bredin, C. (2009). Foreign body perforation of the thoracic esophagus. *Journal de Chirurgie*, 146(1), 40-47.
9. Lin, H. H., Lee, S. C., Chu, H. C., Chang, W. K., Chao, Y. C., & Hsieh, T. Y. (2007). Emergency endoscopic management of dietary foreign bodies in the esophagus. *The American journal of emergency medicine*, 25(6), 662-665.
10. Elleuch, N., Sabbek, A., Slama, A. B., Hammami, A., Jaziri, H., Braham, A., ... & Jmaa, A. (2018). Ingestion accidentelle d'aiguilles: nouvelle circonstance de survenue. *Endoscopy*, 50(03), 000791.
11. Mir, S. A., Dar, H. M., Dogra, V., Gilkar, I. A., & Ahmad, M. M. (2015). Accidental ingestion of hairpins in adolescent Muslim girls while doing or undoing the headscarf. *International Surgery Journal*, 2(3), 377-380.
12. Naumeri, F., & Ahmad, H. M. (2017). Duodenocecal Fistula Developing after Hairpin Ingestion: A Case Report. *Annals of King Edward Medical University*, 23(2).
13. Michaud, L., Bellaïche, M., & Olives, JP (2009). Ingestion of foreign bodies in children. Recommendations of the French-speaking group of pediatric hepatology, gastroenterology and nutrition. *Archives of Pediatrics*, 16(1), 54-61.
14. Islam, S. R., Islam, E. A., Hodges, D., Nugent, K., & Parupudi, S. (2010). Endoscopic removal of multiple duodenum foreign bodies: an unusual occurrence. *World Journal of Gastrointestinal Endoscopy*, 2(5), 186.
15. Ikenberry, S. O., Jue, T. L., Anderson, M. A., Appalaneni, V., Banerjee, S., Ben-Menachem, T., ... & ASGE Standards of Practice Committee. (2011). Management of ingested foreign bodies and food impactions. *Gastrointestinal endoscopy*, 73(6), 1085-1091.
16. Kramer, R. E., Lerner, D. G., Lin, T., Manfredi, M., Shah, M., Stephen, T. C., ... & Mamula, P. (2015). Management of ingested foreign bodies in children: a clinical report of the NASPGHAN Endoscopy Committee. *Journal of pediatric gastroenterology and nutrition*, 60(4), 562-574.

Cite This Article: Meriem Boui, Zakaria Zouaki, Nabil Hammoune, Badr Slioui, Rachid Akka, Mehdi Atmane, Abdelilah Mouhsine (2023). Hairpin Ingestion, an Unusual Cause of Epigastralgia. *EAS J Radiol Imaging Technol*, 5(2), 37-41.