

Original Research Article

Appendicitis: Epidemioclinical and Histological Aspects at the Nianankoro Fomba Hospital in Segou

Dr. Samake Bréhima^{1*}, Keita M¹, Kone O², Kanthe D², Fomba D², Malle K⁴, Traore BZ¹, Kamate B⁵, Bah A¹, Kassogue A¹, Ongoiba S⁷, Koumare SB⁶, Prof Traore CB⁵

¹General Surgery Department of the Nianankoro Fomba Hospital in Segou, Mali

²General Surgery Department of the MARKALA Reference Health Centre, Mali

³Centre National de Recherche Scientifique et de Technologie (CNRST), Bamako, Mali

⁴Regional Health Directorate of Ségou, Mali

⁵G-Spot Anatomopathology Department, Mali

⁶Department of Surgery of the University Centre of Point G Hospital, Mali

⁷hopital Gavardo Bamako, Mali

Article History

Received: 18.04.2023

Accepted: 24.05.2023

Published: 27.05.2023

Journal homepage:

<https://www.easpublisher.com>

Quick Response Code



Abstract: Summary: This was a single-centre prospective descriptive study carried out in the general surgery department of the Nianankoro Fomba Hospital in Segou over a period of one year. We collected a total of 53 cases of acute appendicitis which represented 14.52% of our surgical activity, 22.36% of the surgical abdominal emergencies. The sex ratio was 2.1 in favour of the male. The clinical signs were polymorphous. Patients consulted for a painful abdominal syndrome most often located in the IDF, 81.1% of cases. Palpation revealed pain in the IDF in 52 (98%) patients, tenderness in the IDF in 21 (40%) patients. Abdominal contracture and a mass in 1(2%). The signs of BLUMBERG, ROVSING and PSOÏTIS were respectively: 58.4%; 0%; 0% of cases. The rectal examination was painful in 49.0% of cases. The postoperative course was simple in 38 patients (71.1%). Complications were observed in 28.3% of our patients, including 14 parietal suppurations, and we recorded 1 case of death. The average hospital stay was 6.4 days.

Keywords: Acute appendicitis, Emergency, Histology, Nianankoro Fomba Hospital in Segou.

Copyright © 2023 The Author(s): This is an open-access article distributed under the terms of the Creative Commons Attribution **4.0 International License (CC BY-NC 4.0)** which permits unrestricted use, distribution, and reproduction in any medium for non-commercial use provided the original author and source are credited.

I-INTRODUCTION

Acute appendicitis is an acute inflammation of the vermicular appendix. It is one of the most frequent emergencies in digestive surgery [1]. It can be seen at any age, but is especially common in children. Its diagnosis is clinical and it is generally accepted that there is no anatomical-clinical parallelism but that the essential prognostic factor is the time elapsed between the onset of signs and management [2].

Also its reputation for benignity is not entirely justified as people still die from appendicitis [1, 3]. Treatment is surgical: either a conventional appendectomy or a laparoscopic appendectomy. Acute appendicitis, is a widespread abdominal surgical emergency in industrialized countries where of the population is affected [4, 5]. 12% to 13% of the North American population are In Europe, it is the leading cause of surgical abdominal emergencies: 26% of digestive surgical emergencies in France [6].

In Dakar (Senegal) in 2014, a prospective necrotic study was carried out on subjects who died of appendicitis or one of its complications, among whom 51% had normal histology and 2% had bilharzian inflammation [7]. In Mali, a study showed that the frequency of acute appendicitis increased from 6.31% (1975) to 20.9% (2005) of surgical emergencies at Gabriel Touré Hospital [8]. In Gao in 2008, appendicular syndrome was the leading abdominal surgical emergency with 62% of cases [9]. In Segou in 2009, appendicitis represented 26.0% of surgical emergencies in adults; and in 2013, it represented 3.4% of pathologies acquired in children at the Nianankoro Fomba Hospital [10, 11]. To date, to our knowledge, no study has been carried out on the histological aspect of acute appendicitis at the Nianankoro Fomba Hospital in Segou. Our objective was to study acute appendicitis in the general surgery department of the Nianankoro Fomba Hospital in Segou.

*Corresponding Author: Dr. Samake Bréhima

General Surgery Department of the Nianankoro Fomba Hospital in Segou, Mali

II-METHODOLOGY

It was a prospective, descriptive, mono-centric study from December 1, 2021 to November 30, 2022, i.e. a period of one (1) year in the general surgery department of the Nianankoro FOMBA hospital in Segou: - An acute appendicitis confirmed by histology during our study period, an appendicular plastron, an appendicular abscess, were not included in our study: -

All cases of appendicitis with an incomplete medical file. All cases of appendicitis with incomplete medical records. -Appendectomy cases that were not subjected to anatomopathological examination.

III-RESULTS

Frequency

Table I: Frequency of acute appendicitis in the general surgery department

Surgical pathology	Workforce	Percentage (%)
Hernia (umbilical- inguinal)	131	26,7
Intestinal obstruction	77	15,7
Peritonitis	74	15,1
Acute appendicitis	72	14,5
Hemoperitoneum	24	4,9
Adenoma of the prostate	19	3,8
FVV	19	3,8
Post event operating	14	2,8
Abscess and Necrosectomy	14	2,8
Bladder lithiasis and stenosis of the bladder neck	9	1,8
Haemorrhoids and fistula anal	9	1,8
Hydrocele	8	1,6
Perforation digestive no appendicular	6	1,3
Liver abscesses	5	1,0
Splenectomy	5	1,0
Cholecystitis	4	0,8
Total	489	100

Acute appendicitis has been the focus of the fourth place in the surgical activity.

Table II: Frequency in relation to surgical emergencies

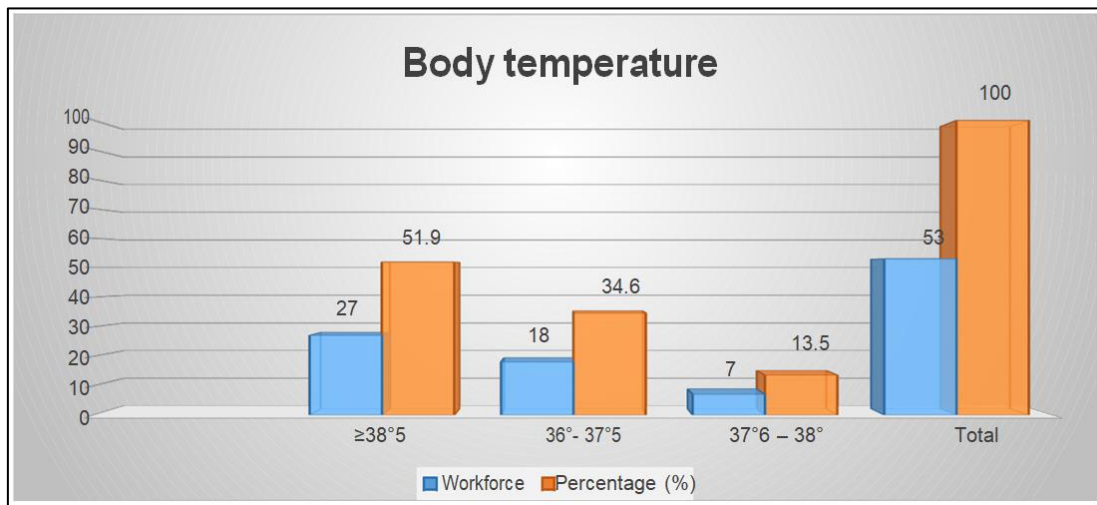
Surgical pathology	Workforce	Percentage(%)
Intestinal obstruction	77	23,91
Peritonitis	74	22,98
Acute appendicitis	72	22,36
Strangulated hernia	46	14,28
Hemoperitoneum	24	7,45
Hemorrhoidal thrombosis	9	2,8
Digestive perforation no appendicular	6	1,86
Liver abscesses	5	1,55
Splenectomy	5	1,55
Acute cholecystitis	4	1,24
Total	322	100

Acute appendicitis was the third most common surgical emergency with 22.36%.

Table III: Distribution by age group

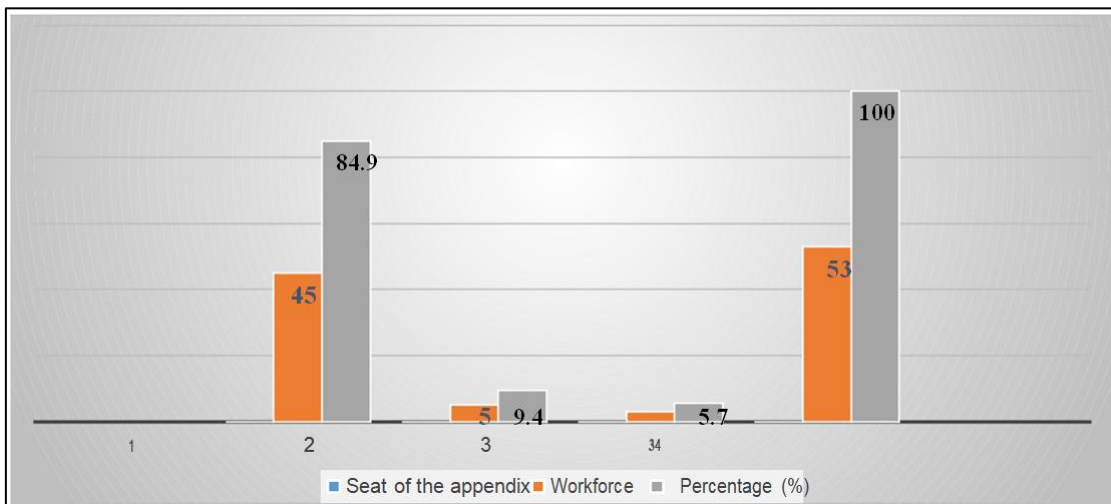
Age range (years)	Workforce	Percentage (%)
6-15	12	23
16-25	14	26,4
26-35	14	26,4
36-45	5	9,4
46-55	5	9,4
56-65	2	4
66-72	1	2
Total	53	100

The mean age was 27.92±14.92 years with extremes of 7 and 72 years.



Graph I: Distribution of patients by body temperature

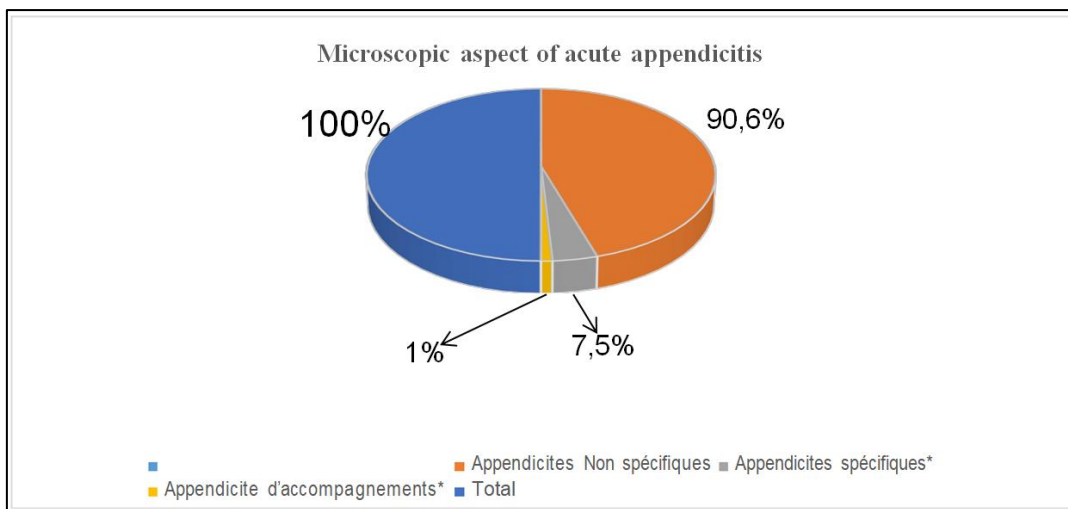
Hyperthermia was present in 51.9% of cases.



Graph II: Distribution of patients according to the location of the appendix

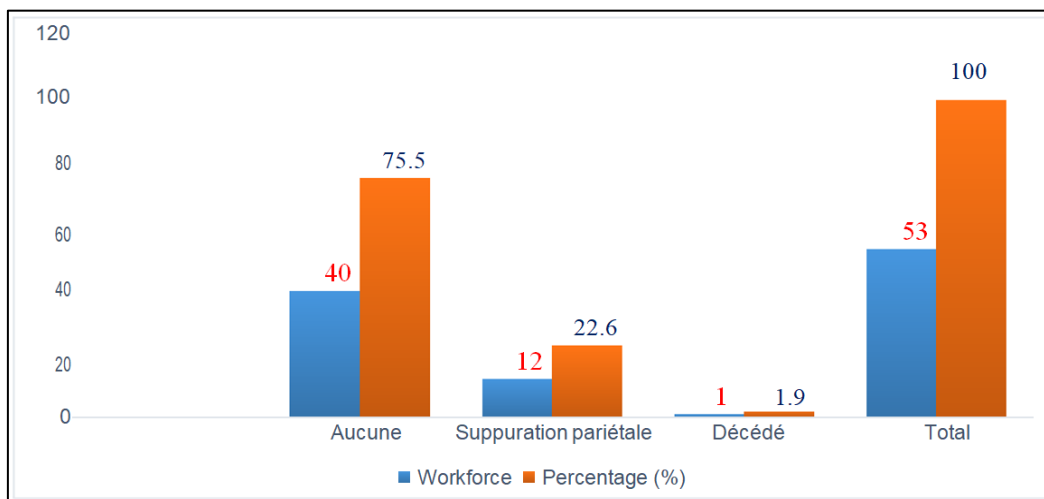
Table IV: Distribution according to macroscopic appearance

Macroscopic appearance	Workforce	Percentage(%)
Catarrhal appendicitis	19	35,8
Appendicitis phlegmoner	18	34
Perforated appendix	6	11,3
Gangrenous appendicitis	5	9,4
Appendicular abscess	2	3,8
Appendicular peritonitis	2	3,8
Appendicular mucocele	1	1,9
Total	53	100



Graph III: Distribution according to microscopic aspect

Specific appendicitis: Schistosomes haematobium
Accompanying appendicitis: Simple mucocele



Graph IV: Distribution of patients by type of complication

Complications such as parietal suppurations accounted for 75.5% of cases.

IV. COMMENTS AND DISCUSSION

Our study was carried out in the general surgery department of the Nianankoro Fomba Hospital in Segou. We collected 53 cases of acute appendicitis over a period of one (1) year. One of the problems encountered was the performance of the histological examination because we do not have this service in Segou and the transport to Bamako (Point-G) is often difficult, the low purchasing power of the rural population of Segou. During our study period, 489 surgical operations were performed, including 322 cases of surgical emergencies. We recorded 71 cases of acute appendicitis for which histology was performed on 53 patients, i.e. 14.52% of the department's surgical activity and 22.04% of surgical emergencies.

Appendicitis was the third most common surgical emergency in our study. This result is similar to

that of Yalcouye Y [16] who reported that appendicitis was the 2nd most frequent surgical emergency in the hospital of Sikasso. On the other hand, in Markala (Mali) Diarra M [16] and in France Rohrs *et al.*, [3] classified acute appendicular syndrome as the leading etiology in abdominal surgical emergencies. (p=0,53)

Appendicitis is mainly a disease of young people, and is rare in the elderly [11, 15, 16].

The majority of our patients were young (16-35 years). The average age of our patients was 27.92 years. This notion of young age found also by other authors [10, 19] is in agreement with the general literature [19]. It is important to emphasise the diagnostic difficulties of the condition in young children and the elderly.

We found a sex ratio of 2.1 in favour of men. In several studies [9, 10, 18-20], like ours, male predominance has been the rule. Explanations for this male predilection remain controversial and some studies have shown the opposite [10, 13]. This is probably due to the different ways of recruiting patients, depending on the department

The majority of our patients (71.7%) resided in Ségou, followed by Niono (11.3%), San (7.5%), Baraouéli (3.8%), Bla (1.9%) and Bamako (1.9%). The predominance of Ségou can be explained by the influence of the place of study, as the other localities concerned had referred complicated forms due to the inadequacy of the surgical technical platform.

Classically, appendicular pain occurs in the right iliac fossa and is the main symptom of appendicitis.

During our study period, IDF was the most frequent site of pain (81.1% of cases), as evidenced by the literature and studies in Kenya with a frequency of 62.2% [18] and in Niger it was 80% [2] ($p=0,86$).

Nevertheless, the atypical location of the pain, as in some of our patients, should not lead to the dismissal of the diagnosis, especially when the subject is young.

We found localized pain in the right iliac fossa without any radiation in 54.7% of our patients. In 45.3% of cases it was without radiation. According to the literature, radiation of appendicular pain is rare. Thus, its presence should suggest another pathology or a complication [3].

Usually appendicular pain is accompanied by digestive problems such as vomiting or nausea.

Vomiting attracts attention, but may be replaced by nausea. This notion is found in several series [10, 11] like ours ($p=0,57$). Constipation is of no diagnostic interest and may be replaced by diarrhoea, which accounted for 1.9% and 3.8% respectively in our patients.

Urinary disorders such as dysuria, pollakiuria or acute retention of urine were reported in 9.4% of cases in our patients and are most often found in pelvic appendicitis [3].

Typically, patients with acute appendicitis have a fever. The average temperature was around 38-38.5°C. In our study it was found in the majority of cases (51.2%). This notion was reported by Coulibaly M [19] and Yalcouye Y [18] who found respectively 58.5% in a series of 253 cases and 51.9% in a series of 103 cases.

A normal temperature may be accompanied by severe anatomical lesions in acute appendicitis, this reflects the absence of anatomical-clinical parallelism, but the presence of high fever (39-40°C) is a sign of complication.

Three physical signs are essential for the diagnosis of appendicitis [3]:

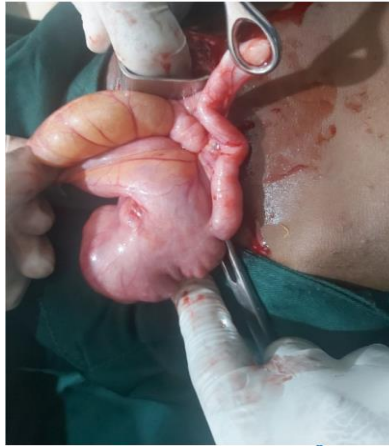- Pain in the right iliac fossa, Defence in the right iliac fossa, Pain on pelvic touch. The pain provoked in the IDF may be sharp, localised to Mac Burney's point or, on the contrary, spread out and more muted. Its persistence during successive examinations even in the absence of any other sign can be in favour of the diagnosis of acute appendicitis. It was noted in 58% of cases in our case, 98.1% reported by Diarra M [16], 91% reported by Yusuf M *et al.*, This pain can be revealed by various manoeuvres: Blumberg's sign, which is a pain appearing on sudden decompression of the IDF, was observed in 58% of our patients ($p<0.05$). Rovsing's sign is a pain appearing in the IDF by compression of the FIG, it was not found in our patients. Psoitis was not found in our study.
- Parietal defence in IDF, resulting from irritation of the peritoneal serosa due to inflammation, was noted in 40% of cases in our study, 51% were reported by Yusuf M *et al.*, Diarra M. found 14.1%.
- Pain on pelvic touch: this is a sign that must be systematically sought even if its absence does not always mean that the appendix is free of lesions [3], it is a pain located on the right in the cul de sac of Douglas on TR and/or TV. It was observed in 79.24% of our patients, Yusuf M *et al.*, [11] found 45%, Diarra M [56] found 82.5%.

We agree with the authors that these three physical signs are essential in the diagnosis of appendicitis. They have been frequently noted in several series [9, 10, 11], such as ours. We found a mass in the right iliac fossa in 2% of cases. This most often corresponded to cases of plastron or appendicular abscess. On the other hand, some European authors [12, 13] did not report any cases. This could be explained by the fact that our patients consulted late.

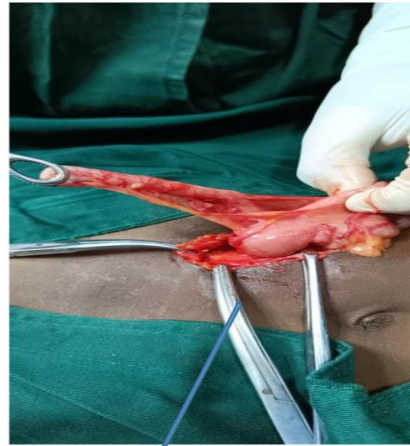The IDF was the main site of the appendix in our patients (77.4% of cases). As shown in the general literature as well as in studies that have been done in France [21] and Niger [2] ($p<0.05$).

During our study period all resected appendages had a macroscopic pathological appearance.

Catarrhal appendicitis was found in (39.6%) of our patients ($p=0.36$).



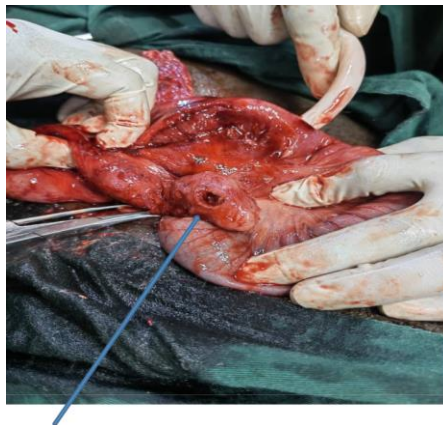CATARHAL



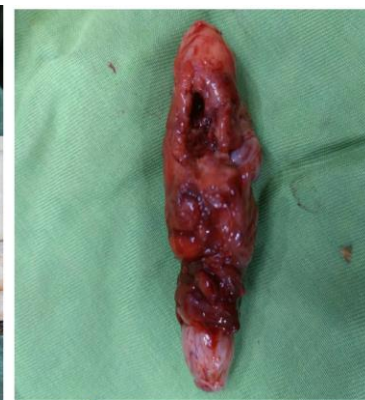APPENDICITIS

In the majority of cases in our study (58.5%), these were advanced forms, in contrast to a Mexican

series [14] where advanced forms represented only 27.1% ($p < 0.05$).



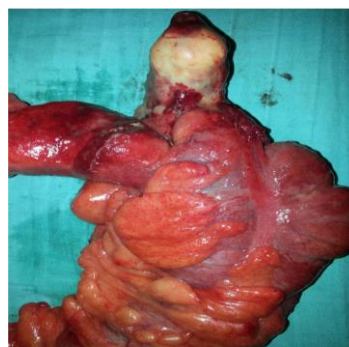
APPENDICULAR ABSCESS



APPENDECTOMY PIECE

This could be linked to a delay in diagnosis often attributed to the ignorance of our populations who always tried either a traditional treatment before medical consultation, or self-medication. These factors, which are always interrelated, explain the stage of the disease at the time of admission. Other authors [10] state that 69% of perforated or gangrenous appendicitis occurred in an ectopic appendix. On histology, we collected 4 cases of parasitic appendicitis (*Bilharzia*) i.e. 7.5%, which largely exceeds the results of the

studies of Adébamowo CA (Nigeria) [20] and Hodasi WM (Ghana) [18] which are respectively 2.4%; 2.9%, 48 cases of non-specific appendicitis i.e. 90.6%, and we report 1 case of appendicular Mucocele (benign tumour) i.e. 1.9%. We know that appendices removed surgically for a clinical picture of appendicitis correspond most frequently to non-specific inflammatory lesions and rarely to lesions of tumoral origin, which confirms our results [20] ($p = 0.11$).



APPENDICULAR MUCOCELE

CONCLUSION

Acute appendicitis is one of the most frequent surgical emergencies in digestive surgery, its diagnosis essentially clinical, sometimes made difficult by the absence of anatomical-clinical parallelism linked to the polymorphism of the lesions and the variations in the position of the organ in the abdominal cavity. If left untreated, it can lead to serious complications (generalised peritonitis). It is a condition with low morbidity and mortality provided that it is diagnosed and treated surgically at an early stage.

BIBLIOGRAPHIC REFERENCES

1. Delattre, J. F. (1994). Appendicite aigue et ses complications diagnostic, Traitement impact internat 1997; 356. *Scand j gasterol*, 29, 1145-1149.
2. Harouna, Y., Amadou, S., Gazi, M., Gamatie, Y., Abdou, I., Omar, G. S., ... & Boureima, M. (2000). Appendicitis in Niger: current prognosis. *Bulletin de la Societe de Pathologie Exotique (1990)*, 93(5), 314-316.
3. Ohle, R., O'Reilly, F., O'Brien, K. K., Fahey, T., & Dimitrov, B. D. (2011). The Alvarado score for predicting acute appendicitis: a systematic review. *BMC medicine*, 9, 1-13
4. Thiam, I., Doh, K., & Dial, C. (2016). Necropsy study of the appendix in Senegal. *Afr Hepato gastro enteral*, 10, 73.
5. Fane, Y. (2017). Digestive surgical emergencies: diagnosis and management. These de medecine 2017 Bamako. N°208.
6. Chavda, S. K., Hassan, S., & Magoha, G. A. O. (2005). Appendicitis at Kenyatta national hospital, Nairobi. *East African Medical Journal*, 82(10), 526-30.
7. Flum, D. R., Morris, A., Koepsell, T., & Dellinger, E. P. (2001). Has misdiagnosis of appendicitis decreased over time?: a population-based analysis. *Jama*, 286(14), 1748-1753.
8. Konaté, M. (2005). Surgical emergencies at Gabriel Touré Hospital These Med: Bamako, 2005-91P; 238.
9. Ohle, R., O'Reilly, F., O'Brien, K. K., Fahey, T., & Dimitrov, B. D. (2011). The Alvarado score for predicting acute appendicitis: a systematic review. *BMC medicine*, 9, 1-13.
10. Mallé, L. (2013). The surgical pathologies of children aged 0-15 years at the Nianankoro Fomba Hospital in Ségou Med thesis: 2013-60P; 96.
11. Maiga, I. E. (2005). Etude Epidemio-clinique et l'aspect thérapeutique des appendicites aigue à l'hôpital Nianankoro Fomba de Ségou. 2009-56P; 82.Thèse Méd: Bamako, 2005- 63P; 203.
12. Maiga, A. (2002). Bilharzian appendicitis in the general surgery department of Point G hospital from January 2001 to June 2001.Thesis Med: Bamako, 2002- 44P; 56.
13. Koiner H., Soreide Ja, Pedersen EJ. et al. Stability in incidence of acute appendicitis:A population based longitudinal study dig surg 2001 ; 18 ; 16.
14. Sidibé, B. (2002). Ultrasound anatomy of the appendix Medical thesis: Bamako, 2002-30P; 80.
15. Mumtaz, K. H. (2017). Effectiveness of conservative management of uncomplicated acute appendicitis: A single hospital based prospective study. *International Journal of Surgery Open*.
16. Yalcouye, Y. (2007). Appendicite aigue à l'hôpital de Sikasso ; Thèse méd : Bamako, 2007-67p ; 9.
17. Körner, H., Söndena, K., Söreide, J. A., Nysted, A., & Vatten, L. (2000). The History Is Important in Patients with Suspected Acute Appendicitis/with Invited Commentary. *Digestive surgery*, 17(4), 364-369.
18. Baba, S. (2011). Management of appendicitis in the surgical service 'A' of the CHU of point-'G' from 1998 to November 2010 Thesis of Medicine 2011. N°174
19. Diop, P. S., Ndoeye, & Fall, B. (2008). Laparoscopic appendectomy: a Dakar experience in 29 cases. *Black African Medicine*, 55(11), 602-604.
20. Ohene-Yeboah, M., & Togbe, B. (2006). An audit of appendicitis and appendectomy in Kumasi, Ghana. *West Afr J Med*, 25, 138-43.

Cite This Article: Samake Bréhima, Keita M, Kone O, Kanthe D, Fomba D, Malle K, Traore BZ, Kamate B, Bah A, Kassogue A, Ongoiba S, Koumare SB, Prof Traore CB (2023). Appendicitis: Epidemioclinical and Histological Aspects at the Nianankoro Fomba Hospital in Segou. *East African Scholars J Med Surg*, 5(4), 37-43
