

Case Report

Giant Synovial Chondromatosis of the Shoulder: The Limits of Arthroscopic Treatment and Technical Tips

Chedi Saadi^{1*}, Mehdi Bellil¹, Souheil Ketata¹, Mohamed amine Jaouedi¹, Mohamed ben salah¹, Mondher Kooli¹

¹Orthopaedic Surgery Department, Charles Nicolle Hospital, Tunis, Tunisia , University of Tunis El Manar, Tunis, Tunisia

Article History

Received: 02.08.2023

Accepted: 08.09.2023

Published: 28.09.2023

Journal homepage:

<https://www.easpublisher.com>

Quick Response Code



Abstract: Synovial chondromatosis (SC) is a rare disease. It is a chondrocytic metaplasia and is characterized by the presence of cartilaginous loose bodies in the involved joint, bursa or tendon sheath, it occurs most often in those aged 30_50 years and 3 times more in males than females, The shoulder is an exceptional location. It causes significant functional disability in young people. The clinical presentation is not specific, and the diagnosis is based on MRI. Confirmation is still anatomopathological. Classically, the mainstay treatment for SC of the shoulder has been open arthrotomy and removal of loose bodies, followed by either complete or partial synovectomy, removing the affected tissue, with recent advances in arthroscopic techniques and methods, arthroscopy becomes the gold standard. We present this case report of a 26-year-old man, who was left-hand dominant, a maintenance technician, amateur football player presented a left shoulder inflammatory pain; ; plain radiography demonstrated multiple calcific densities over the glenohumeral joint , the MRI showed multiple calcified intra-articular loose bodies around the anterior and posterior joint and axillary recess ; At arthroscopy, a large number of loose bodies were observed together with marked synovitis ,it only allowed the removal of small foreign bodies < 1 cm, partial synovectomy was performed with a shaver ; anatomopathological examination confirmed the diagnosis of sc. the extraction of giant fragments >2 cm was impossible so it was subsequently removed by open surgery. This was carried out one month later using a delto-pectoral approach: all foreign bodies > 1 cm were successfully extracted. We report this case report in order to review the role of shoulder arthroscopy and magnetic resonance imaging (MRI) in diagnosis and treatment and to highlight the operative difficulties, technical tips of arthroscopic extraction of giant Synovial chondromatosis of the shoulder.

Keywords: Synovial Chondromatosis, Giant, Arthroscopy, Shoulder.

Copyright © 2023 The Author(s): This is an open-access article distributed under the terms of the Creative Commons Attribution **4.0 International License (CC BY-NC 4.0)** which permits unrestricted use, distribution, and reproduction in any medium for non-commercial use provided the original author and source are credited.

INTRODUCTION

Synovial chondromatosis (SC) is a rare disease. It is a chondrocytic metaplasia and is characterized by the presence of cartilaginous loose bodies in the involved joint, bursa or tendon sheath, It occurs most often in those aged 30_50 years and 3 times more in males than females, The shoulder is an exceptional location. It causes significant functional disability in young people. The clinical presentation is not specific, and the diagnosis is based on MRI. Confirmation is still anatomopathological. Classically, the mainstay treatment for SC of the shoulder has been open arthrotomy and removal of loose bodies, followed by either complete or partial synovectomy, removing the affected tissue, with recent advances in arthroscopic

techniques and methods, arthroscopy becomes the gold standard.

We present this case report in order to review the role of shoulder arthroscopy and magnetic resonance imaging (MRI) in diagnosis and treatment and to highlight the operative difficulties of arthroscopic extraction of giant Synovial chondromatosis of the shoulder.

CASE REPORT

A 26-year-old man, who was left-hand dominant, a maintenance technician, amateur football player presented a left shoulder inflammatory pain, which had been begin for 1 year and for which no

*Corresponding Author: Chedi Saadi

Orthopaedic Surgery Department, Charles Nicolle Hospital, Tunis, Tunisia , University of Tunis El Manar, Tunis, Tunisia

treatment had been received, . there was no history of trauma and no medical problems , clinical examination showed limited abduction and external rotation ; plain radiography demonstrated multiple calcific densities over the glenohumeral joint, the MRI showed multiple calcified intra-articular loose bodies around the anterior and posterior joint and axillary recess ; At arthroscopy, a large number of loose bodies were observed together with marked synovitis ,it only allowed the removal of small foreign bodies <1cm, partial synovectomy was performed with a shaver; anatomopathological examination confirmed the diagnosis of sc. The

extraction of giant fragments >2 cm was impossible so it was subsequently removed by open surgery. This was carried out one month later using a delto- pectoral approach: all foreign bodies > 1 cm were successfully extracted.

The patient had post-operative rehabilitation, he presented with no pain and normal shoulder function at the 3- month follow-up, One year after the operation, the patient was free from pain and plain radiography showed no sign of recurrence.

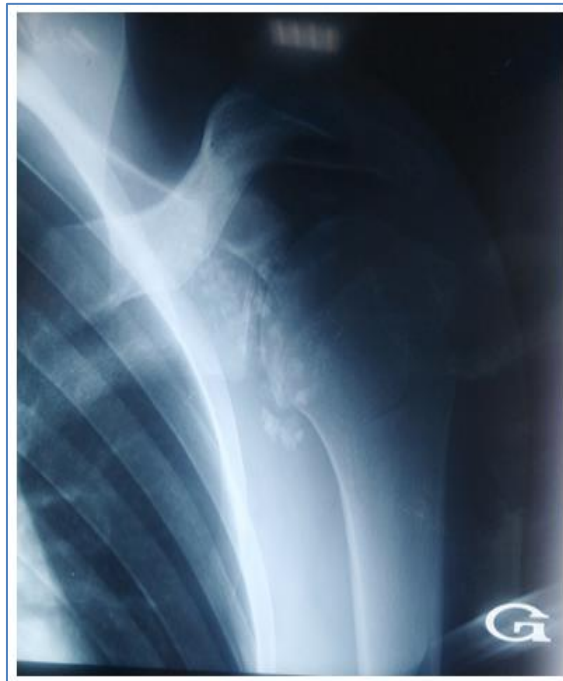

Figure 1: Plain radiography of the shoulder demonstrating multiple calcified intra-articular loose bodies

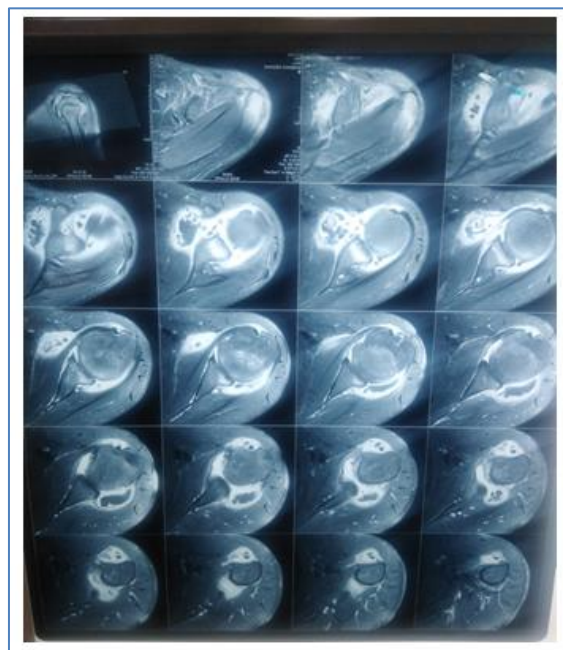


Figure 2: Axial MRI demonstrating location and morphology of calcified loose bodies within glenohumeral joint

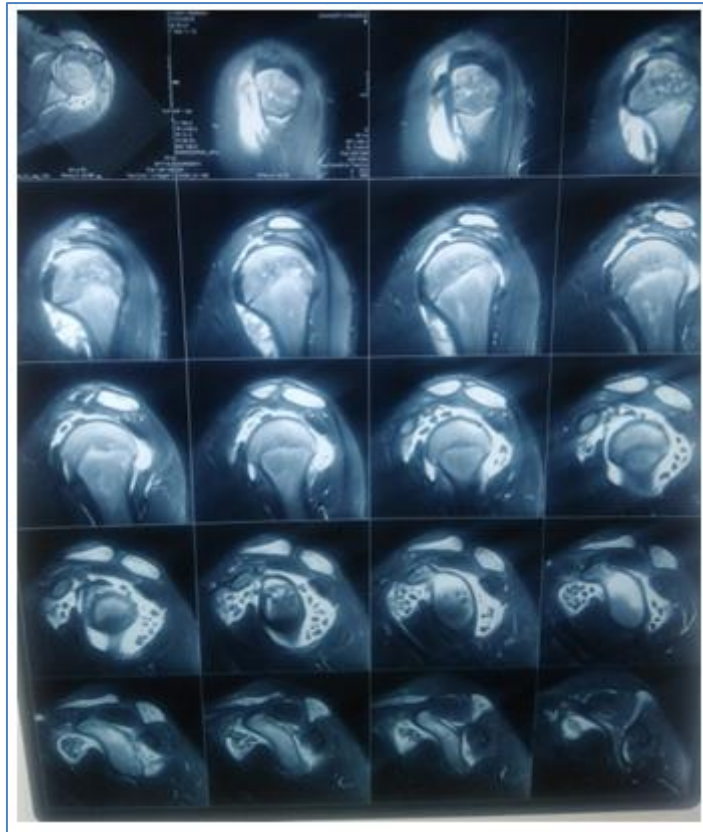


Figure 3: MRI coronal oblique. Loose bodies in the bicipital groove and axillary recess,

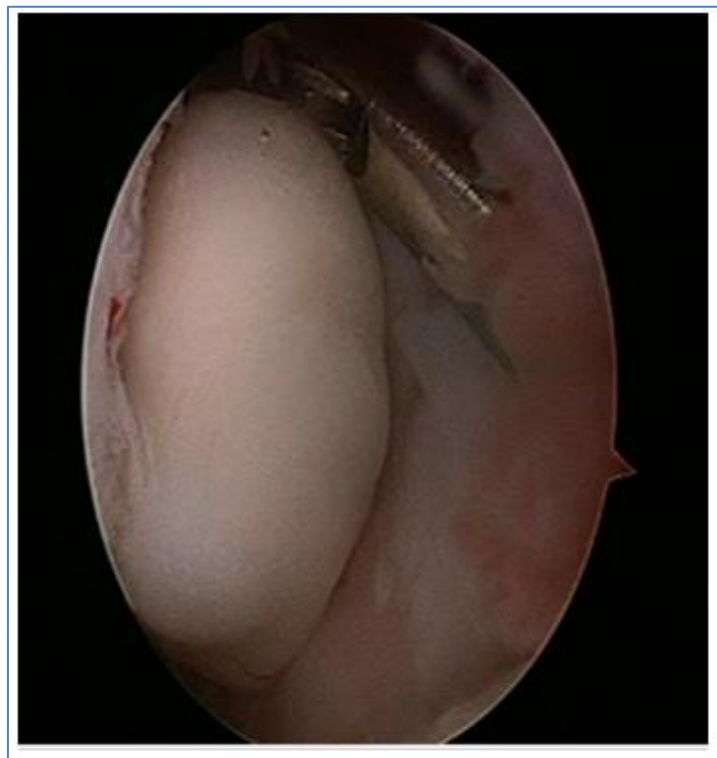


Figure 4: large free fragment within the joint: arthroscopic view

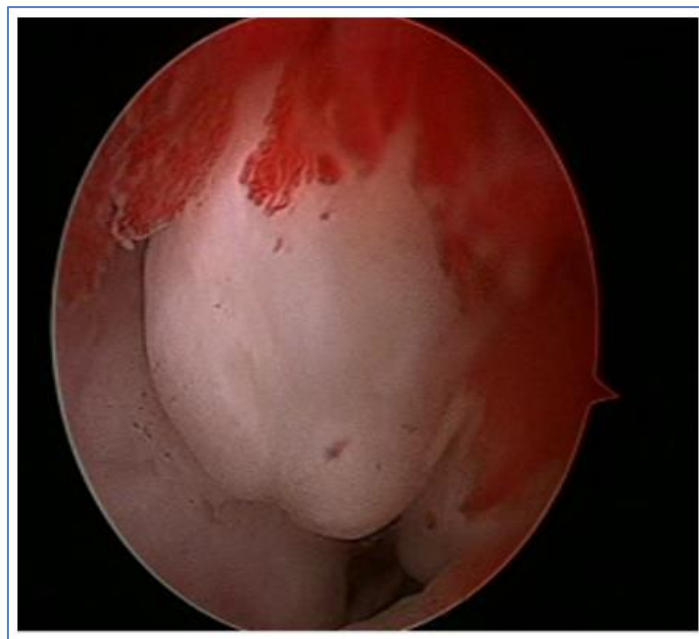

Figure 5: large free fragment >2.5 cm within the joint: arthroscopic view

DISCUSSION

Synovial chondromatosis in the shoulder have been rarely reported in literature. In three reported case series of synovial osteochondromatosis involving almost 100 patients, the shoulder was affected in only five patients [1]. The exact incidence is unclear [2]. The etiology of SC is still unknown, but recent laboratory research suggests the possible role of bone morphogenetic protein (BMP) in inducing it [3]. Synovial osteochondromatosis can be considered either primary (idiopathic) or secondary, occurring as a sequelae of intra-articular pathology, like an intra-articular trauma, rheumatoid arthritis and tubercular arthritis...[2]. The presence of true cartilaginous metaplasia is an important diagnostic feature of SC [3].

Symptoms are often non-specific, the clinical signs of pain, swelling and reduced range of movement overlap with many other disorders like our case [2], plain radiography showed Multiple intra-articular calcifications of a similar size and shape distributed throughout the joint; CT and MR imaging depict the extent of the synovial disease (particularly surrounding soft-tissue involvement) and lobular growth. Secondary synovial chondromatosis can be distinguished from primary disease both radiologically (underlying articular disease and fewer chondral bodies of variable size and shape) and pathologically (concentric rings of growth) [1], and MRI shows the precise localization of the chondromas, thus helping to decide whether radical extraction is possible by arthroscopy [3].

Surgical excision of the loose bodies, and synovectomy is the usual treatment [4], Both open and closed arthroscopic methods can be used in the treatment of synovial chondromatosis [5], the advantages of arthroscopic treatment include good

visualisation, low morbidity, rapid healing and early rehabilitation [6], the disadvantage is that synovectomy is more limited but there is no conclusive evidence that an open procedure confers any advantage with regard to recurrence [5], the arthroscopic difficulties in our case were access to bicipital groove, axillary recess and the extraction of loose bodies >2.5 cm with ordinary cannula, so open surgery was used. Buess and Friedrich report that the removal of chondromas of the axillary recess and the biceps tendon sheath would be difficult to achieve by arthroscopy alone; arthroscopy coupled with a mini- approach is possible [7]. management of giant SC requires surgical planning based on analysis of MRI and CT to determine the location and calculate the diameters of loose bodies; Measuring the diameters of all the lesions on CT in preoperative planning would ensure planning the use of a cannula of sufficient diameter and would avoid the technical difficulties experienced during surgery in the current case [8]. in the opinion of Jeon *et al.*, arthroscopic removal of loose bodies from the bicipital groove and axillary recess can be performed using straight clamps [9], Bruggemann *et al.*, reported that the placement of a wide cannula and high pressure and flow from the anterior portal could be useful for arthroscopic removal of the free fragments from the glenohumeral joint [9].

CONCLUSION

Giant Synovial chondromatosis of the shoulder is a rare condition and Arthroscopic difficulties can be expected. Conversion to open surgery is not a failure, the most important thing is to remove the loose bodies with a wide synovectomy. The Extraction of giant SC would require special large cannula.

DECLARATION OF INTERESTS: None

CONSENT: A written informed consent was obtained from the patient for publication of this case report and accompanying images

REFERENCES

1. Murphey, M. D., Vidal, J. A., Fanburg-Smith, J. C., & Gajewski, D. A. (2007). Imaging of synovial chondromatosis with radiologic-pathologic correlation. *Radiographics*, 27(5), 1465-1488.
2. Poyser, E., Morris, R., & Mehta, H. (2018). Primary synovial osteochondromatosis of the shoulder: a rare cause of shoulder pain. *BMJ Case Reports CP*, 11(1), e227281.
3. Buess, E., & Friedrich, B. (2001). Synovial chondromatosis of the glenohumeral joint: a rare condition. *Archives of orthopaedic and trauma surgery*, 121, 109-111.
4. Lunn, J. V., Castellanos-Rosas, J., & Walch, G. (2007). Arthroscopic synovectomy, removal of loose bodies and selective biceps tenodesis for synovial chondromatosis of the shoulder. *The Journal of Bone & Joint Surgery British Volume*, 89(10), 1329-1335.
5. Park, J. P., Marwan, Y., Alfayez, S. M., Burman, M. L., & Martineau, P. A. (2022). Arthroscopic management of synovial chondromatosis of the shoulder: a systematic review of literature. *Shoulder Elb. Juill*, 14(1 Suppl), 5-15.
6. Tokis, A. V., Andrikoula, S. I., Chouliaras, V. T., Vasiliadis, H. S., & Georgoulis, A. D. (2007). Diagnosis and arthroscopic treatment of primary synovial chondromatosis of the shoulder. *Arthroscopy: The Journal of Arthroscopic & Related Surgery*, 23(9), 1023-e1.
7. Raval, P., Vijayan, A., & Jariwala, A. (2016). Arthroscopic retrieval of over 100 loose bodies in shoulder synovial chondromatosis: a case report and review of literature. *Orthopaedic surgery*, 8(4), 511-515.
8. Duymus, T. M., Yucel, B., Mutlu, S., Tuna, S., Mutlu, H., & Komur, B. (2015). Arthroscopic treatment of synovial chondromatosis of the shoulder: A case report. *Annals of Medicine and Surgery*, 4(2), 179-182.
9. Bruggeman, N. B., Sperling, J. W., & Shives, T. C. (2005). Arthroscopic technique for treatment of synovial chondromatosis of the glenohumeral joint. *Arthroscopy: The Journal of Arthroscopic & Related Surgery*, 21(5), 633-e1.

Citation: Chedi Saadi, Mehdi Bellil, Souheil Ketata, Mohamed amine Jaouedi, Mohamed ben salah, Mondher Kooli (2023). Giant Synovial Chondromatosis of the Shoulder: The Limits of Arthroscopic Treatment and Technical Tips. *EAS J Orthop Physiother*, 5(5): 61-65.
