

Diagnosis of Gamma Heavy Chain Disease: About A Case Report

Adjimon Ganhoutode(MD)^{1,2*}, Imane Zouaoui (MD)^{1,2}, Asma Oukhatar(Pharm D)^{1,2}, Asmae Biaz(Pharm D)^{1,2}, Sanae Bouhsain (Pharm D)^{1,2}, Abdellah Dami(Pharm D)^{1,2}, Samira Elmachtani idrissi(Pharm D)^{1,2}

¹Faculty of Medicine and Pharmacy of Rabat Morocco

²Biochemistry and Toxicology Laboratory, Mohammed V Military Hospital, Rabat

*Corresponding author: Adjimon Ganhoutode | Received: 28.09.2023 | Accepted: 01.11.2023 | Published: 14.11.2023 |

Abstract: Introduction: Heavy chain disease (HCD) is characterized by the production of a truncated heavy chain monoclonal immunoglobulin lacking the corresponding light chains. The aim is to highlight the difficulties associated with the biological diagnosis of this pathology. **Observation:** Serum protein electrophoresis showed hypogammaglobulinemia with restricted gammaglobulin heterogeneity and a peak migrating into the beta-2 globulin zone. Immunofixation revealed a monoclonal band in the gamma heavy chain, with no correspondence with the Kappa or Lambda light chains. **Conclusion:** The observation we have presented reveals that the diagnosis of gamma heavy chain disease is delicate and relies on several techniques.

Keywords: Gamma heavy chains, monoclonal band, restricted gammaglobulin heterogeneity, beta-2 globulin zone, immunoglobulin.

INTRODUCTION

Heavy chain disease (HCD) is a lymphoplasmacytic neoplasia. Gamma heavy chain disease is a lymphoplasmacytic neoplasia. It is characterized by the production of a truncated gamma immunoglobulin heavy chain lacking the corresponding light chains. It is classified according to the heavy chain involved: α for the A chain, γ for the G chain, μ for the M chain [1].

Gamma-heavy chain disease (γ HCD) was first described in 1964 by Franklin. It is a rare hemopathy, with around 150 cases reported to date [2]. Clinical manifestations are varied and depend on the isotype of the chain involved, ranging from asymptomatic to aggressive lymphoma. Its diagnosis is biological. This study aims to present a case of γ HCD, while highlighting the difficulties associated with the biological diagnosis of this pathology.

OBSERVATION

Mrs. M, aged 58, was admitted to internal medicine for an altered general condition. Her history

included asymptomatic cold agglutinin disease, and vesicular lithiasis. Her history dates back to 2017, with the chance discovery of splenomegaly without cytopenia or adenopathy during the preoperative workup for lithiasis. She has not been seen since and returned to the clinic four years later (2021) with an altered general condition. Clinical examination revealed a tumor syndrome including splenomegaly, hepatomegaly, and deep polyadenopathy without superficial adenopathy, suggesting hematologic malignancy.

The hemogram revealed aregenerative pancytopenia with normocytic anemia. The myelogram revealed no bone marrow infiltration and no significant plasmacytosis (3%). Plasma lactate dehydrogenase was normal, and Beta-2 microglobulin was elevated (11 mg/L), with hypoprotidemia at 45g/L. Serum protein electrophoresis on Capillary2 (Sebia) showed a moderate inflammatory syndrome associated with hypogammaglobulinemia with restricted gamma globulin heterogeneity and a peak migrating into the beta 2 globulin zone (Figure 1).

Quick Response Code



Journal homepage:

<https://www.easpublisher.com/>

Copyright © 2023 The Author(s): This is an open-access article distributed under the terms of the Creative Commons Attribution 4.0 International License (CC BY-NC 4.0) which permits unrestricted use, distribution, and reproduction in any medium for non-commercial use provided the original author and source are credited.

Citation: Adjimon Ganhoutode, Imane Zouaoui, Asma Oukhatar, Asmae Biaz, Sanae Bouhsain, Abdellah Dami (2023). Diagnosis of Gamma Heavy Chain Disease: About A Case Report. *Cross Current Int J Med Biosci*, 5(4), 84-87.

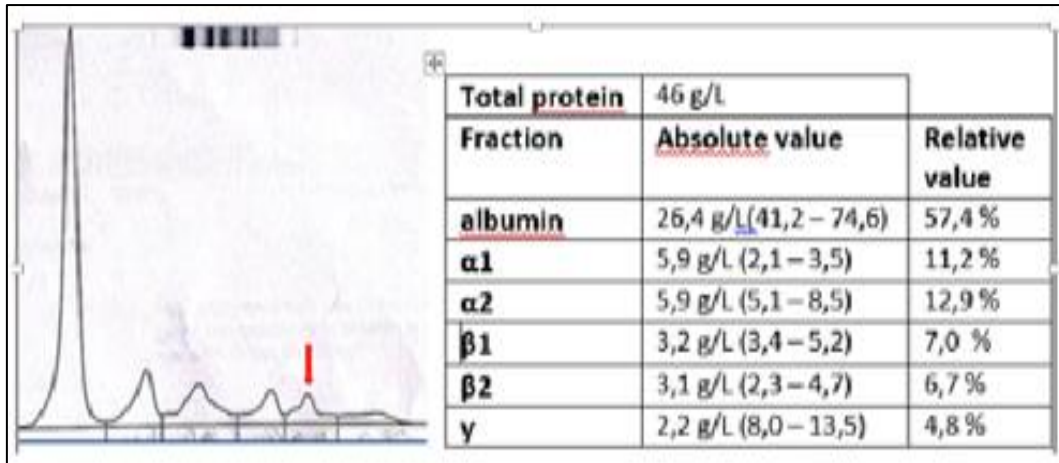


Figure 1: Serum protein electrophoresis on Capillary2 (Sebia).

Serum and urine agarose gel immunofixation (Hydrasys 2, Sebia) revealed a monoclonal band in the gamma heavy chain with no correspondence to the Kappa or Lambda light chains, raising suspicion of γ HCD (Figure 2). Immunosubtraction confirmed the

presence of a monoclonal IgG protein not associated with a light chain (Figure 3). raising suspicion of γ HCD. Immunosubtraction confirmed the presence of a monoclonal IgG protein not associated with a light chain.

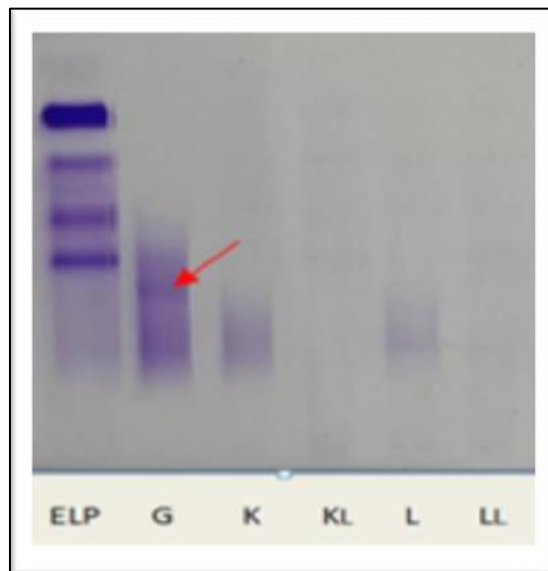


Figure 2: Serum agarose gel immunofixation (Hydrasys 2, Sebia)

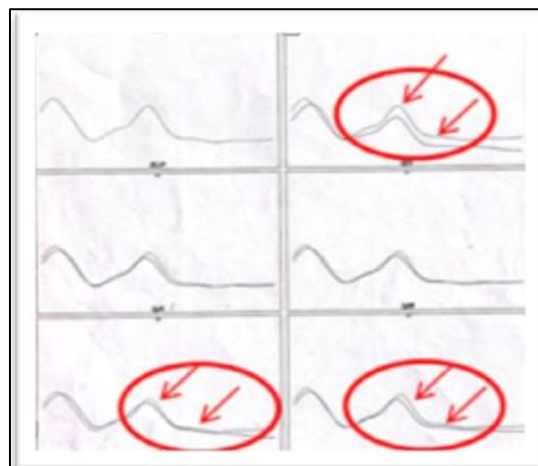


Figure 3: Serum protein immunosubtraction on Capillary2 (Sebia).

The thoracic-abdomino-pelvic scan revealed suspicious bilateral pulmonary nodules with supra- and subdiaphragmatic adenopathies and hepatosplenomegaly suggestive of hematologic malignancy.

Biopsies (osteomedullary, splenic, and right iliac ADP excision) showed no sign of malignancy. She was then transferred to the clinical hematology department for management of gamma heavy chain disease, where she was put on rituximab^R, cyclophosphamide^R and dexamethasone^R. After the fifth course of chemotherapy, the progression was favorable, with correction of the hematological disorders and regression of the tumor syndrome.

DISCUSSION

Gamma HCD has been described worldwide, with no apparent epidemiological profile. It mainly affects middle-aged patients. The median age at diagnosis is 68 years (42–77 years) [3–5]. Our patient, aged 58, fits well within this age range. Moreover, a slight female predominance has recently been observed.

The clinical expression of γ HCD is very heterogeneous, ranging from an indolent and asymptomatic state to rapidly progressive malignancy [6]. Chang and al. found lymphadenopathy in 66.7% of their patients and hepatomegaly and splenomegaly in 50% [4]. It is most often associated with hematological malignancies and autoimmune diseases. Its association with the latter often heralds a γ HCD of several years [5].

In fact, monoclonal gammopathies have an autoantibody activity, often directed against erythrocyte antigens, responsible for cold agglutinins and the formation of a mixed type II cryoglobulin [7]. This explains our patient's history of cold agglutinin disease.

The biological diagnosis of γ HCD relies on the identification of monoclonal gamma heavy chains without associated light chains in serum or urine. But this is not so easy and represents a challenge for the laboratory analyst.

The monoclonal peak appearing on the protein gel is essential for an accurate diagnosis of γ HCD. However, the appearance of the electrophoretic profile is not always normal and leads to a diagnostic impasse. In 20% of cases, no monoclonal peak is observed and in 60% of cases, the peak may migrate into the beta zone [3].

The diversity of the electrophoretic profile is linked to the capacity of capillary zone electrophoresis (CZE). Dynamic reading of the passage of proteins beyond the detection window does not exhaustively explore the migration of abnormal proteins, leaving a reconstructed electrophoregram [5]. In the case presented here, the monoclonal peak migrated into the beta-2 globulin zone. The presence of gamma isotope

heavy chain without light chain on immunofixation led to suspicion of the diagnosis, which was confirmed by immunosubtraction.

Recent cases have illustrated the difficulty of correctly identifying heavy chain disease by immunofixation. Light chain bands are sometimes not visible due to excess antigen, overdilution of serum or masking of the light chain epitope. In addition, monoclonal heavy chains often appear as broad bands and can be confused with polyclonal immunoglobulins, as was the case in our patient. For these reasons, another method is needed to confirm the diagnosis [8]. This explains why our patient underwent immunosubtraction.

In our patient, immunosubtraction allowed the diagnosis to be made by confirming the presence of gamma heavy chains not associated with the light chain, as in the case of Planté and al [9]. Recently, techniques such as Matrix-assisted laser desorption/ionization time-of-flight coupled with mass spectrometry (MALDI-TOF MS) help to overcome these difficulties. It enables direct detection of light and heavy chains and provides structural information on proteins, both of which are particularly important for correctly identifying monoclonal heavy chains [8, 9].

The pathological heterogeneity of γ HCD makes histological diagnosis difficult. The most frequent histopathological finding is a pleomorphic malignant lymphoplasmacytic proliferation of tissues [3]. Management is poorly codified. Treatment options depend on the clinical presentation and underlying neoplasm [4]. Takano and al. successfully treated a patient with γ HCD with rituximab^R in combination with standard chemotherapy [10]. Our patient was treated with rituximab^R, cyclophosphamide^R and dexamethasone^R.

At the 5th course of treatment, she showed a good evolution of the tumor syndrome and biological parameters. Of the 16 patients treated in the series by Dietlind and al, six achieved complete clinical remission, while in 10 the disease persisted, resulting in the deaths of five patients from disease-related complications [2].

CONCLUSION

Gamma heavy chain disease is a rare disorder. The observation we have presented reveals that its diagnosis is delicate and relies on several techniques, the implementation of which requires a well-coordinated approach, a well-trained biologist and a dialogue between the clinician and the biologist. We can assume that the rarity of this pathology is partly linked to its under-diagnosis.

ACKNOWLEDGMENTS AND FUNDING STATEMENT: Nil

CONFLICT OF INTEREST DISCLOSURE: The authors declare have no conflict of interest

DATA AVAILABILITY STATEMENT: The authors declare that the data provided in the case description are available

PUBLICATION ETHICS

The article is produced ethically and responsibly, with no fabrication or falsification of data, no plagiarism and no manipulation of images.

Ethics Approval Statement

The approval of the ethics committee is not required for this article, as the work is based on the patient's clinical dossier and anonymity is respected.

Patient Consent Statement: Patient consent is not required

BIBLIOGRAPHIC REFERENCES

1. Kaleta, E., Kyle, R., Clark, R., & Katzmann, J. (2014). Analysis of patients with γ -heavy chain disease by the heavy/light chain and free light chain assays. *Clinical Chemistry and Laboratory Medicine*, 52(5), 665-669.
2. Nivet, C., Deluche, L., & Carreiro, M. (2021). Gamma-type heavy chain disease associated with diffuse large B-cell lymphoma in a context of myelodysplasia. *The Journal of Internal Medicine*, 42 (5), 355-358.
3. Ria, R., Dammacco, F., & Vacca, A. (2018). Heavy-chain diseases and myeloma-associated Fanconi syndrome: an update. *Mediterranean Journal of Hematology and Infectious Diseases*, 10(1).
4. Chang, L., Zhou, D. B., & Cao, X. X. (2023). Gamma heavy chain disease: a retrospective analysis of 6 cases. *Orphanet Journal of Rare Diseases*, 18(1), 1-4.
5. Humeau, C., Monjanel, H., & Schellenberg, F. (2016, May). Discovery of a gamma heavy chain disease in a patient followed-up for a lymphoplasma cell proliferative disorder. In *Annales de Biologie Clinique* (Vol. 74, No. 3, pp. 338-340).
6. Singer, S., Efebera, Y., Bumma, N., Khan, A., Devarakonda, S., Chaudhry, M., ... & Rosko, A. E. (2020). Heavy lifting: Nomenclature and novel therapy for gamma heavy chain disease and other heavy chain disorders. *Clinical Lymphoma Myeloma and Leukemia*, 20(8), 493-498.
7. Beauvillain, C., Jeannin, P., Renier, G., & Chevaller, A. (2011). Monoclonal immunoglobulins: diagnostic methods in 2011. *French-speaking laboratory review*, 2011 (433), 55-62.
8. Thoren, K. L., Eveillard, M., Chan, P., Doddi, S., Cho, S., & Murata, K. (2020). Identification of gamma heavy chain disease using MALDI-TOF mass spectrometry. *Clinical biochemistry*, 77, 57-61.
9. Planté, P., Hochart, A. C., & Gressier, B. (2022). Biological difficulties of a heavy chains disease diagnosis. *Ann Biol Clin (Paris)*. Févr, 80(1), 75-9.