

Case Report

Thyroid Localization of Breast Cancer: About a Case and Literature Review

Radia Benyahia^{1*}, Fathi Abada², Imene, Salah Eddine Bendib¹¹Department of Medical Imaging, Pierre and Marie Curie Center, University of Algiers 1, Algeria²Department of Cytology, Pierre and Marie Curie Center, University of Algiers 1, Algeria**Article History**

Received: 11.12.2023

Accepted: 06.01.2024

Published: 09.01.2024

Journal homepage:<https://www.easpublisher.com>**Quick Response Code**

Abstract: Introduction: Thyroid localization of breast cancer is rare and has a poor prognosis. Common metastatic sites of mammary carcinoma are pulmonary, hepatic and bone. Clinical diagnosis of thyroid metastasis from malignancy is difficult. We report a case of thyroid metastasis of mammary origin. We then discuss the diagnostic methods and their peculiarities in the identification of such lesions. **Observation:** This was a 47-year-old patient who underwent a left mastectomy with ipsilateral axillary lymph node dissection in 2014 and was presented 9 years later following the onset of a thyroid mass and right spinal lymphadenopathy. Cervical imaging revealed cervical lymphadenopathy of spinal site and nodular goiter classified as EU-TIRADS 4. A cytopuncture of the cervical lymphadenopathy and thyroid nodule is performed. Cytology revealed thyroid metastasis from mammary carcinoma and metastatic cervical lymphadenopathy. The patient underwent surgery (total thyroidectomy) confirming the diagnosis. **Conclusion:** The diagnosis of thyroid metastasis should be suspected in patients with a history of neoplasia prior to nodular goiter. The treatment for these metastases is that of primary cancer.

Keywords: Thyroid, metastases, diagnosis, ultrasound, cytopuncture, Anatomical pathology.

Copyright © 2024 The Author(s): This is an open-access article distributed under the terms of the Creative Commons Attribution **4.0 International License (CC BY-NC 4.0)** which permits unrestricted use, distribution, and reproduction in any medium for non-commercial use provided the original author and source are credited.

INTRODUCTION

The thyroid gland is rarely the site of metastases, accounting for less than 1% of all thyroid cancers. This rarity is actually related to the high iodine content. The clinical and radiological features of intrathyroid metastasis are non-specific. They can be indicative of primary or secondary cancer of neoplasia [1]. The origin of primary cancer is variable; the kidney, the lungs, the stomach, and the breast, it is more rarely described in the literature [2]. Questioning is of paramount importance in the search for neoplastic history.

OBSERVATION

This was a 47-year-old patient who was consulting for the management of a right basilobar nodular swelling of the thyroid that had been evolving for one year and also had the onset of right spinal cervical lymphadenopathy. In her history, she had had a left mastectomy and an ipsilateral axillary lymph node dissection 9 years earlier. Histological analysis concluded that SBR grade II invasive ductal carcinoma,

healthy BDR, ER 5, PR 6, HER 2 to 1, axillary dissection 02 N +/13 was positive. The patient received 6 courses of adjuvant type 3 Fac/3TXT chemotherapy and radiotherapy and hormone therapy. During his supervision, the follow-up was simple, with no local and remote recurrences. During the year 2021/2022, the patient consults following the appearance of cervical swelling, right basilobar swelling and palpation of a right spinal site nodule.

Clinical examination of the thyroid noted a hard right lobe nodule with no evidence of local compression associated with cervical lymph nodes. Ultrasound showed a homogeneous hypoechoic right thyroid nodule, with regular contours, without peripheral halos and microcalcifications with mixed Doppler vascularization, classified as EU-TIRADS 4 (Figure 1). Ipsilateral spinal lymphadenopathy was noted. Thyroid hormone status was normal. Cytology was performed on the thyroid and spinal nodule, which returned in favor of the right basilobar nodule, of a smear of rich cellularity, suggesting a secondary localization (Figure 2) of carcinoma, and for that of the right spinal cervical

*Corresponding Author: Radia Benyahia

Department of Medical Imaging, Pierre and Marie Curie Center, University of Algiers 1, Algeria

lymphadenopathy, in favor of a lymph node metastasis of a carcinoma. The patient underwent a total thyroidectomy and lymph node dissection. The histopathological study of the surgical specimen revealed

a secondary thyroid localization of a weakly differentiated carcinoma whose immunohistochemical profile argues in favor of the mammary origin (OR at 90%, PR at 10% and HER 2 at 0).

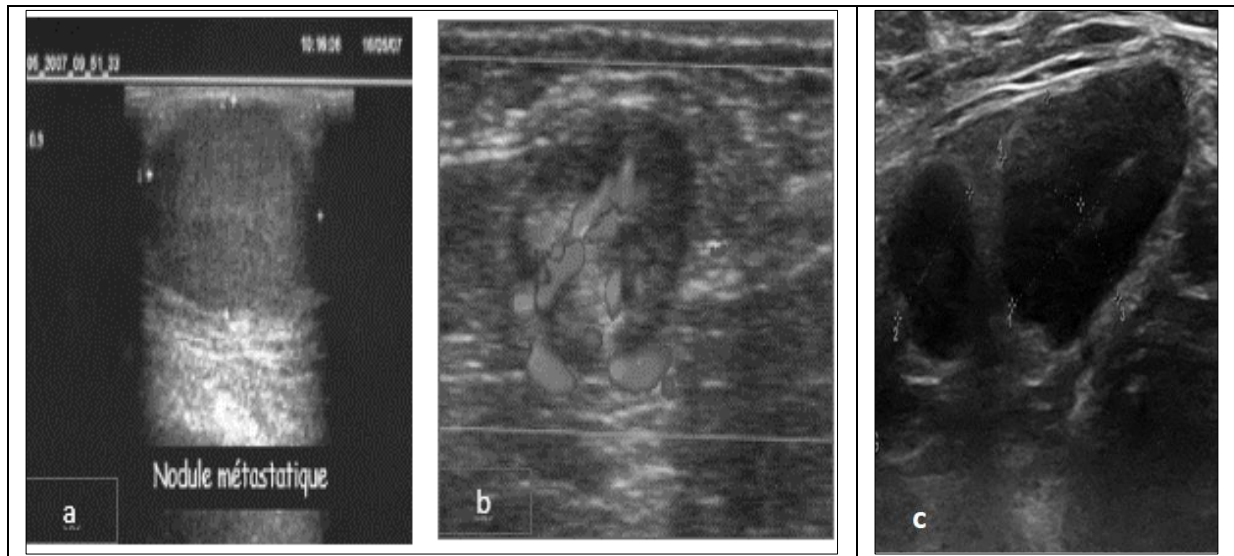


Figure 1: Ultrasound image

- a. The right nodule is very hypoechoic and has sharp and regular contours**
- b. Central and peripheral mixed vascularization on Doppler**
- c. Metastatic spinal lymphadenopathy, hypoechoic, eccentric thick cortex**

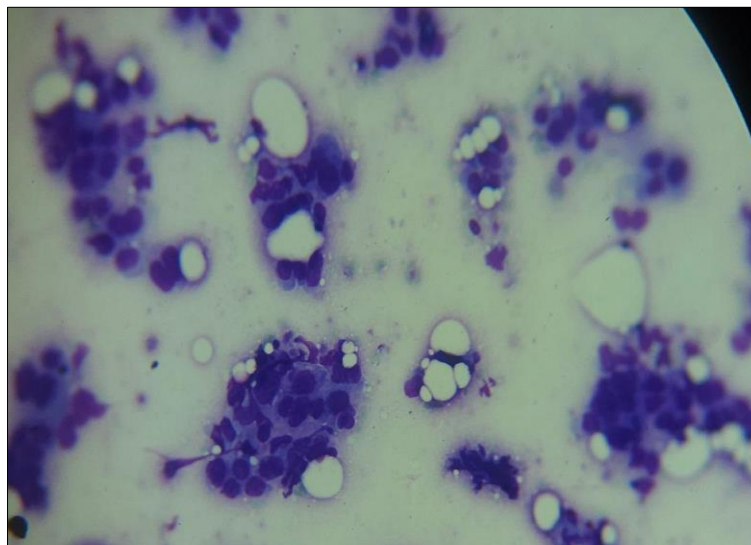


Figure 2: Cytology images: Microscopic appearance of thyroid metastasis from breast cancer

DISCUSSION

The frequency of intrathyroid metastases is estimated to be between 1 and 4% of all neoplastic thyroid disorders [2]. Intrathyroid metastases are rarely observed in clinical practice.

Ultrasound is not specific. It may find localized hypoechoic lesions, single or multiple, sometimes calcified, unilateral or bilateral more or less suspicious, or a hyperechoic appearance related to an inflammatory or necrotic reorganization, however all authors agree on the imperfect sensitivity of imaging in the diagnosis of

intrathyroid metastases [3-6]. Thyroid laboratory work-up is usually normal, but rare cases of hyperthyroidism have been reported [7].

Cytology examination at low sensitivity outside of a neoplastic context with a very high specificity exceeding 90% in the literature [4]. An immunohistochemical (IHC) study of the operative specimen is required and may strongly point to the primary tumor [8]. The IHC will provide proof of the diagnosis and identify the primary tumor even if it was occult.

CONCLUSION

The diagnosis of intrathyroid metastasis should always be considered in the presence of a thyroid nodule of suspicious ultrasound semiology, especially in the presence of a history of cancer. This investigation must be completed by a cytopuncture and by the performance of a precise and complete local and remote extension assessment.

Declaration of Ties of Interest: The authors declare that they have no ties of interest.

Authors' Contribution: All authors contributed to the writing of this manuscript and read and approved the final version.

REFERENCES

1. Chung, S. Y., Kim, E. K., Kim, J. H., Oh, K. K., Kim, D. J., Lee, Y. H., ... & Kim, J. S. (2001). Sonographic findings of metastatic disease to the thyroid. *Yonsei medical journal*, 42(4), 411-417.
2. Nakhjavani, M. K., Gharib, H., Goellner, J. R., & Heerden, J. A. V. (1997). Metastasis to the thyroid gland: a report of 43 cases. *Cancer: Interdisciplinary International Journal of the American Cancer Society*, 79(3), 574-578.
3. Buła, G., Waler, J., Niemiec, A., Koziołek, H., Bichalski, W., & Gawrychowski, J. (2010). Diagnosis of metastatic tumours to the thyroid gland by fine needle aspiration biopsy. *Endokrynologia Polska*, 61(5), 427-429.
4. Ferrozzi, F., Campodonico, F., De Chiara, F., Uccelli, M., & Saccani, A. (1997). Thyroid metastases: the echographic and computed tomographic aspects. *La Radiologia medica*, 94(3), 214-219.
5. Takashima, S., Takayama, F., Wang, J. C., Saito, A., Kawakami, S., Kobayashi, S., & Sone, S. (2000). Radiologic assessment of metastases to the thyroid gland. *Journal of computer assisted tomography*, 24(4), 539-545.
6. Medas, F., Calò, P. G., Lai, M. L., Tuveri, M., Pisano, G., & Nicolosi, A. (2013). Renal cell carcinoma metastasis to thyroid tumor: a case report and review of the literature. *Journal of medical case reports*, 7, 1-5.
7. Rodier, JF, Tuech, JJ, Wilt, M., Lindas, P., & Bruant-Rodier, C. (2008, September). Locally advanced intrathyroidal metastasis of bronchial cancer. In *Annals of Otolaryngology and Head and Neck Surgery* (Vol. 125, No. 4, pp. 198-203). Elsevier Masson.
8. Valo, I., Verrièle, V., Giraud, P., Lorimier, G., Guyété, S., & Sommelet, D. (2004, June). Thyroid metastases from an adrenocorticaloma 41 years after diagnosis of the initial tumor. In *Annals of Pathology* (Vol. 24, No. 3, pp. 264-267). Elsevier Masson.

Cite This Article: Radia Benyahia, Fathi Abada, Imene, Salah Eddine Bendib (2024). Thyroid Localization of Breast Cancer: About a Case and Literature Review. *EAS J Radiol Imaging Technol*, 6(1), 1-3.
