

Original Research Article

Incidents of Complications after Reconstruction of Neglected Achilles Tendon Injury by Baker's Procedure

Dr. Mohammad Sabbir Hossain^{1*}, Prof. Dr. Muhammad Shahiduzzaman², Dr. Md. Shahadat Hossain³, Dr. Mohammad Anisur Rahman⁴

¹Associate Professor, Department of Orthopaedics, Chandpur Medical College, Chandpur, Bangladesh

²Former Head, Department of Orthopaedics, Dhaka Medical College & Hospital, Dhaka, Bangladesh

³Senior consultant, Department of Orthopaedics, 250 Bed General Hospital, Chandpur, Bangladesh

⁴Senior Consultant, Department of Orthopaedics, 250 Bed General Hospital, Chandpur, Bangladesh

Article History

Received: 09.12.2023

Accepted: 17.01.2024

Published: 18.01.2024

Journal homepage:

<https://www.easpublisher.com>

Quick Response Code



Abstract: Introduction: Neglected Achilles tendon ruptures present a significant challenge in orthopedic surgery, with varied outcomes and complications. This study aims to evaluate the effectiveness of Baker's Procedure in the reconstruction of neglected Achilles tendon ruptures and to analyze the associated postoperative outcomes and complications. **Methods:** This prospective interventional study was conducted from January 1, 2012, to May 31, 2013, at multiple centers in Dhaka, Bangladesh. It included 42 patients aged 18 to 60 years with neglected Tendo-Achilles ruptures, defined as injuries untreated for over 4 weeks. Baker's Procedure, involving gastrocnemius aponeurosis advancement, was employed for reconstruction. **Result:** Of the 42 participants, 71.43% were male, with a mean age of 30.7 years. Injuries predominantly occurred in the right Achilles tendon (57.14%) and were mainly caused by sharp-metal objects (57.14%) and toilet-pan accidents (35.71%). Postoperative complications included stitch or wound infections (21.43%), pain (14.29%), stiffness (28.57%), and calf-muscle weakness (35.71%). Excellent, good, and fair outcomes were achieved in 64.29%, 21.43%, and 14.29% of patients, respectively. **Conclusion:** Baker's Procedure is effective in reconstructing neglected Achilles tendon ruptures, with a majority of patients achieving excellent or good outcomes. However, the relatively high rate of postoperative complications, particularly infections, calf muscle weakness and stiffness, highlights the need for improved surgical and postoperative strategies. These findings underscore the importance of tailored.

Keywords: Achilles Tendon; Neglected Injuries; Reconstruction; Baker's Procedure; Postoperative Complications.

Copyright © 2024 The Author(s): This is an open-access article distributed under the terms of the Creative Commons Attribution **4.0 International License (CC BY-NC 4.0)** which permits unrestricted use, distribution, and reproduction in any medium for non-commercial use provided the original author and source are credited.

INTRODUCTION

Achilles tendon injuries, prevalent in both athletic and general populations, significantly impact individuals' quality of life and physical capabilities [1]. The Achilles tendon, integral to the human musculoskeletal system, facilitates crucial movements in walking, running, and jumping [2]. Its robustness notwithstanding, the Achilles tendon is susceptible to a spectrum of injuries, ranging from mild tendinitis to complete ruptures. These injuries are particularly common in sports, attributed to overuse or acute trauma, and their prevalence has been increasing in recent decades [3,4]. Neglected Achilles tendon injuries, which are not addressed promptly or adequately, pose a unique

set of challenges. They often lead to chronic conditions characterized by pain, decreased functionality, and impaired quality of life, necessitating complex and often innovative reconstruction procedures [5,6]. The historical trajectory of treating Achilles tendon injuries reflects a significant evolution, mirroring broader advancements in medical science and surgical techniques. Initial conservative approaches, emphasizing rest and immobilization, have gradually given way to more aggressive surgical interventions as understanding of tendon healing and biomechanics has deepened [7,8]. Among the various surgical techniques, Baker's procedure, involving the lengthening of the gastrocnemius-soleus complex, has been noted for its effectiveness in managing chronic Achilles tendon issues

*Corresponding Author: Dr. Mohammad Sabbir Hossain

Associate Professor, Department of Orthopaedics, Chandpur Medical College, Chandpur, Bangladesh

[9–11]. In the realm of Achilles tendon injury management, a significant gap in the literature pertains to understanding the complications associated with Baker's procedure, particularly in the context of neglected injuries. While surgical interventions for Achilles tendon injuries generally report high success rates, the specific outcomes and complication rates associated with Baker's procedure, a technique often employed for more complex or neglected cases, are less thoroughly documented [12]. This lack of detailed documentation presents a critical barrier to advancing clinical knowledge and improving patient outcomes. The increasing incidence of Achilles tendon injuries is a growing concern, with contributing factors including an aging population, rising obesity rates, and increased participation in sports activities [13]. However, there is a notable scarcity of detailed data regarding the incidence of neglected Achilles tendon injuries and the success rates of reconstruction surgeries, such as Baker's procedure. The expected contributions of this research extend beyond academic interest, offering practical insights that could shape future treatment protocols and enhance the quality of life for individuals suffering from these injuries. In conclusion, this research seeks to address the critical need for a deeper understanding of the long-term outcomes of surgical interventions for neglected Achilles tendon injuries. By exploring the efficacy and complications associated with Baker's procedure, this study aims to provide valuable insights that can guide clinical decision-making and improve patient outcomes in this challenging and evolving field of medicine.

METHODS

This prospective interventional study was conducted from January 1, 2012, to May 31, 2013, at Dhaka Medical College & Hospital, the National Institute of Traumatology and Orthopaedic Rehabilitation (NITOR), and selected private hospitals in Dhaka, Bangladesh. The study included 42 patients aged 18 to 60 years, presenting with neglected Tendo-Achilles ruptures, defined as injuries untreated for over 4 weeks. The age range was chosen to represent adults most affected by such injuries. Exclusion criteria were recent ruptures, concurrent injuries, fractures in the affected limb, and significant health conditions. The study aimed to evaluate the outcomes of reconstructing neglected Achilles tendons using Baker's Procedure, which involves gastrocnemius aponeurosis advancement in inverted U-fashion and resulting in end-to-end reconstruction [11]. This method was selected for its effectiveness in similar cases. Postoperative care included initial limb elevation, followed by a two-week immobilization in a long leg anterior plaster slab with specific knee and ankle flexion angles to optimize healing. This was succeeded by a long leg full plaster cast for four weeks, transitioning to a short leg full plaster with the ankle in a neutral position for another four weeks to reintroduce normal ankle positioning. After ten weeks, the plaster was removed, and patients used a 3-5 cm heel lift, gradually reduced weekly, to ease back into normal activity. Physiotherapy focused on quadriceps strengthening and joint mobility. Ethical approval was obtained, and data were analyzed using appropriate statistical methods to evaluate the efficacy of Baker's Procedure in treating neglected Achilles tendon ruptures.

RESULTS

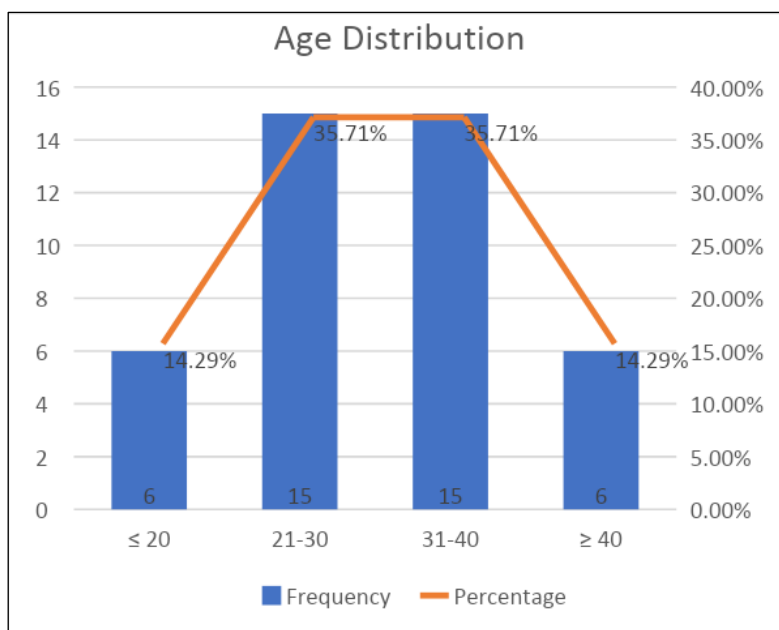


Figure 1: Age range distribution of participants (N=42)

In this study of 42 participants, the age distribution was as follows: 14.29% (n=6) were aged ≤ 20 years, 35.71% (n=15) each in the 21-30 and 31-40 year age groups, and 14.29% (n=6) were aged ≥ 40 years. The

average age of participants was 30.7 years with a standard deviation of 9.19 years, indicating a predominance of young adults in the study cohort.

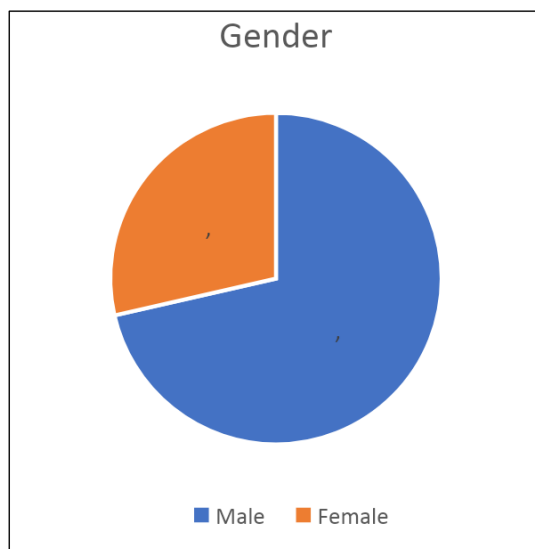


Figure 2: Gender distribution of the participants (N=42)

Of the 42 participants in the study, 71.43% (n=30) were male, and 28.57% (n=12) were female.

Table 1: Distribution of participants by interval between injury and operation (N=42)

Interval	Frequency	Percentage
≤ 6 weeks	15	35.71%
6-10 weeks	24	57.14%
≥ 10 weeks	3	7.14%
Mean \pm SD	7.5 \pm 1.99	

In the study, 35.71% (n=15) of participants underwent surgery within 6 weeks of injury, 57.14% (n=24) between 6-10 weeks, and 7.14% (n=3) after 10

weeks. The average interval from injury to operation was 7.5 weeks with a standard deviation of 1.99 weeks.

Table 2: Distribution of participants by injury related characteristics (N=42)

Variables	Frequency	Percentage
Side of Injury		
Right Achilles tendon	24	57.14%
Left Achilles tendon	18	42.86%
Cause of Injury		
Sharp-metal injury	24	57.14%
Toilet-pan injury	15	35.71%
Sports injury	3	7.14%
Presence of Palpable Gap		
Yes	30	71.43%
No	12	28.57%

In the study, 57.14% (n=24) of the injuries occurred in the right Achilles tendon, while 42.86% (n=18) were in the left. Regarding the cause of injury, 57.14% (n=24) were due to sharp-metal objects, 35.71%

(n=15) to toilet-pan accidents, and 7.14% (n=3) to sports injuries. A palpable gap was present in 71.43% (n=30) of the cases, while 28.57% (n=12) did not have a palpable gap.

Table 3: Distribution of participants by incidence of complications (N=42)

Variables	Frequency	Percentage
Pain		
No pain	36	85.71%
Mild pain	6	14.29%
Stiffness of affected ankle		
No stiffness	30	71.43%
Mild stiffness	12	28.57%
Calf- muscle weakness		
None	27	64.29%
Mild weakness	12	28.57%
Moderate weakness	3	7.14%
Footwear restrictions		
None	39	92.86%
Mild	3	7.14%
Active Range of Motion		
Normal ($\leq 5^\circ$)	27	64.29%
Mildly limited ($6^\circ - 10^\circ$)	15	35.71%
Stitch/Wound Infection		
Present	9	21.43%
Absent	33	78.57%
Power of planter flexion (according to MRC grading)		
MRC-5	24	57.14%
MRC-4	6	14.29%
MRC-3	12	28.57%

A majority, 85.71% (n=36), experienced no pain post-surgery, while a smaller fraction, 14.29% (n=6), reported mild pain. Regarding ankle stiffness, 71.43% (n=30) of the participants did not experience any stiffness, whereas 28.57% (n=12) had mild stiffness. Calf-muscle weakness was observed in varying degrees: 64.29% (n=27) reported no weakness, 28.57% (n=12) had mild weakness, and 7.14% (n=3) experienced moderate weakness. Footwear restrictions were minimal, with 92.86% (n=39) facing no restrictions and only 7.14% (n=3) having mild restrictions. In terms of active

range of motion, 64.29% (n=27) of participants maintained a normal range ($\leq 5^\circ$), while 35.71% (n=15) exhibited mildly limited motion ($6^\circ - 10^\circ$). The incidence of stitch or wound infections was noted in 21.43% (n=9) of the cases, contrasting with 78.57% (n=33) who did not encounter this complication. Finally, the power of planter flexion, assessed according to the Medical Research Council (MRC) grading, showed that 57.14% (n=24) achieved MRC-5, 14.29% (n=6) reached MRC-4, and 28.57% (n=12) were at MRC-3 level.

Table 4: Distribution of participants by final outcome (N=42)

Final Outcome	Frequency	Percentage
Excellent	27	64.29%
Good	9	21.43%
Fair	6	14.29%

In the study, the final outcomes for the 42 participants were as follows: 64.29% (n=27) had an excellent outcome, 21.43% (n=9) had a good outcome, and 14.29% (n=6) had a fair outcome.

DISCUSSION

The present study's findings on the surgical treatment of neglected Achilles tendon ruptures provide valuable insights into patient demographics, injury characteristics, complications, and outcomes. Our study

observed a higher incidence of injuries in the 21-40 age group (71.42%), aligning with the findings of Stavenuiter *et al.*, who noted that Achilles tendon ruptures are frequent in the adult population [14]. The predominance of males (71.43%) in our study is consistent with previous research, indicating a higher susceptibility of males to Achilles tendon injuries [15–17]. In terms of injury characteristics, the majority of our cases involved right Achilles tendon injuries (57.14%), which is interesting to note but not extensively covered in the literature. The causes of injury in our study were

predominantly sharp-metal objects (57.14%) and toilet-pan accidents (35.71%), which is a unique finding as most literature, including the study by Kunc *et al.*, focuses on sports-related injuries [18]. This difference could be attributed to regional or cultural factors affecting injury mechanisms. Our study observed a 21.43% incidence of postoperative stitch or wound infections, a figure that is notably higher than rates reported in other recent studies. For example, Rider *et al.*, emphasized the effectiveness of modern surgical techniques and aggressive infection control strategies in significantly reducing infection rates [15]. The discrepancy in infection rates could be attributed to various factors, including differences in the surgical environment, patient comorbidities, or postoperative care protocols. Additionally, a study by Stavenuiter *et al.*, identified advancing patient age and active tobacco use as risk factors for postoperative complications, including infections [14]. These factors might have contributed to the higher infection rate in our cohort. Furthermore, our findings on pain, stiffness, and calf-muscle weakness post-surgery align with the varied postoperative experiences reported in the literature. A study by Kunc *et al.*, noted that complications such as wound dehiscence and thrombosis are common after Achilles tendon rupture surgery [18]. These complications can potentially lead to longer recovery times and residual symptoms like stiffness and weakness. The presence of mild pain in 14.29% and mild stiffness in 28.57% of our patients suggests a need for enhanced postoperative rehabilitation protocols to mitigate these issues. In terms of functional recovery, the majority of our patients achieved a good level of active range of motion and planter flexion power, which is encouraging. This outcome is consistent with findings from Kalma *et al.*, who reported favorable functional outcomes following Achilles rupture repair, regardless of the time to surgery or surgical technique used [19]. Our study's focus on neglected injuries, however, adds a unique perspective to the existing literature, highlighting the challenges and potential for recovery in this specific patient group. The final outcomes in our study were predominantly excellent (64.29%), which is encouraging and comparable to the positive outcomes reported in other studies, such as the one by Kalma *et al.*, who also observed favorable results with different surgical techniques [19]. The similarity in successful outcomes across different studies underscores the effectiveness of surgical interventions for Achilles tendon ruptures, despite variations in techniques and patient populations. However, our study's incidents of complication calls for a critical evaluation of surgical practices, patient selection, and postoperative care. It suggests a need for further research into optimizing surgical techniques and patient management to minimize complications, as indicated by the studies of Stavenuiter *et al.*, and Rider *et al.*, [14,15]. Additionally, the unique injury causes observed in our study population highlight the importance of considering regional and cultural factors in injury prevention strategies. In conclusion, our study

contributes to the existing literature by providing insights into neglected Achilles tendon ruptures in a specific demographic and regional context. The similarities and differences observed in comparison with other studies emphasize the need for continuous evaluation and adaptation of surgical and postoperative practices to enhance patient outcomes and reduce complications.

Limitations of The Study

The study was conducted in a few hospitals with a small sample size. So, the results may not represent the whole community.

CONCLUSION

In conclusion, this study offers significant insights into the surgical management of neglected Achilles tendon ruptures. Our findings indicate a higher incidence of these injuries in young adult males, predominantly caused by non-sport-related accidents. The postoperative complication rate, particularly concerning stitch or wound infections, pain, stiffness, and calf-muscle weakness, underscores the need for enhanced surgical techniques and postoperative care protocols. Despite these challenges, the majority of patients achieved excellent or good outcomes, demonstrating the effectiveness of Baker's Procedure. These results contribute to the growing body of evidence supporting surgical intervention in such cases, while also emphasizing the importance of tailored approaches considering patient-specific factors and regional injury patterns. Future research should focus on optimizing surgical methods and postoperative care to further improve patient outcomes and minimize complications.

Funding: No funding sources

Conflict of interest: None declared

Ethical approval: The study was approved by the Institutional Ethics Committee

REFERENCES

1. Egger, A. C., & Berkowitz, M. J. (2017). Achilles tendon injuries. *Curr Rev Musculoskelet Med* 10: 72–80.
2. Benjamin, M., Theobald, P., Suzuki, D., & Toumi, H. (2007). The anatomy of the Achilles tendon. *The Achilles Tendon*, 3, 5-16.
3. Kvist, M. (1994). Achilles tendon injuries in athletes. *Sports Med*;18(3):173–201.
4. Aicale, R., Tarantino, D., & Maffulli, N. (2018). Overuse injuries in sport: a comprehensive overview. *Journal of orthopaedic surgery and research*, 13(1), 1-11.
5. Gatz, M., Spang, C., & Alfredson, H. (2020). Partial Achilles tendon rupture—a neglected entity: a narrative literature review on diagnostics and treatment options. *Journal of Clinical Medicine*, 9(10), 3380.

6. Ashton-Miller, J. A. (1999, April). Response of muscle and tendon to injury and overuse. In *Work-related Musculoskeletal Disorders: Report, Workshop Summary, and Workshop Papers, National Research Council* (pp. 73-97).
7. Zhao, J. G., Meng, X. H., Liu, L., Zeng, X. T., & Kan, S. L. (2017). Early functional rehabilitation versus traditional immobilization for surgical Achilles tendon repair after acute rupture: a systematic review of overlapping meta-analyses. *Scientific reports*, 7(1), 39871.
8. Utashima, D., Matsumura, N., Suzuki, T., Iwamoto, T., Ogawa, K., Park, D., ... & Seo, S. G. (2020). Treatment of acute Achilles tendon rupture. *Clinics in Orthopedic Surgery*, 12(1), 1-8.
9. Ackermann, P. W., Phisitkul, P., & Pearce, C. J. (2018). Treatment of Achilles tendinopathy: state of the art. *Journal of ISAKOS*, 3(6), 367-376.
10. Fanter, N. J., Davis, E. W., & Baker Jr, C. L. (2012). Fixation of the Achilles tendon insertion using suture button technology. *The American Journal of Sports Medicine*, 40(9), 2085-2091.
11. Baker, L. D. (1956). A rational approach to the surgical needs of the cerebral palsy patient. *JBJS*, 38(2), 313-323.
12. Roebke, L. J., Alvarez, P. M., Curatolo, C., Palumbo, R., & Martin, K. D. (2024). Chronic Achilles Tendon Avulsion Repair: Central Third Fascia Slide Technique with Flexor Hallucis Longus Transfer. *JBJS Essential Surgical Techniques*, 14(1), e22.
13. Fain, A. M., Vlasov, A. P., Akimov, R. N., Kisel, D. A., Lazarev, M. P., Miguleva, I. Y., & Svetlov, K. V. (2023). Achilles Tendon Injury Treatment: the History and Current State of the Art. *Russian Sklifosovsky Journal" Emergency Medical Care"*, 11(4), 655-667.
14. Stavenuiter, X. R., Lubberts, B., Prince III, R. M., Johnson, A. H., DiGiovanni, C. W., & Guss, D. (2019). Postoperative complications following repair of acute Achilles tendon rupture. *Foot & Ankle International*, 40(6), 679-686.
15. Rider, C. M., Hansen, O. B., & Drakos, M. C. (2022). Clinical Management and Functional Outcomes of Postoperative Achilles Tendon Infections: How Do These Really Do?. *Foot & Ankle Orthopaedics*, 7(1), 2473011421S00411.
16. Pardes, A. M., Freedman, B. R., Fryhofer, G. W., Salka, N. S., Bhatt, P. R., & Soslowky, L. J. (2016). Males have inferior Achilles tendon material properties compared to females in a rodent model. *Annals of biomedical engineering*, 44, 2901-2910.
17. Intziegianni, K., Cassel, M., Hain, G., & Mayer, F. (2017). Gender differences of Achilles tendon cross-sectional area during loading. *Sports Medicine International Open*, 1(04), E135-E140.
18. Kunc, V., Edelmann, K., Bába, V., Debnar, M., Kmet', P., Kučera, K., ... & Kopp, L. (2021). Retrospective analysis of complications after treatment of acute Achilles tendon rupture by Kessler technique. *Rozhledy v Chirurgii: Mesicnik Ceskoslovenske Chirurgicke Spolecnosti*, 100(8), 384-389.
19. Kalma, J. J., Hewitt, M. A., Buckley, S. E., Drexelius, K. D., Moon, D. K., Metzl, J. A., ... & Hunt, K. J. (2022). Time to Surgery and Technique as Predictors of Complications after Surgical Treatment of Achilles Ruptures: A Retrospective Study. *Foot & Ankle Orthopaedics*, 7(4), 2473011421S00714.

Citation: Mohammad Sabbir Hossain, Muhammad Shahiduzzaman, Md. Shahadat Hossain, Mohammad Anisur Rahman (2024). Incidents of Complications after Reconstruction of Neglected Achilles Tendon Injury by Baker's Procedure. *EAS J Orthop Physiother*, 6(1): 1-6.
