

Case Report

Pancoast-Tobias Syndrome Due to a High-Grade Fibrous Histiocytoma: A Case Report

Joshua Tambe^{1,2*}, Yannick Onana³, Sylviane Dongmo¹, Vanessa Tongue⁴, Boniface Moifo⁵¹Division of Radiology, Faculty of Health Sciences, University of Buea, Cameroon²Medical Imaging Center, Limbe Regional Hospital, Cameroon³Department of Radiology, Faculty of Medicine and Biomedical Sciences, University of Garoua, Cameroon⁴Faculty of Medicine and Pharmaceutical Sciences, University of Douala, Cameroon⁵Department of Medical Imaging & Radiation Oncology, Faculty of Medicine and Biomedical Sciences, The University of Yaoundé 1, Cameroon**Article History**

Received: 08.03.2024

Accepted: 16.04.2024

Published: 18.04.2024

Journal homepage:<https://www.easpublisher.com>**Quick Response Code**

Abstract: Bronchogenic cancers account for an overwhelming majority of all malignancies responsible for Pancoast syndrome. However, the spectrum of non-bronchogenic malignant causes is broad and although less frequent, they are characterized by late diagnosis at advanced disease stage with a poor prognosis. The clinical presentation of Pancoast tumors can be polymorphic based on the etiology and anatomic extent, leading to considerable delays in the request of appropriate investigative techniques. Chest radiography may be helpful in first-line imaging but the cross-sectional modalities are more sensitive for diagnosis, staging and follow-up of treatment. Early reporting of symptoms and increased clinical vigilance could lead to an early diagnosis and improved 5-year survival. We report the case of a 40-year-old male with worsening left shoulder and arm pain over the course of a few months and a left neck swelling.

Keywords: Pancoast syndrome, non-bronchogenic tumor.

Copyright © 2024 The Author(s): This is an open-access article distributed under the terms of the Creative Commons Attribution **4.0 International License (CC BY-NC 4.0)** which permits unrestricted use, distribution, and reproduction in any medium for non-commercial use provided the original author and source are credited.

INTRODUCTION

Pancoast-Tobias syndrome is the association of the triad shoulder or arm pain along C8 to T2 nerve roots of the brachial plexus, ipsilateral amyotrophy of the hand and Horner's syndrome. The clinical presentation can be atypical and polymorphic depending on the etiology, the anatomic location and extent of spread (Sellami *et al.*, 2017). Pancoast-Tobias syndrome, or Pancoast syndrome, is often due to apical malignant tumors most of which are bronchogenic (Saidi *et al.*, 2021). Nevertheless, benign causes have also been reported in the literature and include pulmonary tuberculosis, aspergillosis and histoplasmosis (Das *et al.*, 2014; Samaraj & Vijay Gowri Shankar, 2019).

For the malignant causes of Pancoast-Tobias syndrome, initial diagnosis is often made at an advanced stage of disease (Ginsberg *et al.*, 1994). This is partly due to the spectrum of clinical findings that might not be suspecting and therefore lead to delays in investigation (Jabli *et al.*, 2018; Saidi *et al.*, 2021). Late diagnosis at

advanced disease stage is synonymous to poor prognosis for many malignancies. We report a case of Pancoast syndrome in a young adult male with a neck mass evolving slowly over time and later diagnosed to be a malignant non-bronchogenic tumor.

CASE DESCRIPTION

A 40-year-old man presented to the Radiology Department of a university-affiliated hospital in the South-West Region of Cameroon for a chest radiograph following complaints of left shoulder pain radiating to the arm, associated with paresthesia. A posterior-anterior chest radiograph (Figure 1) showed a left apical opacity (mass) with a circumscribed and convex lower border and a superior aspect obscured by the soft tissues of the neck. With lytic bone destruction of the left first rib and partial lysis of T1 vertebra, a malignant apical tumor mass was suspected. The patient, still at the department awaiting the results got an invitation for a clinical review by the reporting clinical radiologist (corresponding author).

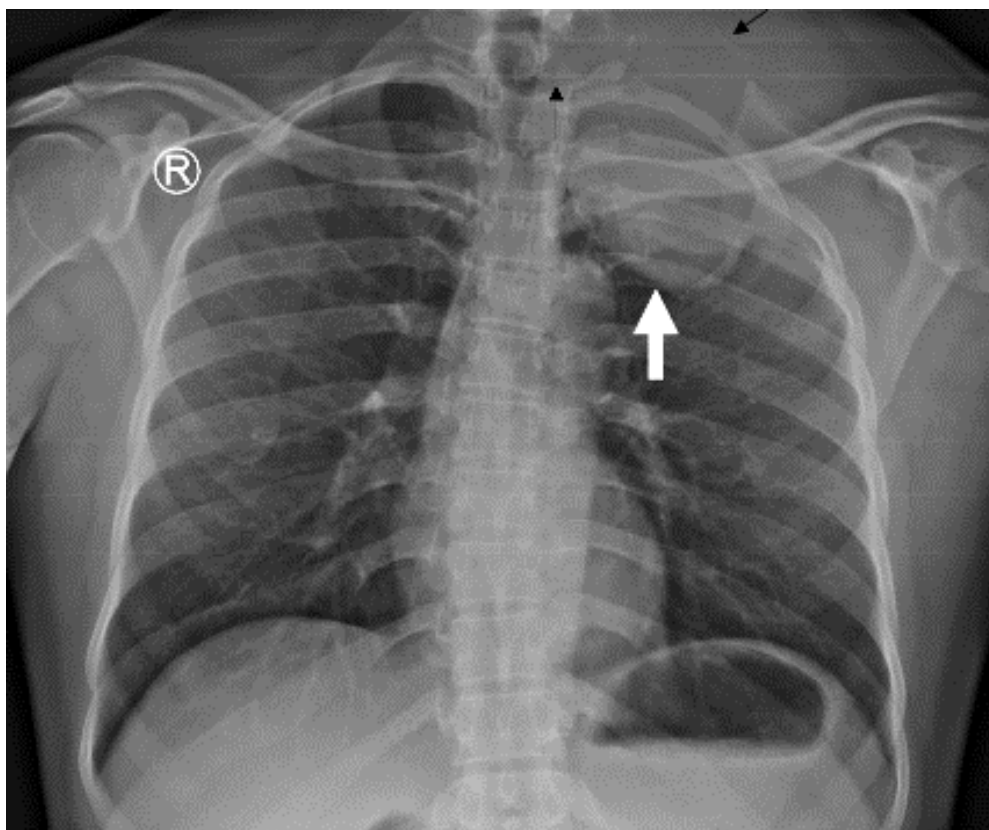


Figure 1: Chest radiograph (Posterior-anterior projection). Opacity of soft tissue density at the left apex with a circumscribed convex lower border (white arrow) and a superior aspect obscured by the soft tissues of the neck (black arrow). There is lysis of the left first rib and the left aspect of T1 vertebral body (black arrowhead)

According to his narrative, he had been feeling some numbness over the left upper limb radiating to the hands, associated with pain that had gradually intensified over a couple of months. He reportedly could no longer work effectively or hold objects with his left hand owing to the pain. Treatment was symptomatic with over-the-counter analgesics and anti-inflammatory medications. After noticing a slight swelling at the left supra-clavicular region, he decided to consult with a general practitioner. He did not report any significant medical history, did not smoke and consumed alcohol occasionally. Physical examination confirmed mild left supra-clavicular swelling and an indolent palpable mass. There was ptosis of the left upper eyelid, but no miosis or amyotrophy. The patient had not taken note of any left unilateral anhidria.

The reporting radiologist recommended a contrast-enhanced computed tomography (CT) scan of the neck and chest. CT was performed two weeks later as the patient had to put together the financial resources necessary to pay for the services. A 16-slice CT scanner was used (HITACHI Supria®) with volumetric multiphase data acquisition. Intravenous iodinated contrast material was administered (Xenetix 300®, 80ml) and post-processing techniques included multiplanar

reformatting and the use of multiple window settings. CT scan showed a circumscribed and heterogeneous mass of soft tissue density, extending from the left supra-clavicular region to the apex with encasement of the left subclavian artery. There was a vast hypodense area suggestive of necrosis, prominent blood vessels within the mass and no contrast enhancement (Figure 2). CT further confirmed lysis of the left first rib and part of C7 and T1 vertebral bodies (Figure 3). No enlarged cervical, axillary or mediastinal lymph node was depicted. Given these initial findings, a portal phase of the abdomen and pelvis was included and the findings were unremarkable.

A full blood count was normal and blood biochemistry was unremarkable. Transcutaneous biopsy of the mass was performed and histopathology analysis reported a high-grade fibrous histiocytoma (histology slides were not accessible to the authors). Based on imaging, this tumor was classified as a T4 lesion. The patient was referred to a tertiary health facility for specialized care. He was called up three months later by one of the authors (JT) and he admitted having received radiotherapy sessions. A contrast-enhanced chest CT scan obtained six months later at the request and expense of this author showed identical findings to the initial diagnostic scan.

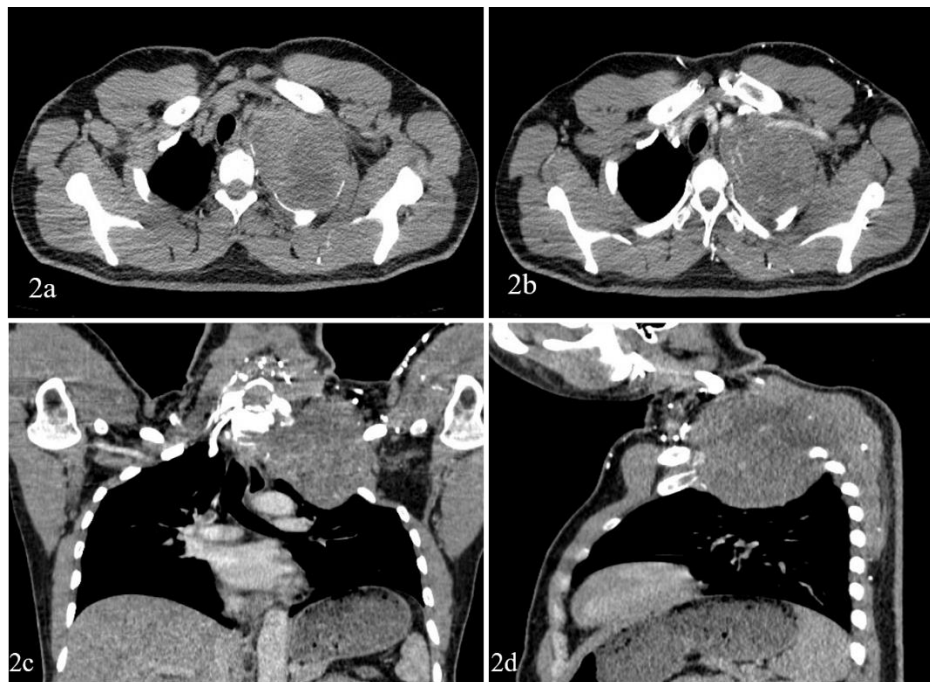

Figure 2: Chest CT. Unenhanced axial section (2a) showing a left apical heterogeneous soft tissue mass with hypodense areas within. There is lytic destruction and thinning of the first rib which outlines the mass posteriorly and laterally. The contrast-enhanced axial section (2b) shows prominent blood vessels within the mass and partial encasement of the subclavian vein. The coronal (2c) and parasagittal (2d) reformatted contrast-enhanced images illustrate the anatomical relationships of the mass

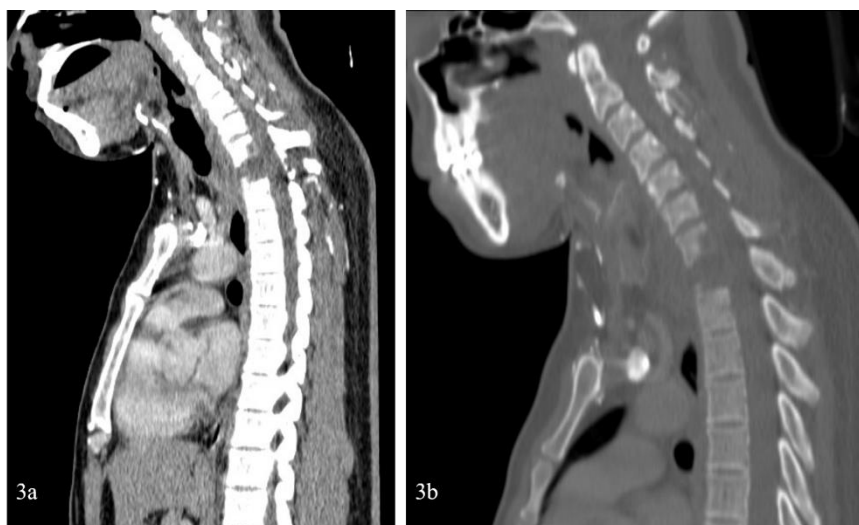

Figure 3: Midsagittal reformats of the contrast-enhanced series illustrate partial lysis of C7 and T1 vertebral bodies

DISCUSSION

Bronchogenic tumors account for up to 95% of all malignancies that produce a Pancoast syndrome (Munir *et al.*, 2021). Non-bronchogenic malignant causes are less frequent, however, with an overall poor prognosis if diagnosis is late and at an advanced stage of disease as is frequently the case (Saidi *et al.*, 2021). The primary malignant non-bronchogenic causes of Pancoast syndrome reported in the literature is a broad spectrum comprising of both solid and hematological malignancies. Some solid malignancies reported include

myxofibrosarcoma, adenoid cystic carcinoma, carcinoid, hemangiopericytoma, and mesothelioma (Jevremovic *et al.*, 2017). Hematologic malignancies include plasmacytoma (Chen & Padmanabhan, 1983), non-Hodgkin lymphoma (Mills *et al.*, 1994), and lymphomatoid granulomatosis (Dolan *et al.*, 1991). Metastatic lesions are also a documented etiology of Pancoast syndrome and include tumors from the lungs, larynx, thyroid, urinary bladder and cervix (Rabano *et al.*, 1991).

Pancoast syndrome due to bronchogenic malignancies is usually reported in male patients between 53 and 70 years of age with a history of active tobacco consumption (Jabli *et al.*, 2018; Munir *et al.*, 2021). Owing to the heterogeneous etiology of non-bronchogenic primary malignancies at the origin of a Pancoast syndrome, the risk factors, clinical presentation, management and prognosis are polymorphic and depend on the specific malignancy in question. For the case we report, the diagnosis was a malignant fibrous histiocytoma, also known as undifferentiated pleomorphic sarcoma. This tumor is reportedly the most common soft tissue sarcoma that usually occurs in late adult life and mostly in males (Weiss & Enzinger, 1978). Treatment is with neoadjuvant/adjuvant radiotherapy and 5-year survival can be as high as 66% (Toy & Heck Jr, 2021). However, indicators of poor prognosis include high grade, large size, deep location and the presence of metastases (Toy & Heck Jr, 2021).

More than 50% of patients with Pancoast-Tobias syndrome present with tumor masses considered unresectable at the time of diagnosis (Panagopoulos *et al.*, 2014). This is due to vertebral involvement, lymph node invasion at the mediastinum and distant tumor spread. Our patient had lysis of at least one rib and two vertebral bodies at the time of diagnosis corresponding to stage T4 disease with encasement of the subclavian vein. Stage T4 is reportedly predictive of a poor outcome. Five-year survival of patients with stage T4 disease was reportedly less than 10% by Ginsberg *et al.*, (Ginsberg *et al.*, 1994), at 13% by Rusch *et al.*, (Rusch *et al.*, 2000) and 30% by Darteville *et al.*, (Darteville *et al.*, 1993). Subclavian vessel involvement was reported to be a negative prognostic factor (Darteville *et al.*, 1993). CT did not show any enlarged lymph node, and nodal involvement has a prognostic value. Despite the negative CT for nodal disease, the more sensitive mediastinoscopy and positron-emission tomography were not available. Routine workup also proved to be a challenge for the patient who had to pay out-of-pocket for needed services.

CONCLUSION

Pancoast-Tobias syndrome is a clinical entity with variations in the presentation. Mostly due to apical lung cancers, other non-bronchopulmonary tumors have been reported. Increased clinical vigilance would be beneficial as late diagnosis with advanced disease is frequent and associated to an overall poor prognosis. The lack of resources to pursue further investigations and treatment in resource-poor settings can further compromise the prognosis.

Conflicts of interest: The authors declare that they have no conflict of interest.

Funding statement: None received

Acknowledgement: The authors heartily thank the patient for providing all relevant information.

REFERENCES

- Chen, K. T. K., & Padmanabhan, A. (1983). Pancoast syndrome caused by extramedullary plasmacytoma. *Journal of Surgical Oncology*, 24(2), 117–118. <https://doi.org/10.1002/jso.2930240210>
- Darteville, P. G., Chapelier, A. R., Macchiarini, P., Lenot, B., Cerrina, J., Ladurie, F. L., Parquin, F. J., & Lafont, D. (1993). Anterior transcervical-thoracic approach for radical resection of lung tumors invading the thoracic inlet. *J Thorac Cardiovasc Surg*, 105(6), 1025–1034.
- Das, A., Choudhury, S., Basuthakur, S., Das, S. K., & Mukhopadhyay, A. (2014). Pancoast's Syndrome due to Fungal Abscess in the Apex of Lung in an Immunocompetent Individual: A Case Report and Review of the Literature. *Case Reports in Pulmonology*, 2014, 1–4. <https://doi.org/10.1155/2014/581876>
- Dolan, G., Smith, J., & Reilly, J. T. (1991). Extrapulmonary lymphomatoid granulomatosis presenting as Pancoast's syndrome. *Postgraduate Medical Journal*, 67(792), 914–915. <https://doi.org/10.1136/pgmj.67.792.914>
- Ginsberg, R. J., Martini, N., Zaman, M., Armstrong, J. G., Bains, M. S., Burt, M. E., McCormack, P. M., Rusch, V. W., & Harrison, L. B. (1994). Influence of surgical resection and brachytherapy in the management of superior sulcus tumor. *The Annals of Thoracic Surgery*, 57(6), 1440–1445. [https://doi.org/10.1016/0003-4975\(94\)90098-1](https://doi.org/10.1016/0003-4975(94)90098-1)
- Jabli, S., Gargouri, I., Knaz, A., Aissa, S., Ben Khelifa, M., Abdelghani, A., Garrouch, A., Hayouni, A., & Benzarti, M. (2018). Les tumeurs de Pancoast Tobias : étude pronostique et particularités de prise en charge : à propos de 39 cas. *Revue Des Maladies Respiratoires*, 35, A206–A207. <https://doi.org/10.1016/j.rmr.2017.10.471>
- Jevremovic, V., Yousuf, A., Hussain, Z., Abboud, A., & Chedrawy, E. G. (2017). A rare presentation of myxofibrosarcoma as a Pancoast tumor: a case report. *Journal of Medical Case Reports*, 11(1), 61. <https://doi.org/10.1186/s13256-017-1223-5>
- Mills, P. R., Han, L. Y., Dick, R., & Clarke, S. W. (1994). Pancoast syndrome caused by a high grade B cell lymphoma. *Thorax*, 49(1), 92–93. <https://doi.org/10.1136/thx.49.1.92>
- Munir, M., Jamil, S. Bin, Rehmani, S., & Borz-Baba, C. (2021). Pancoast-Tobias Syndrome: A Unique Presentation of Lung Cancer. *Cureus*, 13(2), e13112. <https://doi.org/10.7759/cureus.13112>
- Panagopoulos, N., Leivaditis, V., Koletsis, E., Prokakis, C., Alexopoulos, P., Baltayiannis, N., Hatzimichalis, A., Tsakiridis, K., Zarogoulidis, P., Zarogoulidis, K., Katsikogiannis, N., Kougioumtzi, I., Machairiotis, N., Tsiouda, T., Kesisis, G.,

- Siminelakis, S., Madesis, A., & Dougenis, D. (2014). Pancoast tumors: characteristics and preoperative assessment. *Journal of Thoracic Disease*, 6 Suppl 1, S108-15. <https://doi.org/10.3978/j.issn.2072-1439.2013.12.29>
- Rabano, A., La Sala, M., Hernandez, P., & Barros, J. L. (1991). Thyroid carcinoma presenting as Pancoast's syndrome. *Thorax*, 46(4), 270–271. <https://doi.org/10.1136/thx.46.4.270>
 - Rusch, V. W., Parekh, K. R., Leon, L., Venkatraman, E., Bains, M. S., Downey, R. J., Boland, P., Bilsky, M., & Ginsberg, R. J. (2000). Factors determining outcome after surgical resection of T3 and T4 lung cancers of the superior sulcus. *The Journal of Thoracic and Cardiovascular Surgery*, 119(6), 1147–1153. <https://doi.org/10.1067/mtc.2000.106089>
 - Saidi, I., Aitbatahar, S., & Amro, L. (2021). Profil épidémiologique, clinique et évolutif des cancers bronchiques révélés par un syndrome de Pancoast–Tobias. *Revue Des Maladies Respiratoires Actualités*, 13(1), 127. <https://doi.org/10.1016/j.rmra.2020.11.262>
 - Samaraj, S., & Vijay Gowri Shankar, A. (2019). A case of Pancoast syndrome in TB. *Chest*, 156(4), A771. <https://doi.org/10.1016/j.chest.2019.08.742>
 - Sellami, L., Cherif, F., Kolsi, M., Khalbous, S., Essoussi, H., & Haddad, M. (2017). Le syndrome de Pancoast-Tobias : une entité à plusieurs visages, à propos de 95 cas. *Douleurs : Evaluation - Diagnostic - Traitement*, 18(3), 146–151. <https://doi.org/10.1016/j.douler.2017.04.001>
 - Toy, P., & Heck Jr, R. (2021). Soft-tissue tumors. In F. Azar & J. Beaty (Eds.), *Campbell's operative orthopaedics* (14th ed., pp. 1049–1078). Elsevier.
 - Weiss, S. W., & Enzinger, F. M. (1978). Malignant fibrous histiocytoma. An Analysis of 200 Cases. *Cancer*, 41(6), 2250–2266. [https://doi.org/10.1002/1097-0142\(197806\)41:6<2250::AID-CNCR2820410626>3.0.CO;2-W](https://doi.org/10.1002/1097-0142(197806)41:6<2250::AID-CNCR2820410626>3.0.CO;2-W)

Cite This Article: Joshua Tambe, Yannick Onana, Sylviane Dongmo, Vanessa Tongue, Boniface Moifo (2024). Pancoast-Tobias Syndrome Due to a High-Grade Fibrous Histiocytoma: A Case Report. *EAS J Radiol Imaging Technol*, 6(2), 29-33.
