

## Case Report

## Sialolithiasis of the Submandibular Gland- A Case Report

Nupur Agarwal<sup>1\*</sup>, Puneet Gupta<sup>2</sup>, Rajendragouda Patil<sup>3</sup>, Ambika Murari<sup>4</sup>, Arjit Vihan<sup>4</sup><sup>1</sup>Professor, Department of Oral Medicine and Radiology, Kothiwal Dental College and Research Centre, Moradabad<sup>2</sup>Professor, Department of Public Health Dentistry, Kothiwal Dental College and Research Centre, Moradabad<sup>3</sup>Professor and Head, Department of Oral Medicine and Radiology, Kothiwal Dental College and Research Centre, Moradabad<sup>4</sup>Post Graduate Student, Department of Oral Medicine and Radiology, Kothiwal Dental College and Research Centre, Moradabad

## Article History

Received: 28.05.2024

Accepted: 03.07.2024

Published: 23.07.2024

## Journal homepage:

<https://www.easpublisher.com>

## Quick Response Code



**Abstract:** Sialolithiasis refers to the presence of calcified structures within the ducts of salivary glands and is the most common disorder affecting these glands. Approximately 80-95% of sialoliths occur in the submandibular salivary gland. The occurrence rate of sialoliths is about 12 per 1000 individuals, with men being affected approximately twice as often as women. Sialoliths can be diagnosed through clinical examination, conventional radiography, computed tomography, and ultrasonography. Typical clinical indicators of sialoliths include painless swelling, sometimes extensive, often accompanied by difficulty opening the mouth (trismus) during eating, and symptoms that vary from mild discomfort to severe pain. This case report illustrates the clinical, radiological signs, and surgical treatment of a salivary stone in the submandibular gland.

**Keywords:** Sialolith, Salivary gland, Sialolithiasis, Submandibular.

**Copyright © 2024 The Author(s):** This is an open-access article distributed under the terms of the Creative Commons Attribution 4.0 International License (CC BY-NC 4.0) which permits unrestricted use, distribution, and reproduction in any medium for non-commercial use provided the original author and source are credited.

## INTRODUCTION

Sialoliths are calcified masses that develop either in the parenchyma or the ductal system of a salivary gland [1]. Sialolithiasis is the most frequently encountered disorder of the salivary glands, comprising approximately 1.2% of cases of unilateral major salivary gland swellings. The submandibular gland is most commonly affected, with sialolithiasis occurring in 80% of cases, followed by the parotid gland (19%) and the sublingual gland (1%) [2].

Typically, sialolithiasis manifests between the ages of 30 and 60 years, with a low incidence in children—only 3% of reported cases occur in pediatric patients. Males are affected twice as often as females [3, 4]. While the exact cause of sialolith formation remains uncertain, it is hypothesized that the formation is linked to saliva that is more alkaline, viscous, and rich in mucous [5]. Symptoms of sialolithiasis frequently involve discomfort and swelling in the parotid or submandibular region, particularly during meals [6]. Complete blockage of the duct results in severe symptoms. Additionally, symptoms may include decreased saliva flow from the salivary gland ducts, limited mouth opening, and discharge of pus [7].

In this paper we report a case of submandibular sialolith, its clinical manifestation and along with radiological investigations.

## CASE REPORT

A 50-year-old male reported with the chief complaint of swelling below the tongue towards the left side for 4 months. Initially, the swelling was smaller but gradually increased with time to attain the present size. The patient gave a history of enlargement of swelling while having food associated with pain. For that patient went to a local dental specialist where he was prescribed some antibiotics and analgesics. After taking those medicines pain was relieved but the swelling persisted. Soon after that, he started experiencing difficulty in chewing due to dryness in the mouth. Medical and family history was non-contributory. Personal history revealed that the patient had a habit of smoking cigarettes for 5 years. The patient used to take 5 cigarettes per day. On general examination, patient was moderately built and well-nourished and vitals were under normal limits. The patient was conscious, cooperative and well-oriented with time, place and things.

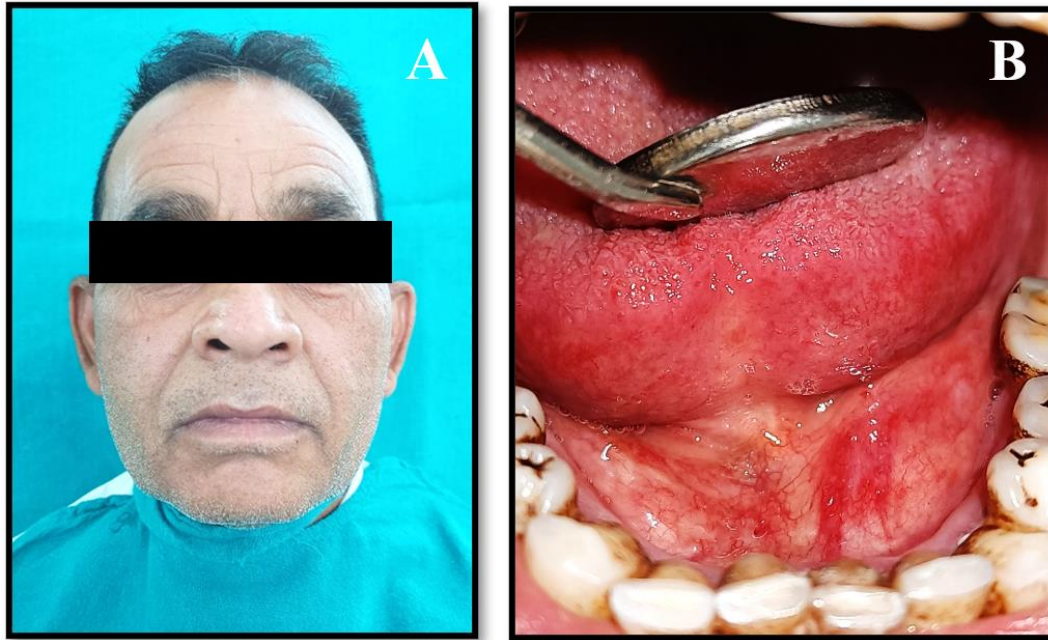No gross facial asymmetry was observed while examining extra orally (Fig. 1A). Intra orally a diffuse swelling was observed in the floor of the mouth towards

\*Corresponding Author: Dr. Nupur Agarwal

Professor, Department of Oral Medicine and Radiology, Kothiwal Dental College and Research Centre, Moradabad

the left side, roughly oval with a size of approximately 1.5 x 0.5 cm in dimensions (Fig. 1. B). Extending anteroposteriorly from the lingual frenum to the posterior part of the floor of the mouth, just adjacent to 36 lingual aspect. The overlying mucosa appears smooth and

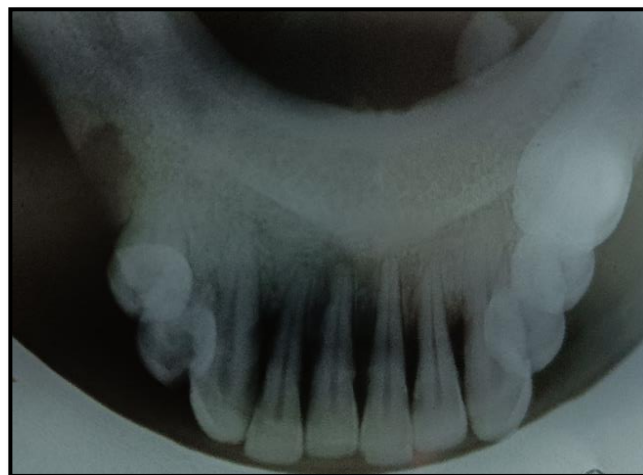slightly erythematous. Surrounding mucosa appears normal. On palpation, the swelling was slightly tender, hard in consistency, non-reducible, non-compressible, non-fluctuant and fixed to the underlying structures.



**Figure 1: A) Extra oral profile B). Intra oral with a diffuse swelling w.r.t left side**

There was no associated discharge or bleeding reported from the area. Based on clinical history and examination provisional diagnosis of sialolithiasis of the left Wharton's duct was made. Phleboliths, abscessed teeth, tonsillitis, calcified hemangiomas and benign

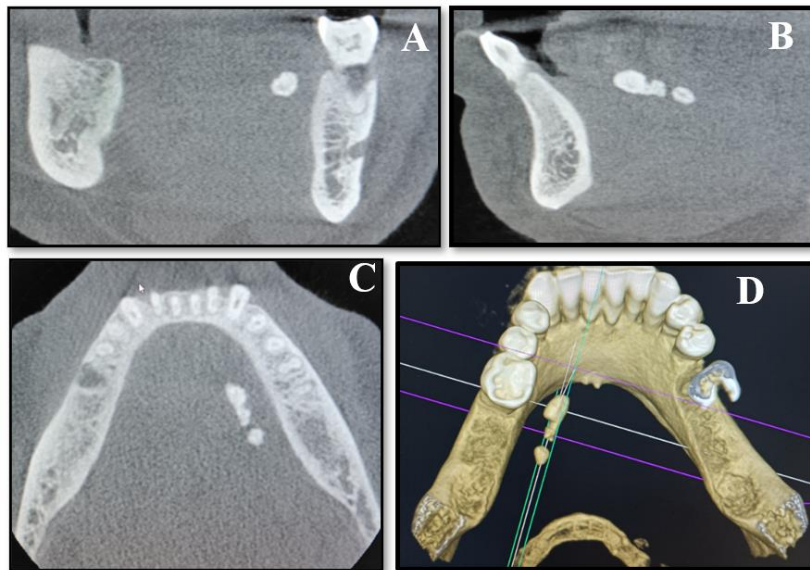
salivary gland tumours are among the differential diagnoses. An occlusal radiograph was advised which revealed an oval-shaped radiopacity adjacent to the lingual cortical plate of 35, 36 region (Figure 2).



**Figure 2: Occlusal Radiograph showing radiopacity**

Later, CBCT was also advised which revealed two radiopaque masses of size approx. 1.5 x 0.8 cm in dimensions and another 0.4 cm in diameter. Anterior one was roughly oval while the posterior one was spherical. Extending just adjacent from the lingual cortical plate of

35 till the distal half of 36 region (figure 3). This reconfirms our diagnosis of submandibular sialolithiasis on the left side. The calcified mass was surgically excised under local anaesthesia and sutures were placed (figure 4).



**Figure 3: CBCT images showing sialolith in different views A) Coronal view B) Saggittal view C) Axial View D) 3-D view**



**Figure 4: Surgically excised calcified**

## DISCUSSION

Sialolithiasis is defined as the presence of calcified structures within the ducts of salivary glands and is the most common disorder affecting these glands [8]. The exact cause of salivary stone formation remains elusive, and the rarity of the condition complicates comprehensive research efforts. Consequently, investigations into its etiological factors are significantly limited. The two main contributing factors to salivary stone formation are compositional, such as increased calcium content, and anatomical, including duct constriction that obstructs salivary flow or synthesis [9].

Sialolithiasis cases typically peak between the ages of 40 and 50. On average, individuals with parotid stones appear slightly older compared to those with submandibular stones. The parotid gland is involved in 72% to 95% of cases, whereas the submandibular gland is implicated in 4% to 28% of cases. Submandibular

stones are found within the duct in 80% to 90% of cases, with 34% to 57% occurring at the distal duct or hilum. Only 10% of submandibular stones are gland-specific. Intrinsic factors such as longer ducts and slower salivary flow against gravity due to the mylohyoid muscle's angulation are factors specific to the submandibular gland that contribute to stone formation [10].

Sialolithiasis can lead to uncomfortable swelling with pain (59%) or discomfort without pain (29%), or it may cause discomfort alone (12%). Patients often experience salivary colic and spasmodic pain during meals. Recurrent infections and abscesses can also occur. Additionally, salivary stones may be incidentally discovered during routine examinations or dental x-rays. Not all patients with stones experience symptoms, which depends on the degree of obstruction to salivary flow. Similar to individuals with salivary gland disorders, this patient presented with mild swelling

and pain in the right submandibular area exacerbated during meals [10].

Swelling and pain are the primary indicators of sialolithiasis, and accurate diagnosis relies on thorough patient history and clinical assessment. While X-ray imaging can aid in diagnosis, smaller or less mineralized calculi may require alternative radiographic methods such as sialography, ultrasound, CBCT scans, magnetic resonance imaging (MRI), scintigraphy, and sialoendoscopy [11].

Treatment options such as extracorporeal shock wave lithotripsy and sialoendoscopy are effective alternatives to traditional surgical removal for smaller sialoliths. For larger sialoliths, transoral sialolithotomy with sialodochoplasty or sialadenectomy remains the primary management approach [11].

Differential radiographic diagnoses for salivary calculi include a range of conditions such as air bubbles and film artifacts, retained roots, torus mandibularis, opaque foreign bodies, calcified lymph nodes, phleboliths, calcifications of the facial artery, cysticercosis, myositis ossificans, calcified sebaceous cyst, osteoma cutis, tuberculosis affecting the salivary glands, calcified acne, milk-alkali syndrome, and metastasis from various calcifying neoplasms [12].

After removal, healthcare providers should recommend that patients follow a diet high in proteins, liquids, and acidic foods to help prevent the recurrence of salivary gland sialoliths [11].

## CONCLUSION

In summary, the evaluation of sialoliths requires a thorough preoperative history, clinical examination, and precise imaging techniques. Localization of the salivary stone is crucial for both diagnosis and treatment planning. It is essential to differentiate sialoliths from other conditions involving soft tissue calcifications like calcified lymph nodes and vascular calcifications, as well as bone lesions such as mandibular torus and osteoma.

**Conflicts of Interest:** Nil

## REFERENCES

1. El Deel, M., Holte, N., & Gorlin, R. J. (1981). Submandibular salivary gland sialoliths perforated through the oral floor. *Oral Surgery, Oral Medicine, Oral Pathology*, 51(2), 134-139.
2. Batori, M., Mariotta, G., Chatelou, H., Casella, G., & Casella, M. C. (2005). Diagnostic and surgical management of submandibular gland sialolithiasis: report of a stone of unusual size. *Eur Rev Med Pharmacol Sci*, 9(1), 67-8.
3. Siddiqui, S. J. (2002). Sialolithiasis: An unusually large submandibular salivary stone. *Br Dent J*, 193, 89-91.
4. Nahlieli, O., Eliav, E., Hasson, O., Zagury, A., & Baruchin, A. M. (2000). Pediatric sialolithiasis. *Oral Surgery, Oral Medicine, Oral Pathology, Oral Radiology, and Endodontology*, 90(6), 709-712.
5. Hammett, J. T., & Walker, C. (2019). Sialolithiasis.
6. Duong, L. T., Kakiche, T., Ferré, F., Nawrocki, L., & Bouattour, A. (2019). Management of anterior submandibular sialolithiasis. *Journal of Oral Medicine and Oral Surgery*, 25(2), 16.
7. Omezli, M. M., Ayranci, F., Sadik, E., & Polat, M. E. (2016). Case report of giant sialolith (megalith) of the Wharton's duct. *Nigerian journal of clinical practice*, 19(3), 414-417.
8. Angiero, F., Benedicenti, S., Romanos, G. E., & Crippa, R. (2008). Sialolithiasis of the submandibular salivary gland treated with the 810- to 830-nm diode laser. *Photomedicine and Laser Surgery*, 26(6), 517-521.
9. Siddiqui, S. J. (2002). Sialolithiasis: an unusually large submandibular salivary stone. *Br Dent J*, 193, 89-91.
10. Ganesh, C., Sreenandhan, D., & Manoj, S. (2023). Sialolithiasis- A Case Report. *J Res Med Dent Sci*, 11(11), 14-16.
11. Arifa, S. P., Christopher, P. J., Kumar, S., Kengasubbiah, S., & Shenoy, V. (2019). Sialolithiasis of the submandibular gland: report of cases. *Cureus*, 11(3), e4180.
12. Divya, V. C., & Sathasivasubramanian, S. (2015). Submandibular sialolithiasis - a report of two cases. *J Med Res*, 1, 5-7.

---

**Cite This Article:** Nupur Agarwal, Puneet Gupta, Rajendragouda Patil, Ambika Murari, Arjit Vihan (2024). Sialolithiasis of the Submandibular Gland- A Case Report. *EAS J Dent Oral Med*, 6(4), 65-68.

---