

Case Report

Safety of Laparoscopy without Intraoperative Intracranial Pressure Monitoring In Patients with Ventriculoperitoneal Shunt: Case Report and Literature Review

Abbas AR Mohamed¹, Shafqat Ali Abbasi²

¹Consultant General and Laparoscopic Surgeon, Head of General Surgery Department, NGH Madinah –KSA

²Assistant Consultant General and Laparoscopic Surgeon, NGH –Madinah –KSA

*Corresponding Author

Abbas AR Mohamed

Abstract: Since the first ventriculoperitoneal (VP shunt), the procedure was firstly performed in 1908 it has become the standard neurosurgical procedure for CSF shunting (1). With the advent of VP shunting and improvement in medical therapies, patients with hydrocephalus are living longer and may present with surgical problems that required laparoscopy. We present a case of laparoscopic cholecystectomy for acute cholecystitis in a patient with VP shunt.

Keywords: Laparoscopic cholecystectomy, Ventriculoperitoneal shunt.

INTRODUCTION

Although there are no absolute contraindications for laparoscopy in patients with VP shunts, still there is controversy regarding the safety of performing laparoscopic surgery in patients with VP shunt and the needs for intraoperative monitoring of intracranial pressure. We report a case of laparoscopic cholecystectomy done with routine anesthetic monitoring without intraoperative monitoring of intracranial pressure on a 27 years old female, without having postoperative neurological complications or catheter failure.

CASE REPORT

27 years old female was admitted to the surgical ward complaining of recurrent attacks of pain in the right hypochondrium associated with chronic dyspepsia and fat intolerance. She had an attack of acute pancreatitis and ERCP for obstructive jaundice a year before her admission without having cholecystectomy. She was known epileptic since childhood on antiepileptic medications and diagnosed to have Bechet disease and mild hydrocephalus at age of 16 and had VP shunt at the age of 21years old.

On admission, she had a mild fever with a temperature of 37.9 C, pulse and blood pressure within normal values. Abdominal examination revealed

tenderness and rigidity over right hypochondrium with positive Murphy's sign. Her all blood investigations including complete blood count, urea and electrolytes, liver function test and coagulation profile were within normal values apart from leukocytosis (WBC $13.600 \times 10^6/L$). Her abdominal ultrasound showed distended gall bladder with multiple gallstones together with thickened edematous gallbladder walls (fig.-1). The common bile duct and intrahepatic biliary radicles were reported to be slightly dilated without evidence of stones in the common bile duct. Her pre-operative chest x-ray showed the shunt tube in position (fig.-2)

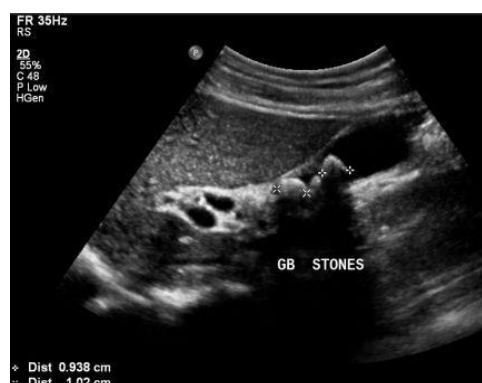

Fig.1: Showing distended gall bladder with multiple gallstones together with thickened edematous gallbladder walls.

Quick Response Code



Journal homepage:

<http://www.easpublisher.com/easjacc/>

Article History

Received: 10.01.2019

Accepted: 25.01.2019

Published: 15.02.2019

Copyright © 2019 The Author(s): This is an open-access article distributed under the terms of the Creative Commons Attribution 4.0 International License (CC BY-NC 4.0) which permits unrestricted use, distribution, and reproduction in any medium for non-commercial use provided the original author and source are credited.

DOI: 10.36349/easjacc.2019.v01i01.001

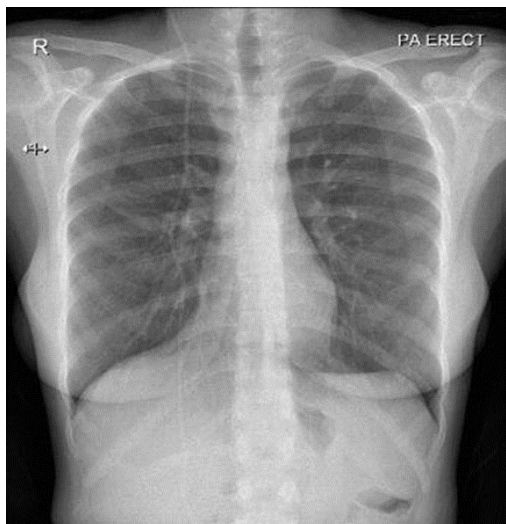


Fig.-2: Showing the shunt tube crossing the chest to the abdomen.

She had uneventful laparoscopic cholecystectomy without monitoring of the intracranial pressure, however, the torchers were inserted carefully avoiding the path of the VP shunt tube and the insufflation pressure was reduced to 10 mm of Hg. The shunt tube was examined before leaving the abdomen and was found to be functioning well. Post-operatively, she didn't develop any neurological symptoms and signs and she was discharged on the next day.

DISCUSSIONS

The standard of treatment hydrocephalus is the surgical insertion of a shunt to divert CSF from the brain to another area of the body. Since the first VP shunt procedure was performed in 1908 it has become the standard neurosurgical procedure for CSF shunting (Pudenz, R.H. 1981). With the advent of VP shunting and improved medical therapies, patients with hydrocephalus are living longer and presenting with unrelated medical problems (Hammill, C. W. *et al.*, 2010). It was estimated that the number of patients with CSF shunts in the United States to be greater than 125,000.4 in 1995 (Bondurant, C. P., & Jimenez, D. F.1995). Surgeons are increasingly facing situations where they have to operate laparoscopically on patients with VP shunts.

Although there is no absolute contraindication for laparoscopy in VP shunts, there have been always risks of raised intracranial during laparoscopic procedures resulting from insufflation of carbon dioxide to create space for instrument placement and to allow safe tissue dissection (Sankpal, R. *et al.*, 2011).

Many studies have documented an increase in intracranial pressure with abdominal insufflation, but the exact mechanism has not been explained (Halverson, A. *et al.*,1998). It was suggested that the increase in intracranial pressure with the creation of pneumoperitoneum may result from a "Valsalva-like"

phenomenon, together with the fact that pneumoperitoneum may increase the resistance to outflow through the distal peritoneal catheter, causing a partial or complete shunt obstruction (Uzzo, R. G. *et al.*, 1997). Theoretically, high intra-abdominal pressure may directly obstruct the antegrade cerebrospinal fluid flow and the retrograde passage of carbon dioxide gas may result in a sudden increase in intracranial pressure. The combined effect of hypercapnia-induced cerebral arterial dilatation and venous pressure elevation generated by abdominal pressure may cause increased intracranial blood volume and increased intra-pressure in the fixed volume of the cranium (Cobianchi, Lorenzo *et al.*, 2012).

Rosenthal et al studied the effect of pneumoperitoneum on the intracranial pressure in a large animal model they concluded that there was a significant and linear increase in intracranial pressure with increased intra-abdominal pressure and Trendelenburg position. The combination of increased intra-abdominal pressure of 16 mmHg and Trendelenburg position increased ICP 150% over control levels (Rosenthal, R. J. *et al.*, 1997). Similarly, Josephs et al (Josephs, L. G. *et al.*, 1994) investigated the effect of pneumoperitoneum on intracranial pressure and cerebral perfusion pressure in animals' model they concluded that pneumoperitoneum during laparoscopy may increase intracranial pressure and advised that laparoscopy for evaluation of abdominal trauma victims must be used cautiously in patients with severe head injuries.

A standard parameter of any shunt valve's hydrodynamic profile, as derived by the manufacturer, is a quantification of "retrograde flow." This variable is defined as the distal pressure head that a shunt valve can tolerate before allowing retrograde flow to occur (Drake, J.M., & Sainte-Rose, C. 1995). It indicates the upper limit of insufflation pressure that can be safely produced without having retrograde flow. Most of the shunt has a one-way valve which can withstand pressures of 300 mmHg and prevent reflux of intraabdominal fluid (Collure, D. W. D. *et al.*, 1995) but unfortunately, the relation between intraperitoneal pressure and shunts failure was not intensively investigated. (Neale, M. L., & Falk, G. L. 1999). studied on (in vitro) model the potential failure of shunt valves with increased intra-abdominal pressure of laparoscopy with nine different shunts subjected to increased back pressure and none of the valves showed any signs of a leak associated with the increased back pressure. The risk of retrograde failure of the valve system has been shown to be minimal even with intra-abdominal pressures as high as 80 mm Hg (Al-Mufarrej, F. *et al.*, 2005).

Multiple methods have been described to reduce the risk of retrograde shunt failure, including clamping or clipping of the intraperitoneal end of the

catheter, exposure and clamping of the subcutaneous portion of the catheter, and externalization of the intraperitoneal portion of the shunt for the duration of the case (Al-Mufarrej, F. *et al.*, 2005; Kimura, T. *et al.*, 2002).

There is still controversy regarding the safety of performing laparoscopic surgery in patients with VP shunt and potentially decreased cerebral compliance (Sankpal, R. *et al.*, 2011). There is little-published evidence regarding intraoperative and postoperative complications in patients with ventriculoperitoneal shunts who undergo laparoscopic surgery, partly due to the small number of reported cases and mainly due to lack of large-scale studies including a large number of patients as most cases present sporadically. We believe each case should be reported to build up a base data for further studies.

Many authors (Sankpal, R. *et al.*, 2011; Jackman, S. V. *et al.*, 2000) indicated that there is no evidence of clinically significant increased intracranial pressure in most patients with VP shunts who undergo laparoscopy and advised routine anesthetic monitoring during their surgery without needs for invasive methods for shunt monitoring which are not without risk however, some authors advised neurosurgery consultation prior to surgery to verify the proper function of the VP shunt, identification of the path of the catheter within the abdominal wall to avoid inadvertent damage to the catheter during trocar placement, and making sure that the intraperitoneal part of the catheter is not twisted or obstructed prior to decompression of the abdomen (Hammill, C. W. *et al.*, 2010).

(Fraser, J. D. *et al.*, 2009) found no episodes of air embolism one shunt infection in a study conducted over 51 laparoscopy procedures in patients with VP shunts.

(Jackman, S.V. *et al.*, 2000) reviewed the anesthesia records of 12 females and 6 males who had a ventriculoperitoneal shunt and underwent a total of 19 consecutive laparoscopic operations. They found that there was no evidence of clinically significant increased intracranial pressure in all of them. The authors concluded that invasive methods for shunt monitoring are usually not required and routine anesthetic monitoring should remain the standard of care in the absence of clear evidence to the contrary.

Collure *et al.*, published data in 1995 on a series of four patients with VP shunts who had laparoscopic cholecystectomy without intraoperative monitoring of intracranial pressure without having central nervous system sequelae postoperatively and the shunts remained intact and functioning. The authors concluded that elective laparoscopic cholecystectomy in patients with VP shunts can be done safely without a

need for clamping manipulation of the shunt (Collure, D. W. D. *et al.*, 1995).

On the other hand, (Baskin, J.J. *et al.*, 1998) reported in 1998 the first documented case of laparoscopically induced Ventriculoperitoneal (VP) shunt failure due to shunt obstruction that required emergency revision in a patient with shunt-dependent hydrocephalus who underwent laparoscopic placement of a feeding jejunostomy. The authors concluded that laparoscopic surgery may represent a potential danger in patients with pre-existing CSF shunts, as the increased intraabdominal pressure resulting from the pneumoperitoneum may impair CSF drainage due to a sustained elevated distal pressure gradient or distal catheter obstruction together with the potential risk of retrograde insufflation of the CSF spaces through an incompetent shunt valve mechanism.

(Baskin, J. *et al.*, 1998; Schwed, D. A. *et al.*, 1992) reported a case of severe subcutaneous emphysema during peritoneal insufflation along a VP track created ten days earlier. The shunt system remained functional. They concluded that "recently" placed "peritoneal subcutaneous" catheters should be viewed as a relative contraindication to laparoscopy.

A clinical experience published by Uzzo *et al.*, in 1997 described the potential adverse effects of the laparoscopic surgery, monitoring the intracranial pressure in two children with an Arnold-Chiari malformation (Uzzo, R. G. *et al.*, 1997; Cobianchi, Lorenzo *et al.*, 2012).

CONCLUSION

The little-published evidence regarding intraoperative and postoperative complications in patients with VP shunts who undergo laparoscopic surgery is partly due to the small number of reported cases and mainly due to lack of large-scale studies including a large number of patients as most cases present sporadically. Some studies indicate the safety of laparoscopy in patients with VP shunt even without intraoperative intracranial pressure monitoring but they are not sufficient to establish a solid consensus. we recommend all cases to be reported to build up base data for futures studies.

REFERENCES: -

1. Pudenz RH. The survival treatment of hydrocephalus- a historical review. *Surg Neurol.* 1981; 15:15–26.
2. Hammill, C. W., Au, T., & Wong, L. L. (2010). Laparoscopic cholecystectomy in a patient with a ventriculoperitoneal shunt. *Hawaii medical journal*, 69(4), 103.
3. Bondurant, C. P., & Jimenez, D. F. (1995). Epidemiology of cerebrospinal fluid shunting. *Pediatric neurosurgery*, 23(5), 254-259.

4. Sankpal, R., Chandavarkar, A., & Chandavarkar, M. (2011). Safety of laparoscopy in ventriculoperitoneal shunt patients. *Journal of gynecological endoscopy and surgery*, 2(2), 91.
5. Halverson, A., Buchanan, R., Jacobs, L., Shayani, V., Hunt, T., Riedel, C., & Sackier, J. (1998). Evaluation of mechanism of increased intracranial pressure with insufflation. *Surgical endoscopy*, 12(3), 266-269.
6. Uzzo, R. G., Bilsky, M., Mininberg, D. T., & Poppas, D. P. (1997). Laparoscopic surgery in children with ventriculoperitoneal shunts: effect of pneumoperitoneum on intracranial pressure—preliminary experience. *Urology*, 49(5), 753-757.
7. Cobianchi, L., Dominioni, T., Filisetti, C., Zonta, S., Maestri, M., Dionigi, P., & Alessiani, M. (2012). Ventriculoperitoneal shunt and the need to remove a gallbladder: Time to definitely overcome the feeling that laparoscopic surgery is contraindicated. *Annals of Medicine and Surgery*, 3(3), 65-67.
8. Rosenthal, R. J., Hiatt, J. R., Phillips, E. H., Hewitt, W., Demetriou, A. A., & Grode, M. (1997). Intracranial pressure. *Surgical Endoscop*, 11(4), 376-380.
9. Josephs, L. G., Este-McDonald, J. R., Birkett, D. H., & Hirsch, E. F. (1994). Diagnostic laparoscopy increases intracranial pressure. *The Journal of trauma*, 36(6), 815-8.
10. Drake JM, Sainte-Rose C. The Shunt Book. Cambridge, MA: Blackwell Science; 1995
11. Collure, D. W. D., Bumpers, H. L., Luchette, F. A., Weaver, W. L., & Hoover, E. L. (1995). Laparoscopic cholecystectomy in patients with ventriculoperitoneal (VP) shunts. *Surgical endoscopy*, 9(4), 409-410.
12. Neale, M. L., & Falk, G. L. (1999). In vitro assessment of back pressure on ventriculoperitoneal shunt valves. *Surgical endoscopy*, 13(5), 512-515.
13. Al-Mufarrej, F., Nolan, C., Sookhai, S., & Broe, P. (2005). Laparoscopic procedures in adults with ventriculoperitoneal shunts. *Surgical Laparoscopy Endoscopy & Percutaneous Techniques*, 15(1), 28-29.
14. Baskin, J. J., Vishteh, A. G., Wesche, D. E., ReKate, H. L., & Carrion, C. A. (1998). Ventriculoperitoneal shunt failure as a complication of laparoscopic surgery. *JSLS: Journal of the Society of Laparoendoscopic Surgeons*, 2(2), 177.
15. Kimura, T., Nakajima, K., Wasa, M., Yagi, M., Kawahara, H., Soh, H., ... & Okada, A. (2002). Successful laparoscopic fundoplication in children with ventriculoperitoneal shunts. *Surgical Endoscopy And Other Interventional Techniques*, 16(1), 215-215.
16. Sankpal, R., Chandavarkar, A., & Chandavarkar, M. (2011). Safety of laparoscopy in ventriculoperitoneal shunt patients. *Journal of gynecological endoscopy and surgery*, 2(2), 91.
17. Fraser, J. D., Aguayo, P., Sharp, S. W., Holcomb III, G. W., Ostlie, D. J., & St. Peter, S. D. (2009). The safety of laparoscopy in pediatric patients with ventriculoperitoneal shunts. *Journal of Laparoendoscopic & Advanced Surgical Techniques*, 19(5), 675-678.
18. Jackman, S. V., Weingart, J. D., Kinsman, S. L., & Docimo, S. G. (2000). Laparoscopic surgery in patients with ventriculoperitoneal shunts: safety and monitoring. *The Journal of urology*, 164(4), 1352-1354.
19. Schwed, D. A., Edoga, J. K., & McDonnell, T. E. (1992). Ventilatory impairment during laparoscopic cholecystectomy in a patient with a ventriculoperitoneal shunt. *Journal of laparoendoscopic surgery*, 2(1), 57-59.